ics & gynecology books, visit our website **www.jaypeebrothers.com,** for detailed information on obstetrics & gynecology books

Case Discussions



Case Discussions in Obstetrics & Gynecology

YM Mala • Madhavi M Gupta • Asmita M Rathore

Highlights

- New topics and case scenarios
- Updated management guidelines

An Official Publication of the Department of Obstetrics & Gynecology, MAMC, New Delhi, India

SECOND EDITION

JAYPEE

Case Discussions in

OBSTETRICS AND GYNECOLOGY

Second Edition

Editors

YM Mala
MD DNB
Director-Professor
Department of Obstetrics and Gynecology
Maulana Azad Medical College and
Lok Nayak Hospital, New Delhi, India

Madhavi M Gupta
MS
Professor
Department of Obstetrics and Gynecology
Maulana Azad Medical College and
Lok Nayak Hospital, New Delhi, India

Asmita M Rathore
MS FRCOG
Director-Professor and Head
Department of Obstetrics and Gynecology
Maulana Azad Medical College and
Lok Nayak Hospital, New Delhi, India

Foreword

Sanjay Tyagi

JAYPEE BROTHERS

JAYPEE BROTHERS MEDICAL PUBLISHERS
The Health Sciences Publisher
New Delhi | London

Contents

PART 1

OBSTETRICS

Section 1: Early Pregnancy

1. **Nausea and Vomiting in Pregnancy 3**
   Madhavi M Gupta, Shristi Shrivastava

2. **Recurrent Pregnancy Loss 13**
   Madhavi M Gupta

Section 2: Obstetric Complications

3. **Hypertension in Pregnancy 25**
   Anjali Tempe, Priyanka Khandey

4. **Antepartum Hemorrhage 46**
   Mumtaz Khan, Chanchal Singh

5. **Multiple Gestation 74**
   Devender Kumar, Asmita Patil

6. **Obstetric Cholestasis 95**
   Poonam Kashyap

7. **Pregnancy with Intrauterine Death of Fetus 105**
   Krishna Agarwal, Astha Raheja

8. **Pregnancy with Previous Cesarean Section 115**
   Renu Tanwar

JAYPEE BROTHERS

9. Preterm Labor 127
Poonam Sachdeva, Ishita Agarwal, Chanchal Gupta

10. Preterm Premature Rupture of Membranes 140
Sharda B Ghosh, Reetu Yadav, Madhavi M Gupta

11. Pregnancy beyond due Date 148
Manju Puri, Akriti Gautam

Section 3: Medical Complications

12. Anemia in Pregnancy 157
Usha Manaktala, Avantika Gupta

13. Heart Disease in Pregnancy 175
Leena Wadhwa, Arima Nigam, Monica Marghret K

14. Diabetes in Pregnancy 194
Ashok Kumar, Divya KV, Chandni

15. HIV-positive Pregnancy 207
Shikha Sharma

16. Liver Disease in Pregnancy 237
Niharika Dhiman, Shweta Mishra

17. Renal and Urinary Tract Disorders in Pregnancy 253
Pushpa Mishra, Aparna Setia, Sonia Goswami

18. Thrombocytopenia in Pregnancy 268
Shristi Shrivastava, Sadhana Singh, Preeti Singh

Section 4: Fetal Disorders

19. Pregnancy with Previous Congenital Disorders 278
Sangeeta Gupta, Vaishnavi Seshan

JAYPEE BROTHERS

20. Fetal Growth Restriction 300
Chandan Dubey

21. Rh Alloimmunization 319
Sangeeta Bhasin, Shristi Shrivastava

Section 5: Labor and Puerperium

22. Respectful Maternity Care 345
Shalini Singh, Paridhi Jha, Richa Goel

23. Septic Abortion: A Clinical Review 355
Rachna Sharma, Kaarthiga Gopinath

PART 2
GYNECOLOGY

Section 6: Benign Gynecological Disorders

24. Abnormal Uterine Bleeding 371
Saritha Shamsunder, B Manjeera Siva Jyothi

25. Fibroid Uterus 396
YM Mala, Pooja Pundhir, Karishma Bhatia, Sharda B Ghosh

26. Approach to a Case of Adnexal Mass in a Young Patient 415
Vijay Zutshi, Reenu Kanwar, Binni Makkar

27. Prolapse Uterus 429
Reena Rani, Asmita M Rathore

28. Vulvar Skin Disorders (Benign Conditions) 447
Shakun Tyagi, Shweta Mishra

JAYPEE BROTHERS

Section 7: Malignant Gynecological Disorders

29. Postmenopausal Bleeding 465
Swaraj Batra, Puneet K Kochhar, Tanvi Raj

30. Management of Abnormal Pap Smear 486
Raksha Arora, Bhoomika Tantuway

31. Approach to a Case of Carcinoma Cervix 497
Neerja Bhatla, Seema Singhal

32. Lump in Abdomen 508
Reva Tripathi, Nikita Banerjee, Nilanchali Singh

33. Gestational Trophoblastic Disease 524
Shalini Rajaram, Megha Jindal, Bindiya Gupta

34. Carcinoma Vulva 540
Gauri Gandhi, Divya Singh, Saloni Chadha

Section 8: Urogynecology

35. Urinary Incontinence 551
Nilanchali Singh, Sneha Mishra

36. Vesicovaginal Fistula 563
Latika Sahu

Section 9: Reproductive Medicine

37. Amenorrhea 594
Deepti Goswami

38. Secondary Amenorrhea 608
Kamna Datta

JAYPEE BROTHERS

39. Primary Infertility 616
Sudha Prasad, Saumya Prasad, Astha Singh

40. Secondary Infertility 637
Sneha Mishra, Astha Singh, Bidhisha Singha

41. Menopausal Hormone Therapy 646
Shelly Arora, Arushika Yedla

Index 661

JAYPEE BROTHERS

CHAPTER 27

Prolapse Uterus

Reena Rani, Asmita M Rathore

JAYPEE BROTHERS

INTRODUCTION

Pelvic organ prolapse (POP) is the descent of one or more aspects of the vagina and uterus (cervix), or vaginal vault after hysterectomy.[1] It affects approximately one in nine women and the lifetime risk of undergoing surgery for prolapse or urinary incontinence is 11%.[2] Though, generally not life-threatening, they significantly impair physical functioning, emotional well-being, and the quality of life.

This chapter will discuss the clinical evaluation and management of four cases of POP. The definitive treatment of prolapse is nearly always some sort of surgery but should be performed only if the condition is causing symptoms. If the prolapse is incidental or it is not certain that the patients symptoms are attributable to it, the operation is best deferred.[3]

CASE 1

A 42-year-old Mrs X, Para 3 presents to gynecology outpatient department with complaint of mass descending per vaginum for 2 years and difficulty in initiating micturition.

Q1. What details will you ask in history?

Ans: *The following detailed history to be taken:*

- History of (H/o) presenting complaints—duration of prolapse, rate of increase in severity, any bladder and bowel complaints. Irreducibility of prolapse indicates longstanding nature of the problem and is due to congestion, edema, and hypertrophy of the tissues.
- History of precipitating factor—like chronic cough, constipation, any abdominal swelling, etc. They should be treated before surgical treatment so as to reduce risk of recurrence.
- Obstetric history—the commonest aggravating factor is birth injury. History of factors like pregnancies at short intervals, prolonged labor, big babies, and lack of perineal exercises should be elicited. Parity of the patient, desire to preserve fertility should be noted to choose appropriate treatment option.

- Menstrual history—estrogen deficiency in postmenopausal state results in weakening of connective tissue and aggravation of prolapse. Any associated menstrual abnormality may need further evaluation and may modify choice of treatment.
- Other symptoms—the presence of white discharge, intermenstrual or postcoital bleeding may be due to decubitus ulcer but should be appropriately evaluated. It is vital to assess the urinary tract, defecatory or sexual dysfunction and psychological distress because of prolapse.
- Treatment History—any treatment in form of pessary or surgery and its results should be noted.
- Family history—similar condition in mother or sisters.

Q2. What are the common urinary symptoms in prolapse and their mechanism?

Ans: The woman with prolapse may present with variety of urinary symptoms.

- Difficulty in initiating micturition is common problem in women with large cystocele. It is difficult to empty the bladder and the difficulty increases with straining as bladder base and trigone descend below the level of urethra. She can empty the bladder only after reducing the mass digitally.
- Frequency and dysuria—incomplete emptying of bladder leads to increased risk of cystitis.
- Stress urinary incontinence (SUI) may be present if prolapse is associated with descent of urethrovesical junction.
- Rarely retention of urine can also be seen.

Q3.What are the common bowel and sexual history need to be taken in a case of prolapse?

Ans:

- Assessment of bowel function like H/o straining with bowel movements, laxative use, fecal incontinence, and incomplete rectal emptying needs to be done. Posterior compartment defect, e.g. rectocele generally require splinting action for complete emptying of stools.
- Each patient should be assessed for symptoms of dyspareunia, coital incontinence of urine or stool, and sexual dysfunction that is related to the prolapse.

Q4. What important points will you note in examination of this woman?

Ans:

- The general examination—should note general condition of patient and assess mental status, body mass index, and nutritional status. Since many women may need surgical intervention, presence of anemia, any lymphadenopathy should be looked for.
- Respiratory system—any wheeze or crepts to rule out asthma and chronic obstructive pulmonary disease (COPD)
- The abdominal examination—should focus on hernial sites, any mass or free fluid.
- The pelvic examination is most important to assess severity of prolapse and plan surgical procedure. Local examination should be performed in dorsal lithotomy position.
  - Inspection of external genitalia and perineum should done for any evidence of old healed perineal tears and integrity of perineal body.
  - Eliciting—any leakage of urine on coughing should be noted with full bladder. If present, then Bonneys test should be performed by elevating bladder neck with index

JAYPEE BROTHERS

and middle fingers on either side which should stop leakage of urine on stress. To detect any occult SUI elicit the leakage of urine after repositing the prolapse (as the urethra get kinked along with prolapse)
  - Examination of prolapse—the degree of prolapse should be assessed after maximum straining.
- Look for evidence of hypertrophy of cervix, congestion, edema, decubitus ulcer, keratinization, infection, or vaginal atrophy.
- Note the degree of descent of cervix, anterior and posterior vaginal wall, and quantify the degree of prolapse.
- Identify the specific anatomic defects—that can be addressed with surgical intervention. The dominant prolapse is considered to be first hernia to descend or the most dependent part of prolapse and provides key clue about where most significant fascial damage is located.[4]
  - Bimanual pelvic examination is done to note direction of uterus, size and mobility of uterus and any adnexal mass and tenderness. The levator tone should be assessed.

Q5. How do you look for tone of levatorani muscle?

Ans: The levator tone is assessed by palpating vaginal wall at 5 and 7 o'clock position about 2–4 cm above hymen. The woman is asked to squeeze her vaginal muscles as though she is holding gas or stopping urine flow. The strength is graded from 0 to 5 using modified oxford scale[5] as follows:

- Grade 0—no discernible pelvic floor contraction
- Grade 1—a flicker under finger
- Grade 2—a weak contraction or increase in tension without any discernible lift or squeeze
- Grade 3—a moderate contraction with partial lifting of postvaginal wall and squeezing of finger, contraction more than grade 3 is visible.
- Grade 4—good pelvic contraction causing elevation of postvaginal wall against resistance and indrawing of perineum.
- Grade 5—strong contraction of pelvic floor against strong resistance.

Levator muscles should also be palpated for tenderness or spasm. The integrity of the pudendal nerve is tested by eliciting anal and bulbocavernosus reflexes. The anal reflex is elicited by gently stroking perianal skin which results in contraction of external anal sphincter and in bulbocavernosus reflex, the bulbocavernosus and ischiocavernosus muscles contract in response to tapping the clitoris.

Q6. What are the different classifications of prolapse and their advantages?

Ans: Though there are many classifications, the one traditionally used is Shaw's classification and now widely recommended worldwide is the pelvic organ prolapse quantification system (POPQ)[6] which objectively quantifies the prolapse.

Shaw's classification: This is the simplest and most widely used in the past. It classifies prolapse in four stages and uses ischial spine as reference point.

- First degree—descent of uterus below ischial spine but cervix remains within the introitus
- Second degree—descent of cervix up to introitus

JAYPEE BROTHERS

- Third degree—descent of cervix outside introitus
- Fourth degree—entire uterus prolapses outside the vulva.

POPQ[6] system: It is approved by International Continence Society in 1995. It allows accurate quantification for scientific comparisons and is thus more objective and reproducible. In this system the positions of nine sites are measured in cm in relation to hymen (negative number for proximal and positive number for distal) and recorded in grid form **(Fig. 1)**. These nine sites are as follows:

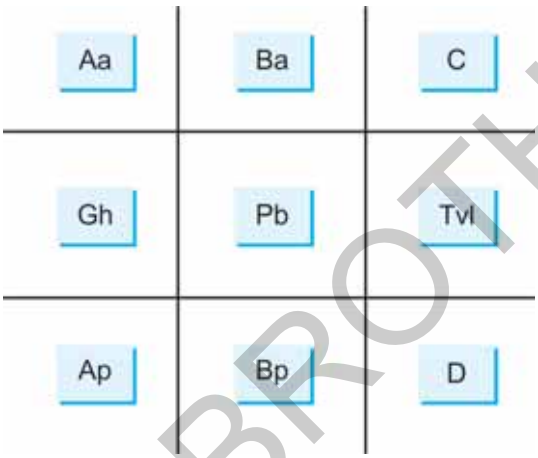

Fig. 1: Pelvic organ prolapse quantification system (POPQ) staging.

1. Aa—point 3 cm proximal to urethral meatus on anterior vaginal wall
2. Ba—the most distal portion of upper anterior vaginal wall
3. C—cervix or vaginal cuff
4. D—posterior vaginal fornix
5. Ap—point 3 cm proximal to hymen on postvaginal wall
6. Bp—most distal position on posterior vaginal wall
7. Gh—the diameter of genital hiatus (measured from middle of external urinary meatus to posterior midline of hymen)
8. Pb—the width of perineal body (measured from posterior midline of hymen to the midanal opening)
9. Tvl—total vaginal length (greatest depth of vagina in cm after reducing the prolapse).

It should also be recorded if the measurements were taken in lithotomy or standing position and whether straining or traction was applied.

Based on measurements at above 9 sites the prolapse is staged from 0 to 4 according to most distal position of prolapse:

- Stage 0—no prolapse is demonstrated.
- Stage I—the criteria for stage 0 are not met but the prolapse is >1 cm above the hymen.
- Stage II—within 1 cm of hymen (i.e. the quantification value is > –1 but < +1)
- Stage III—more than stage II but 2 cm less than total vaginal length [i.e. quantification value > +1 but < + (TVL-2)].
- Stage IV—complete eversion of genital tract [i.e. quantification value ≥ + (TVL-2)].

JAYPEE BROTHERS

Q7. How will you perform POPQ staging and what is the stage of prolapse in your patient?

Ans: Women is placed in lithotomy position. Ayres spatula is used for measurements and grid with three columns and rows is drawn and labeled with patient's name.

- First measurement of genital hiatus and perineal body is completed and entered in grid.
- Then speculum is inserted and Tvl is measured with spatula (after complete repositioning without any maneuver).
- Points C and D are next measured during maximal Valsalva's maneuver.
- Lastly points Aa, Ba, Ap, and Bp are measured.

The severity of prolapse in my patient is stage 4 with leading point C, (lithotomy position with straining) with decubitus ulcer.

The quantification in my patient is as follows **(Fig. 2)**:

Mrs X Age 42 years Hospital record no. 000000

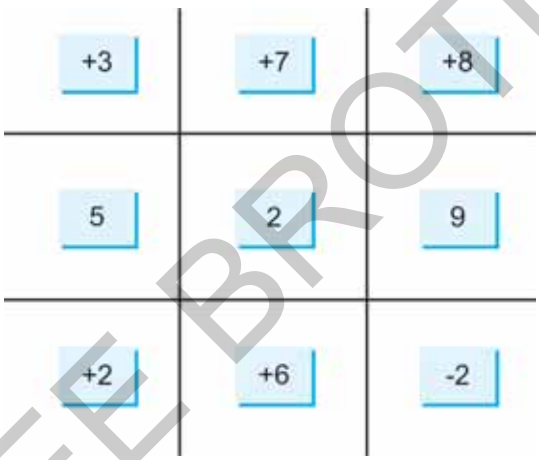

Fig. 2: Pelvic organ prolapse quantification system (POPQ) staging of Mrs X.

Q8. What is differential diagnosis of prolapse uterus?

Ans: *The common differential diagnosis of prolapse uterus are:*

- Gartner cyst or anterior vaginal wall cyst may look similar to cystocele but is not reducible.
- Congenital elongation of cervix—though congenital, its elongation may present for the first time after childbirth. It is identified by deep fornices and long infravaginal portion of cervix.
- Fibroid polyp coming out of vagina can be diagnosed by rim of cervix felt all around the tumor and associated menstrual complaints.
- Chronic inversion.

Q9. How will you investigate your patient?

Ans: *The woman should have:*

- Baseline assessment of her general condition by having complete hemogram and routine urine analysis.
- Urine culture and sensitivity—it is mandatory to rule out urinary tract infection (UTI).

JAYPEE BROTHERS

- Complete preoperative assessment for anesthesia—should be done in women planned for surgical treatment which will include blood sugar estimation, renal function tests, ECG and chest X-ray (also rule out COPD) or any other investigation as advised by anesthesiologists.
- Special investigations—in woman with urinary, defecatory or sexual dysfunction further evaluation by appropriate consultation. Urodynamic testing may help inform patient counseling and may be considered if there is bothersome incontinence with stage II or greater prolapse. Postvoid residual urine can be calculated by catheterization or ultrasonography in patients with voiding difficulty.

Q10. What is decubitus ulcer and how will you manage it?

Ans: The decubitus ulcer is present on dependant part. It is usually an ischemic process due to venous stasis resulting in tissue anoxia. The decubitus ulcer is treated by keeping the prolapse reduced, which will restore circulation and help in healing. Prolapse can be kept in reduced position by packing. Packing with glycerin-acriflavin may help if tissues are hypertrophied and edematous.

In an atrophic vagina, application of estrogen cream CEE 0.625 mg/day for 2–3 weeks will help in tissue vascularization and improve healing power of tissues, but should be stopped at least 2 weeks prior to surgery.

If hospitalization is not possible for regular packing, option of insertion of pessary for short duration can be considered.

If decubitus ulcer does not heal or show improvement in reasonable time, biopsy from margin should be taken to rule out malignancy.

Q11. What is DeLancey's classification of supports of uterus?

Ans: *DeLancey[7] has classified supports of uterus in three levels:*

Level I—apical support by uterosacral ligaments, Mackenrodt's ligament and paracolpium

Level II—midvaginal support due to lateral attachment to levator fascia

Level III—lower vaginal supports by perineal body or fusion of distal urethra to pubic bone.

Q12. How will you treat your patient?

Ans: My patient is 42 years of age, completed her family and symptomatic with prolapse interfering with her normal life and opted for *vaginal hysterectomy and with site-specific repair of anterior and posterior vaginal wall defects* after counseling.

Q13. Is hysterectomy necessary for treatment of prolapse? What is role of uterus preserving surgeries for prolapse?

Ans: No, but generally forms a part of prolapse surgery in older women who have completed family, as removal of uterus permits better reconstruction of supports and proper proximal suspension of vaginal vault as cervix limits access to structures of paracolpium and thus reduce risk of recurrence. Uterine preservation in cases of uterovaginal prolapse was previously only considered if future fertility was a particular concern but is increasing in popularity due its advantages of fertility preservation, stronger apical support, reduced vaginal surgery, and dysfunction and psychological wellbeing.[8] It is important to counsel women about the lack of robust evidence to support its benefits, impact of surgery on pregnancy outcomes, and pregnancy on surgery.

JAYPEE BROTHERS

Q14. What is site-specific repair? What are the common sites of specific defects?

Ans: The specific defects in connective tissue network of pelvis are identified and the anatomic corrections of specific defects are performed in individual woman instead of midline plication in all women. The common sites for defects are:

Anterior vaginal wall: The main support to anterior vaginal wall is due to pubocervical septum which is attached superiorly to pericervical ring and cardinal ligaments, to arcus tendinous fascia of pelvis (ATFP) laterally and pubic tubercle on each side inferiorly. The common defects identified in this support are—central defect in pubocervical septum, paravaginal defect on one or both sides due to detachment of pubocervical septum from ATFP, or transverse apical defect due to detachment of pubocervical septum from pericervical ring.

Posterior vaginal wall: The postvaginal wall is supported by rectovaginal septum which is attached superiorly to pericervical ring and uterosacral ligaments, laterally to levator fascia and inferiorly to perineal body. The common sites of injury to this septum are—transverse apical defect due to detachment from pericervical ring or uterosacral ligaments, midvaginal defects may be central or lateral due to injury or attenuation of levator fascia and inferior defect due to detachment from perineal body or there may be disruption of perineal body.

Q15. How do you diagnose site-specific defects?

Ans: The site-specific defects can be diagnosed by clinical assessment and extensive dissection during surgery.

Clinically these can be identified by examining a woman in lithotomy position during straining and with help of ring forceps, Sims speculum, and bivalve Cusco's speculum. Look for rugosities of vagina which should correlate with pattern of fascial breaks found during surgery.[3]

- Anterior vaginal wall defects can be midline, paravaginal, or transverse apical. To assess them, posterior vaginal wall is retracted by Sims single-bladed speculum and anterior vaginal wall inspected.

Midline defect is suspected if midline bulge is noted when the lateral sulci and apex of vagina are supported with ring forceps. The paravaginal defects appear as blunting or descent of lateral sulcus on either side with straining. Bilateral paravaginal defects are assessed by opening the blades of ring forceps and supporting both lateral sulci. Unilateral paravaginal defects are assessed by supporting each sulcus to the sidewalls separately with closed ring forceps. The transverse defects are seen as distinct bulging out of anterior fornix which is smooth and without rugosities.

- Apical defects are seen in patients with uterine prolapse and are due to detachment of pericervical ring. This can be evaluated by using an open bivalve speculum that is withdrawn slowly while patient is straining when posterior and lateral walls seen bulging with downward mobility of cervix.
- Posterior vaginal wall defects are evaluated while supporting anterior vaginal wall and apex with Sims speculum and gradually withdrawing the single-bladed speculum over

JAYPEE BROTHERS

posterior wall. Upper posterior wall prolapse appears as bulging down of posterior wall of vagina and cul-de-sac and are associated with apical and posterior enteroceles. They are best evaluated by doing rectovaginal examination and palpating for breaks and thickness of rectovaginal septum.

The specific defects become evident only during the intraoperative dissection. Thus irrespective of clinical findings, the extensive dissection should be performed during surgery to identify the defects. After complete dissection, inspection is started for fascial defects keeping in mind the normal anatomy. The fascia is whitish, fibrous and in different plane from underlying visceral fascia. Irrigation with saline may make the color difference obvious. Careful inspection reveals the torn edges. The ability to recognize fascial defects is acquired during careful dissection and observation.

Q16. How does traditional pelvic floor repair differ from site-specific repair?

Ans:

- The traditional prolapse surgery did not emphasize on entire connective tissue network but as organ-specific prolapse, e.g. cystocele, rectocele, etc. and operations focused on reinforcing attenuated tissues surrounding these organs. The support for pelvis is not from ligaments and fascia but from the network of connective tissue that intertwines as it surrounds organs.
- In surgical correction of prolapse by site-specific repair, the portions of this entire network are used to restore the continuity and support the uterus, bladder, rectum, and vagina. The prolapse is considered as hernia and the defects are repaired using nonabsorbable material and use of meshes if the defects are large.
  - The traditional anterior colporrhaphy involves plication of vesicovaginal fascia in the midline after dissection of vagina from bladder using absorbable or delayed absorbable suture material. There is only one midline repair. It does not expose or identify the white line and thus if the woman has a paravaginal defect, this midline plication may aggravate it resulting in recurrence. The site-specific repair involves extensive dissection of vaginal wall and complete exposure of pubocervical fascia/septum from ATFP. The specific defects are identified and accordingly repair is performed using nonabsorbable suture material. The repair sites may be multiple depending on defects.
  - In posterior colporrhaphy, the epithelium of postvaginal wall is dissected and underlying endopelvic fascia of rectovaginal septum is plicated in the midline using chromic catgut, sometimes from vaginal apex to perineal body and levator muscles. Though this corrected midline bulge, it did not correct incomplete emptying and caused dyspareunia in many cases. In site specific the rectovaginal septum is exposed and various defects are identified. There might be multiple suture line in rectovaginal septum after repair and they may be transverse, vertical in midline or laterally. The defects are repaired using nonabsorbable suture material.

Q17. How do you identify and repair enterocele during surgery?

Ans: The enterocele is identified by per speculum examination done under anesthesia just before surgery. The posterior lip of cervix is held by allis forceps and speculum is inserted in

JAYPEE BROTHERS

posterior fornix. The speculum is gradually withdrawn, when a bulge in upper third represents enterocele in which cough impulse may be present. During surgery it is diagnosed after extensive dissection of posterior vaginal wall and identified by peritoneal sac and preperitoneal fat. Unidentified enterocele is common cause of recurrence and efforts should be taken to identify and repair it at the time of primary surgery along with appropriate vault suspension as described below.

- *Repair during vaginal surgery:*
  - *Uterosacral ligament suspension:* At the time of vaginal hysterectomy, enterocele should be dissected free, a high ligature of the peritoneum done by a purse string suture incorporating uterosacral ligaments drawing the cul-de-sac and uterosacral ligaments together and redundant peritoneum excised. The vaginal cuff is attached to cardinal uterosacral ligament complex to avoid descent of vaginal apex.
  - *McCall culdoplasty:* It is a technique for enterocele repair useful when uterosacral ligaments are strong. It consists of rows of internal and external sutures. The internal suture is applied using nonabsorbable suture material and passes through one uterosacral ligament, then peritoneum of cul-de-sac as high as possible to obliterate enterocele sac and then passing through other side uterosacral ligament. The external suture uses delayed absorbable suture material and passes through vaginal wall on one side, ipsilateral uterosacral ligament, peritoneum of cul-de-sac, and then uterosacral ligament of other side, finally coming out through other side vaginal wall. These sutures are tied in the end of surgery after all repairs are completed. It can be used as prophylaxis as well treatment of enterocele at the time of vaginal hysterectomy and also for vault prolapse.
- *Repair during abdominal surgery:* The enterocele can be repaired by Halban technique or Moschcowitz operation.
  - *Halban technique:* The closure of cul-de-sac is done by sewing posterior vaginal wall to the rectum back to front from its most caudal to most cephalad position in parallel rows.
  - *Moschcowitz technique:* The cul-de-sac is closed with sequential concentric purse string sutures placed from caudal post cul-de-sac to the level of uterosacral ligaments incorporating peritoneum over the sacrum.

Q18. What are the common intraoperative complications of prolapse surgery and how can they be prevented?

Ans: The common intraoperative complications include hemorrhage and injury to bladder and rectum.

- Hemorrhage can be reduced by identifying correct tissue planes and morbidity due to hemorrhage can be reduced by raising preoperative hemoglobin of the woman and arranging adequate blood during surgery.
- The injury to bladder and rectum can be reduced by correct technique. Bladder sound may be used if there is difficulty in identifying bladder margins. Intraoperative per rectal examination will help to avoid rectal injury.

JAYPEE BROTHERS

Q19. What is the postoperative care for your patient?

Ans: Postoperative care of woman includes postoperative fluid management, adequate analgesia, prophylactic broad-spectrum antibiotics (e.g. amoxicillin + clavulanic acid 1.2 g and metronidazole 500 mg perioperatively), minimum duration of postoperative catheterization depending on extent of bladder dissection, and type of surgery performed; early ambulation, good perineal hygiene, and monitoring for vital signs and bleeding.

Q20. What are common causes for failed prolapse surgery?

Ans: *The common reasons for failure or recurrence of prolapse surgery can be any of the following:*

- Wrong choice of surgical procedure
- Poor surgical technique
- Omission to recognize and treat enterocele
- Shortening of anterior vaginal wall
- Inherent weakness of supports
- Pregnancy and delivery following operation.

Q21. What is role of laparoscopic surgery in treatment of POP?

Ans: The techniques used abdominally for pelvic organ prolapse can also be performed laparoscopically with advantage of minimally invasive techniques. With laparoscopy, surgeons are repairing not only apical supports but all compartments of pelvic floor using synthetic mesh grafts. Laparoscopic sacral colpopexy is the most commonly performed procedure. Recurrent prolapse and need for repeat surgery is probably more common after vaginal procedures when compared with sacral colpopexy. The advantages of laparoscopic route are reduced incidence of recurrent prolapse (23% vs 41%), dyspareunia, SUI less blood loss and less postoperative hospitalization as compared with vaginal repair.[9] The disadvantages include longer operating time, higher costs, deep learning curve, and mesh-related complications.

Robotic-assisted laparoscopic surgery is devised to shorten learning curve associated with traditional laparoscopic surgery for prolapse. Current literature on this approach is limited and there is need for more data to substantiate the results.

CASE 2

A 27-year-old Mrs Y, Para 2 presents with third degree uterovaginal prolapse. How will you proceed?

History: The detailed history should be taken with special emphasis on poor nutrition, poor intrapartum care, early return to activity after delivery, any other factors suggestive of congenital weakness of tissues like hernia, prolapse rectum, etc. as prolapse at such a young age is not very common. Any urinary or bowel symptoms should be asked to help in planning treatment.

General examination should specifically look for spina bifida and other neurological problems which may contribute to prolapse in young woman. Local examination should assess degree of cervical descent, elongation of cervix and whether it is supra or infravaginal, sites of anterior and posterior vaginal wall defects, tone of pelvic floor muscles.

JAYPEE BROTHERS

POPQ staging of my patient is stage III Ba, lithotomy with straining. The quantification is as follows **(Fig. 3)**:

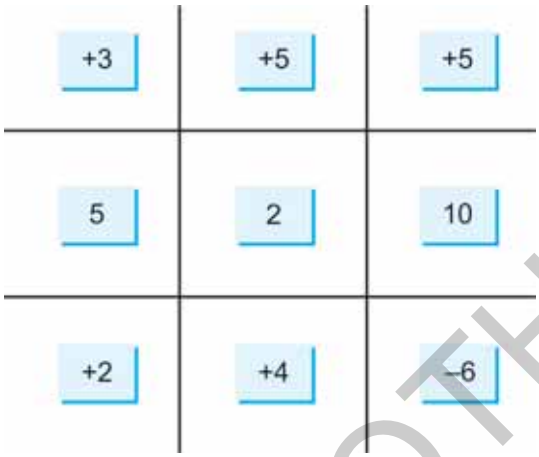

Fig. 3: Pelvic organ prolapse quantification system (POPQ) staging of Mrs Y.

Q22. How will you treat your patient?

Ans: Taking into consideration young age and parity of the woman the preservation of future fertility is important. Unless the problem is severe, the women should be advised to complete the childbearing so that definitive treatment can be offered. Ring pessary provides temporary relief, permits intercourse, and can be offered till she completes childbearing after thorough counseling.

The definitive treatment in this case is surgical. Though various operations which can be considered first choice would be *Manchester operation* which is appropriate in young woman with any degree of prolapse. Though uterus is conserved, there may be some effect on future childbearing in form of increased incidence of infertility, mid-trimester abortions, preterm delivery, and cervical dystocia and this should be discussed with the woman.

Q23. What are the main components of Manchester operation?

Ans: *The main components of Manchester operation are:*

- Dilatation and curettage done first to rule out any associated endometrial pathology.
- Anterior colporrhaphy
- Amputation of cervix
- Anterior plication of Mackenrodt's ligament and other paracervical tissues in front of cervix
- Sturmdorf suture to cover amputated cervix
- Repair of enterocele and posterior colpoperineorrhaphy if necessary.

The intraoperative complications include bleeding and injury to surrounding structures. The postoperative complications include bleeding, infection on short term, and recurrence of prolapse on long term.

Q24. What are the other operations which can be performed in this woman?

Ans: *Shirodkars modification of Manchester operation*: In this vaginally performed operation, after giving circular incision on cervix, vaginal flaps are dissected. After bladder dissection, the

JAYPEE BROTHERS

pouch of Douglas is opened, uterosacral ligaments are dissected, detached from its cervical attachment, brought anteriorly and crossed in front of cervix. Enterocele is then repaired by excising and closing peritoneum and obliterating the space by approximation of uterosacral ligaments. The anterior colporrhaphy and postcolpoperineorrhaphy is then performed. The advantage of this operation over Manchester is that amputation of cervix with its effect on childbearing is avoided and opening of cul-de-sac allows better repair of enterocele. It may not be suitable for women with elongation of cervix.

Sling operations: In young or nulliparous woman with prolapse there is congenital weakness of supporting tissues and these abdominal operations aim at supporting weak ligaments by various natural or synthetic slings. The point of attachment of slings and material used as sling varies with technique. The enterocele if present should be repaired by Moschcowitz or Halban technique. They do not affect future fertility. They should be avoided when there is procidentia, infected hypertrophied cervix, marked elongation of cervix.

Various types of sling operations are as follows:

- *Khannas operation*: The sling is made of mersilene tape and is attached posteriorly to cervix, passes retroperitoneally to be attached to anterior superior iliac spine. Vaginal delivery is allowed.
- *Shirodkars sling operation*: The sling is prepared from fascia lata or mersilene tape. It is attached to cervix posteriorly at one end and follows the course of uterosacral ligaments retroperitoneally to be attached to the intervertebral disc between L5 and S1. It is difficult technically. The woman can have vaginal delivery.
- *Purandares sling operation*: The sling is fashioned from two strips of anterior rectus sheath which remain attached at one end and other end goes along course of round ligaments through internal inguinal ring to get attached to anterior lip of cervix. The woman can deliver vaginally but there can be a problem if she needs LSCS and incision should be made above the level of attachment of strip. The disadvantage is that it relies on intrinsic strength of rectus sheath which may not be good in woman developing prolapse at young age.

Other uterus preserving surgeries: These can be done by vaginal, abdominal, and laparoscopic route. The vaginal techniques include uterosacral cervical ligament plication, sacrospinous hysteropexy, and posterior vaginal slingplasty. They have advantage of shorter operating time but effectiveness studies are poor quality. Abdominal hysteropexy techniques transfixing uterus to anterior abdominal wall, pectineal ligament, and sacral promontory have been described of which abdominal sacrohysteropexy using synthetic mesh is the commonest. Laparoscopic uterine suspension methods include ventrosuspension using round ligaments, uterosacral plication, sacral suture hysteropexy, uterine sling suspension, and oxford hysteropexy most of which use mesh.

CASE 3

A 35-year-old Mrs Z, Para 3 comes with abdominal swelling during coughing and mass descending per vaginum since 2 years. She has undergone abdominal hysterectomy for fibroid

JAYPEE BROTHERS

for detailed information on obstetrics & gynecology books, visit our website **www.jaypeebrothers.com,** for detailed information

Case Discussions in Obstetrics & Gynecology

Salient Features

- Covers all practical aspects of Obstetrics and Gynecology from the point of view of both, Undergraduate and the Postgraduate examinations (MBBS/MD/MS/DGO/DNB)
- Tries to present the near ideal case discussion in obstetrics and gynecology seen on a daily basis in the form of questions and answers by teachers who have vast experience in practical management of cases and conducting undergraduate and postgraduate examinations
- Includes almost all commonly encountered cases in both, obstetrics and gynecology
- Contains commonly/usually asked viva questions in case discussions in practical examinations. Even in a single topic/case different situations have been created to include a wide spectrum of questions
- Includes recent advances in the corresponding topics
- Promises to be of great help to both trainees and practitioners in obstetrics and gynecology.

Available at all medical bookstores
or buy online at www.jaypeebrothers.com



JAYPEE BROTHERS
Medical Publishers (P) Ltd.
www.jaypeebrothers.com

Join us on facebook.com/JaypeeMedicalPublishers

Shelving Recommendation
OBSTETRICS & GYNECOLOGY

ISBN 978-93-89587-31-9

