hers.com, for detailed information on radiology books, visit our website www.jaypeebrothers.com, for detailed information on radiology books

Celebrating 50 YEARS
Passion, Quality and Innovation in Healthcare Publishing

AIIMS-MAMC-PGI IMAGING SERIES



DIAGNOSTIC RADIOLOGY

Genitourinary Imaging

Editors
Anju Garg
Manavjit Singh Sandhu
Arun Kumar Gupta

Associate Editors
Gaurav Shanker Pradhan
Alpana Manchanda
Sapna Singh

4th Edition

JAYPEE

Contents

SECTION 1
UPPER URINARY TRACT

1. **Imaging Techniques and Radiological Anatomy of the Upper Urinary Tract** 3
   Sapna Singh, Jyoti Kumar, Anjali Prakash

2. **Current Status of Nuclear Medicine in Urinary Tract Imaging** 38
   Rakesh Kumar, Madhavi Tripathi

3. **Renal Calculus Disease and Obstructive Uropathy** 57
   Uma Debi, Mahesh Prakash, Mandeep Kang

4. **Renal Parenchymal Disease** 74
   Sreedhara BC, Anupam Lal, Anindita Sinha

5. **Nontubercular Infections of the Urinary Tract** 93
   Ujjwal Gorsi, Naveen Kalra, Ajay Kumar

6. **Tubercular Infection of the Urinary Tract** 105
   Ashu Seith Bhalla, Priyanka Naranje, Arun Kumar Gupta

7. **Renal Cystic Diseases** 121
   Jyoti Kumar, Anjali Prakash, Sapna Singh

8. **Renal Neoplasms** 137
   Anjali Prakash, Gaurav Shanker Pradhan, Rashmi Dixit

9. **Renovascular Hypertension** 173
   Sanjeev Kumar, Vineeta Ojha, Sanjiv Sharma

10. **Imaging of Renal Transplant** 196
    Ajay Gulati, Manavjit Singh Sandhu, Tulika Singh

SECTION 2
LOWER URINARY TRACT

11. **Imaging Techniques and Radiological Anatomy of Lower Urinary Tract** 211
    Gaurav Shanker Pradhan, Satyam, Jyoti Kumar

12. **Urinary Bladder and Urethral Diseases** 223
    Anupam Lal, Paramjeet Singh, Harish Bhujade

SECTION 3
FEMALE GENITAL TRACT

13. Imaging Techniques and Radiological Anatomy of Female Genital Tract **245**
Swati Gupta, Sapna Singh, Anju Garg, Satyam

14. Benign Adnexal Disease **264**
Anju Garg, Alpana Manchanda, Radhika Batra

15. Malignant Ovarian and Tubal Disease **312**
Smita Manchanda, Surabhi Vyas, Manisha Jana

16. Benign Diseases of the Uterus and Vagina **332**
Rashmi Dixit, Anju Garg, Alpana Manchanda

17. Malignant Diseases of the Uterus and Vagina **358**
Alpana Manchanda, Anju Garg, Gaurav Shanker Pradhan

18. Female Infertility **390**
Radhika Batra, Rashmi Dixit, Swati Gupta

SECTION 4
MALE GENITAL TRACT

19. Imaging Techniques and Radiological Anatomy of the Male Genital Tract **415**
Anmol Bhatia, Paramjeet Singh, Sameer Vyas

20. Disorders of the Prostate Gland **423**
Ujjwal Gorsi, Paramjeet Singh, Anupam Lal

21. Scrotal Diseases **439**
Anupam Lal, Manphool Singhal, Sreedhara BC

22. Male Infertility and Erectile Dysfunction **456**
Deep Narayan Srivastava, Chandan J Das

SECTION 5
MISCELLANEOUS

23. Imaging of the Adrenal Gland **473**
Devasenathipathy Kandasamy, Raju Sharma, Arun Kumar Gupta

24. The Retroperitoneum **497**
Smriti Hari, Sanjay Sharma, Ekta Dhamija, Ankur Goyal

25. Urinary Tract Trauma **518**
Atin Kumar, Shivanand Gamanagatti

SECTION 6
INTERVENTIONS

26. Nonvascular Interventions in the Urinary Tract **537**
Mandeep Kang, Naveen Kalra, Ujjwal Gorsi, Sreedhara BC

27. Vascular Interventions in the Genitourinary Tract **552**
Shivanand Gamanagatti, Ankur Goyal, Deep Narayan Srivastava

Index *571*

Chapter 4

Renal Parenchymal Disease

Sreedhara BC, Anupam Lal, Anindita Sinha

Disorders of renal function are ubiquitous in contemporary practice of medicine. Kidney disease manifestations may vary from complete asymptomatic cases to life-threatening emergencies. Insight into the causes and consequences of medical renal disease has progressively increased over the last decade, and radiological imaging has played a pivotal role in this improved understanding.

DEFINITION AND CLASSIFICATION OF KIDNEY DISEASE

The term renal failure encompasses the spectrum of diseases from acute and reversible to chronic and irreversible. It is broadly divided into two categories which are described here.

Acute Kidney Injury

Acute kidney injury (AKI), also termed as acute renal failure previously is defined as a rapid deterioration in renal function, characterized by progressive azotemia (best measured by serum creatinine) which may or may not be accompanied by oliguria (urine output <400 mL/day). The cardinal feature of AKI is decline in glomerular filtration rate (GFR). According to Acute Kidney Injury Network (AKIN) criteria,[1] AKI is diagnosed if one of the following is present:

- An abrupt (within 48 hours) reduction in kidney function (defined as an absolute increase in serum creatinine of more than or equal to 0.3 mg/dL (≥26.4 µmol/L), or percentage increase in serum creatinine of more than or equal to 50% (1.5-fold from baseline).
- Reduced urine volume less than 0.5 mL/kg/h for 6 hours. There is sudden and often temporary loss of renal function, which is frequently reversible, with less than 20% cases ultimately requiring renal replacement therapy.[2] Imaging is, therefore, directed at identifying correctable causes of acute renal insult. Most common causes include acute tubular necrosis (ATN), severe dehydration, tubular blockade, infection, and obstruction.

Chronic Kidney Disease

The diagnosis of chronic kidney disease (CKD) implies a persistent abnormality in GFR with a wide range of causes. Slow progressive loss of kidney function over a span of years occurs, resulting in permanent kidney damage. CKD is defined as sustained kidney damage greater than 3 months duration resulting in a GFR of less than 60 mL/min/1.73 m^2.[2]

For purposes of diagnosis and management, renal failure can be divided into three categories which are as follows:

1. *Prerenal*: Diseases caused by any process that decreases perfusion to kidneys in which the integrity of renal parenchymal tissue is preserved.
2. *Intrarenal*: Diseases affecting renal parenchymal tissue (which can be further divided into vascular, glomerular, and tubular diseases).
3. *Postrenal*: Diseases associated with obstruction of the urinary tract or venous blood flow. It is also known as "surgical renal failure" as it is often amenable to correction.

This chapter is designed to give a contemporary insight of the intrarenal causes of acute and chronic kidney disease—"*Medical Renal Diseases*".

JAYPEE BROTHERS

Table 1: Causes of acute renal failure.

Prerenal	*Intrarenal*	*Postrenal*
• Hypovolemia • Cardiogenic shock • Anaphylaxis • Sepsis • Renal artery stenosis • Severe dehydration	• *Acute tubular necrosis:* – Hemolysis – Antibiotics – Contrast nephrotoxicity • *Glomerulopathy:* – SLE – HSP – Postinfective glomerulonephritis • Papillary necrosis • *Vascular diseases:* – PAN, scleroderma	• Renal vein thrombosis • *Obstruction due to:* – Calculi – Hemorrhage – Tumor

(SLE: systemic lupus erythematosus; HSP: Henoch-Schönlein purpura)

Table 2: Causes of chronic renal failure.

Prerenal	*Intrarenal*	*Postrenal*
• Renal artery stenosis • Chronic dehydration • Congestive heart failure • Cirrhosis	• *Common causes:* – Diabetic nephropathy – Hypertensive – Glomerulosclerosis • Glomerulonephritis • Congenital ADPKD • Renal tubular acidosis • Drugs • TB • *Systemic diseases:* – FSGS – Gout – AIDS nephropathy – Scleroderma	• Posterior cortical value • Neurogenic bladder • Ureteric/bladder outlet obstruction • Retroperitoneal fibrosis • Tumor encasement

(ADPKD: autosomal dominant polycystic kidney disease; TB: tuberculosis; FSGS: focal segmental glomerulosclerosis)

Various causes of acute and chronic kidney disease are enumerated in **Tables 1 and 2**.[2]

ROLE OF IMAGING IN RENAL FAILURE

Overlapping imaging findings are seen in renal failure. Comprehensive evaluation should be done in a particular case which includes clinical profile, laboratory findings, and histopathology along with imaging to arrive at a conclusive diagnosis.

The role of imaging in renal failure is to segregate the surgical and medical conditions resulting in renal insufficiency.[1] Goals for radiological studies in renal failure are as follows:

- Exclusion of correctable causes of acute renal failure (e.g. obstruction and thrombosis).
- Estimation of renal size to differentiate acute parenchymal disease from chronic parenchymal disease.

Once obstruction is excluded, prerenal and postrenal causes of renal failures can be managed medically.

Radiological Approach to Renal Parenchymal Disease

Most diseases affecting the parenchyma of the kidney may produce lesions detectable only by electron or light microscopy, or by deranged renal function. However, some pathological processes manifest as renal morphological abnormalities and may be diagnosed by radiological imaging.

Morphological criteria are useful to categorize the wide spectrum of renal parenchymal diseases. Evaluation is done based on renal size, contour abnormality, and laterality of involvement **(Flowchart 1)**.

Renal size is an important diagnostic criterion. Large kidneys result from accumulation of fluid, deposition of proteins, inflammatory or neoplastic infiltrates, and hypertrophy secondary to glomerular, microvascular or cellular proliferation. Small kidneys result from loss of renal substance due to atrophy, hypoplasia, necrosis or fibrosis.

JAYPEE BROTHERS

Flowchart 1: Morphological criteria to categorize renal parenchymal disease (size, contour, and laterality).

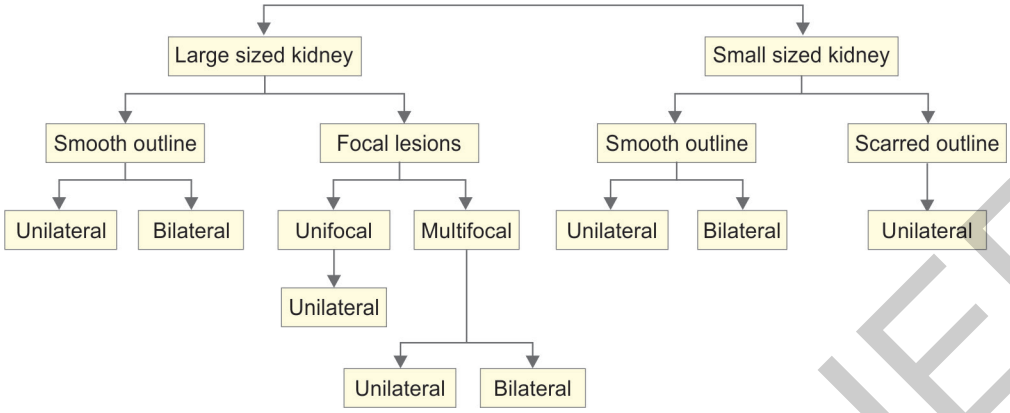

Renal contour is another useful indicator. If a disease causes global reduction in renal mass, parenchymal bulk is uniformly lost and its size decreases with smooth contour. This is ascertained by preserved interpapillary line, which is a useful landmark for evaluating loss of renal parenchyma. Interpapillary line is drawn through the tips of papilla (base of the calyces) **(Fig. 1)**, the distance from this line to lateral surface of kidney is the renal parenchymal thickness which averages to 2.5–3 cm. It is greater at polar calyces ranging up to 3.5 cm. Distances less than 2 cm are suggestive of parenchymal loss while those greater than 3.5 cm indicate mass lesion or infiltration.[4]

Assessment of renal contour may show a deviation when there is focal loss or regional expansion. Laterality indicates nature of the disease. Bilateral renal lesions are usually found in systemic disorders in which total renal mass is affected.[5,6]

Radiological imaging in renal parenchymal disease is usually targeted to reach a set of differential diagnosis, with distinct morphological description. "Bilateral large smooth kidney" constitutes to the group of acute renal parenchymal disease, while "bilateral small smooth kidney" falls into description of chronic renal parenchymal disease.

Imaging Techniques

Recent advancements in all the fields of imaging have led to better evaluation of renal diseases and their improved management. Imaging studies performed for evaluating the kidney diseases can provide anatomic, functional, and metabolic information. To reach a diagnosis for a particular case, it is important to know the benefits and the limitations along with the diagnostic yield of each modality.

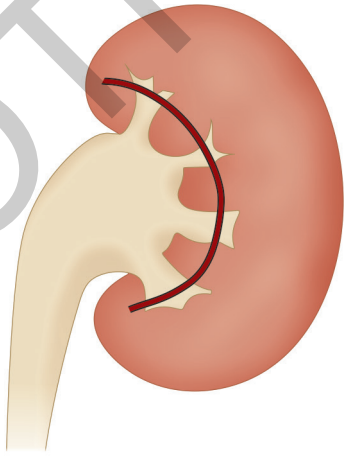

Fig. 1: Schematic diagram of normal interpapillary line. This line is drawn by joining the tips of renal papillae; smooth uninterrupted interpapillary line is seen in normal kidney.

Plain Radiography and Urography

The plain film also known as KUB (kidney, ureter, and bladder), has been used for years as the first step in the evaluation of the kidneys, however it gives little significant information on its own. Role of plain radiography is to detect renal parenchymal calcification and calculi. In an acute emergency setting, plain X-ray can be used to assess perinephric or retroperitoneal air foci, as seen in cases of emphysematous pyelonephritis **(Fig. 2)**. Renal size and contour may be estimated if the renal outlines can be visualized. Renal size is approximately equal to 3–4 lumbar vertebral body height. Normal kidney measures 10–14 cm in men and 9–13 cm in women on conventional radiography and 1–2 cm less on ultrasonography. Generally, right kidney is smaller than the left by about 0.5 cm. In clinical setting, discrepancy in renal size of

JAYPEE BROTHERS

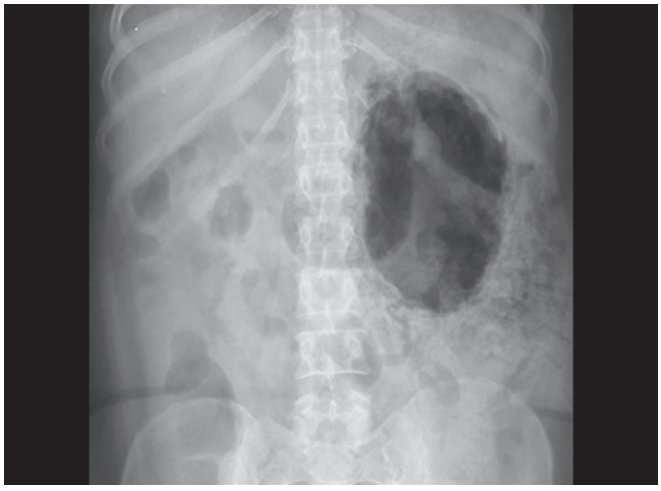

Fig. 2: Extensive gas overlying left renal parenchyma and perinephric space in a case of emphysematous pyelonephritis.

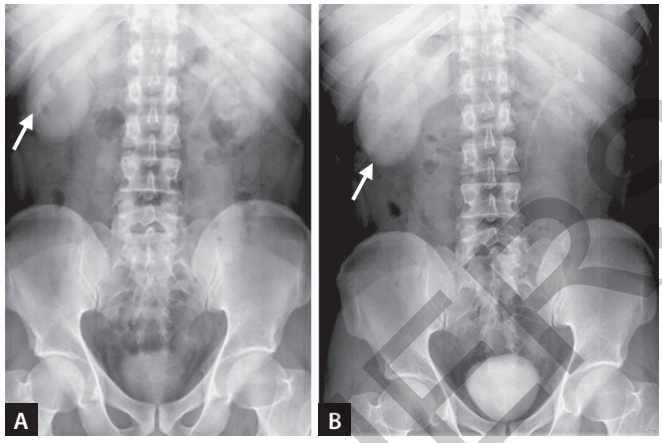

Figs. 3A and B: Increasing dense nephrogram. Intravenous urogram shows increased nephrographic density (arrows) on 2-hour film as compared to 5-minute nephrographic phase. Patient had right-sided urinary obstruction because of a small tumor near the right vesicoureteric junction.

more than 2 cm is considered significant.[3] In this era of cross-sectional imaging, urography is more of historic importance; however, interesting abnormal nephrographic patterns present in certain sets of diseases, were described by Fry and Cattell, which are as follows:[7]

- Immediate faint persistent nephrogram—chronic glomerular disease.
- Increasingly dense nephrogram—acute renal obstruction, hypotension, renal ischemia, acute glomerular disease, intratubular obstruction, and acute renal vein thrombosis **(Figs. 3A and B)**.
- Immediate dense persistent nephrogram—ATN and severe inflammatory renal disease.

Striated nephrogram is a variant of obstructive nephrogram which may also be encountered in other conditions like pyelonephritis, polyarteritis nodosa (PAN), trauma, and medullary cystic kidney disease. Prominent cortical nephrons are seen extending into the medulla as "medullary rays".

Ultrasonography

Ultrasonography is initial imaging modality for azotemia as it is noninvasive and readily differentiates between obstructive (surgical) and nonobstructive (medical) causes of renal failure **(Fig. 4A)**.[6] Renal sizes, cortical thickness, echogenicity of the kidneys, and the presence or absence of hydronephrosis are easily assessed on ultrasonography. Renal size and parenchymal thickness are useful parameters to assess chronicity of renal disease **(Fig. 4B)**. Enlarged kidneys indicate an acute parenchymal lesion while contracted small kidneys suggest a chronic disease. Renal cortical echogenicity is an important indicator for the diagnosis of renal parenchymal disease. Normally the echogenicity of renal cortex is less than liver or spleen; the demonstration of increased echogenicity of the renal cortex under standard scanning techniques may be useful in suggesting the presence of renal parenchymal (medical renal) disease. Renal corticomedullary differentiation (CMD) may be preserved, obliterated or accentuated depending on the severity of renal cortical echoes **(Figs. 4C to F)**.[8,9]

Increased cortical echogenicity with preserved CMD may be seen in glomerulonephritis, nephrosclerosis, amyloidosis, acute leukemia, ATN, and Alport's syndrome while cortical echogenicity is decreased in lymphoma, acute pyelonephritis, and renal vein thrombosis. Increased medullary echotexture is found in gouty nephropathy, medullary nephrocalcinosis, and medullary sponge kidney. Interestingly, some authors recognize the altered state of hydration at the time of scanning as one of determining factors influencing the renal cortical echotexture of the patient.[9,10] An extracapsular hypoechoic rim of edema may surround the kidneys in renal failure. This finding when present is usually bilateral and is called as "kidney sweat sign".[11]

Ultrasound examination is also valuable for assessing the kidneys for follow-up of renal parenchymal disease. Changes in renal size, progression as well as resolution of the disease can easily be monitored on ultrasonography.

Color Doppler

Color Doppler is a handy, easily available, and noninvasive tool for evaluation of renal blood vessels. Normal renal arterial branching pattern is well-appreciated on color

JAYPEE BROTHERS

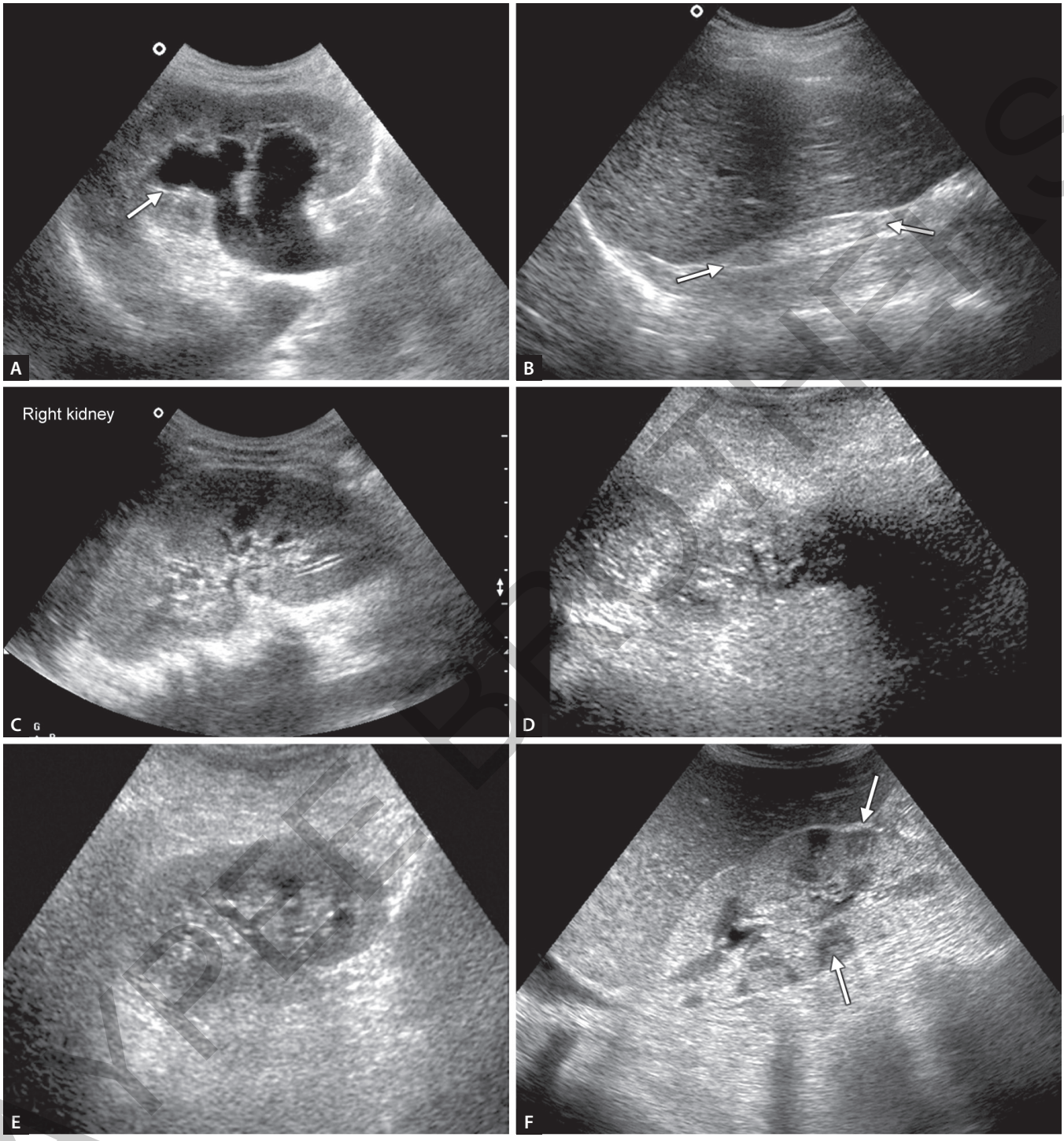

Figs. 4A to F: (A) Obstructive renal failure with distal ureteric calculus: Longitudinal ultrasound (US) image depicts marked dilatation of the pelvicalyceal system (arrow). Note the upper ureter is also dilated. (B) Chronic renal failure: US image shows small smooth kidney with markedly decreased renal parenchymal thickness. (C to F) Acute renal parenchymal disease US images. (C) Slightly raised cortical echogenicity and lack of renal corticomedullary differentiation. (D) Markedly increased parenchymal echoes nearing to that of renal sinus resulting in loss of corticomedullary differentiation. (E) Hyperechoic renal cortex, relatively prominent renal medulla with accentuated corticomedullary differentiation. (F) Complicated pyelonephritis with multiple renal abscesses: Severely raised cortical echoes and few hypoechoic well-defined parenchymal lesions (abscesses) (arrows) with right pleural effusion.

JAYPEE BROTHERS

flow imaging. Assessment of spectral wave pattern and flow indices of renal arteries can be done. Vascular resistance (resistive index: RI) and pulsatility (pulsatility index) along with absolute flow velocities of the main, intralobar, and arcuate arteries may be calculated. Out of these indices RI is most commonly used. It is calculated as:

$$\text{Resistive Index} = \frac{\text{Peak systolic velocity} - \text{Lowest diastolic velocity}}{\text{Peak systolic velocity}}$$

Normal RI is less than 0.7. Parenchymal diseases with tubulointerstitial or vascular involvement cause increased RI (>0.7), while glomerular diseases do not cause any significant increase in this parameter.[12] Elevated RI correlates with the severity of disease in systemic lupus erythematosus (SLE), hemolytic uremic syndrome (HUS), diabetes, and hepatorenal syndrome **(Fig. 5)**.[5]

Contrast-enhanced Ultrasound

Contrast-enhanced ultrasound (CEUS) is an alternative imaging modality to contrast-enhanced computed tomography (CECT) in the evaluation of renal parenchymal diseases, urinary tract infections, and associated complications. The elimination properties of microbubbles through lungs make CEUS an attractive nontoxic imaging modality in renal insufficiency patients. It can also be performed at the bedside in sick patients, and a useful modality in assessing claustrophobic patients and children who cannot tolerate CT or magnetic resonance imaging (MRI) without sedation.

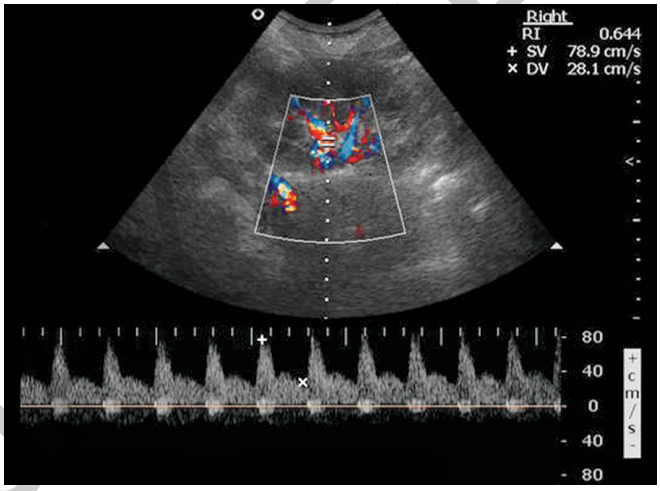

Fig. 5: Normal Doppler ultrasound. Doppler spectra obtained in the area of interlobar arteries show a sharp systolic peak and prominent antegrade flow during diastolic phase. Resistive index in this patient is 0.64, which is normal.

Contrast-enhanced ultrasound showed almost equal sensitivity and specificity to CT in detecting renal parenchymal changes associated with pyelonephritis.[13] CEUS features suggestive of pyelonephritis include peripheral wedge-shaped perfusion defects and heterogeneous enhancement, similar to CECT but without the exposure to radiation. CEUS is also useful in measurement of renal perfusion in AKI, to rule out ischemic perfusion injury, and is more accurate method than Doppler. In postrenal transplant patients with acute rejection, CEUS can detect regional perfusion defects of the allograft.

Computed Tomography

Computed tomography has a specific role in evaluation of renal failure. In acute renal failure noncontrast computed tomography (NCCT) scan of kidneys may show parenchymal calcification. Renal parenchyma, however, appears homogenous in attenuation on NCCT. Various nephrographic patterns are demonstrated after the administration of contrast. Differential diagnosis of the nephrographic patterns used on urography is similarly applied to CT nephrogram. Excretory function can further be assessed on sequential dynamic imaging.[14]

Magnetic Resonance Imaging

Routine MRI evaluation of the kidney includes axial and coronal T1-weighted (T1W) and T2-weighted (T2W) spin echo sequences, with or without fat suppression. CMD is distinctly seen on T1W and T2W images. In normal kidney, the cortex is slightly higher in signal intensity than the medulla on T1W images while renal medulla is hyperintense to cortex on T2W images **(Figs. 6A to D)**. In a normal well-hydrated kidney, sharp CMD is seen on T1W sequence due to high signal of cortex as compared to medulla. Wide variety of renal medical diseases cause decrease in cortical signal and subsequent loss of CMD. Loss of CMD on T1W spin echo sequences is a sensitive indicator of parenchymal diseases and correlates with elevated serum creatinine levels >3.0 mg/dL. Dynamic contrast-enhanced T1W sequences can also be done. CMD is lost on postgadolinium dynamic MRI when serum creatinine is >8.5 mg/dL.[15]

Diffusion-weighted imaging (DWI) is sensitive to changes in the renal interstitium during cellular infiltration or edema, renal fibrosis, and in renal perfusion. The most promising application of DWI so far is in fibrosis estimation in CKD and guidance for biopsy in acute graft dysfunction.[16] Apparent diffusion coefficient (ADC)

JAYPEE BROTHERS

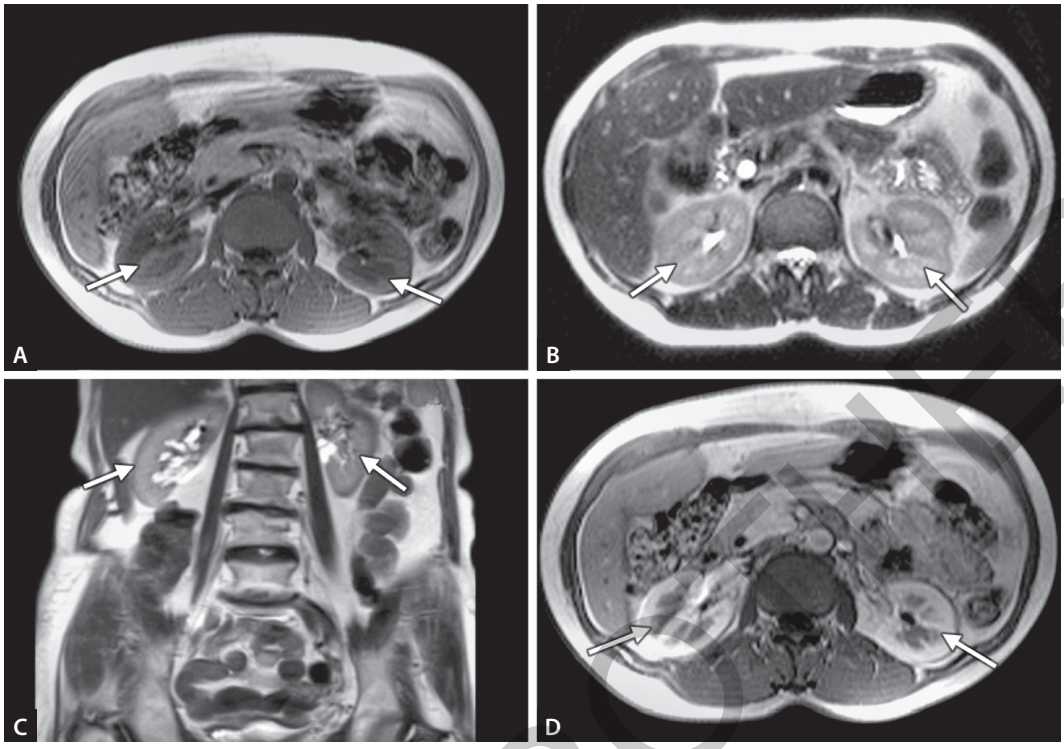

Figs. 6A to D: Normal spin echo magnetic resonance imaging findings: (A) T1-weighted axial image shows corticomedullary differentiation resulting from high signal intensity of normal renal cortex and lower signal intensity of renal medulla (arrows). (B and C) T2-weighted axial and coronal magnetic resonance (MR) images depict the hyperintensity of normal renal medulla as compared to renal cortex (arrows). (D) Postgadolinium dynamic MR in cortical phase reveals the striking distinction between renal cortex and medulla (arrows).

values correlate with renal function, usually estimated by creatinine values. The cortical ADC values show good correlation with cortical fibrosis and chronic lesions (reduction in ADC values with increasing grade of CKD), however, at present no clear cut-off of ADC values can be chosen to differentiate CKD versus healthy kidney due to limitations in image resolution, protocol variability, and interindividual variability. Diffusion tensor imaging (DTI) is another noninvasive tool to assess renal function with medullary fractional anisotropy values significantly lower in patients with CKD than in healthy controls similar to ADC.[17] Arterial spin labeling (ASL) is a powerful tool for noninvasive measurement of regional renal perfusion in humans, with a typical in plane resolution of 2–3 mm. It uses magnetic labeling of water in arterial blood as an endogenous tracer to generate maps of absolute regional perfusion without requiring exogenous contrast. The studies performed so far have shown reproducible measurements of renal perfusion from both renal cortex and medulla, and ASL is highly suited to repeated measurements. The renal perfusion values reduce with increasing stage of CKD and correlates to estimated glomerular filtration rate (eGFR).[18]

Renal Angiography

Renal angiography has limited role in renal parenchymal disease as it is an invasive procedure and usually requires large amount of iodinated contrast medium. Characteristic appearances like aneurysmal dilatation of medium and small-sized vessels on arteriography are seen in conditions like PAN, granulomatosis with polyangiitis, and SLE. Pruned, tortuous vessels with slow flow with thinned renal cortex are demonstrated. Lucent or mottled nephrogram may be seen. Renal artery stenosis is most accurately diagnosed on angiography and can be treated by angioplasty.[19]

Radionuclide Imaging

Scintigraphy provides imaging based diagnostic information on renal structure and function. Radionuclide agents are excreted by kidneys; hence, they should be judiciously employed in patients with renal failure. ^{99m}Tc-DTPA (diethylenetriaminepentaacetic acid) is excreted solely by the glomerular filtration, therefore it should not be used frequently. Tubular secretion of ^{99m}Tc-MAG3 (mercaptoacetyltriglycine) and Hippuran I-131 occurs, hence these may be utilized in severe renal insufficiency.[20]

JAYPEE BROTHERS

Contrast-induced Nephropathy

The presence of renal failure may pose some limitations on the choice of an individual imaging modality. Iodinated contrast media may cause exacerbation of renal insufficiency. Contrast-induced nephropathy (CIN) is one of the common causes of hospital-acquired acute renal failure (ARF). The exact mechanism of CIN is still unknown, but it is thought to be multifactorial.[21] CIN is defined as either 0.5 mg/dL (44 µmol/L) increase in absolute serum creatinine value within 48–72 hours or 25% increase in serum creatinine from baseline after administration of intravascular contrast material when no other cause of renal injury is readily apparent.[22] The rise in serum creatinine usually peaks at 3–5 days and return to baseline within 10–14 days. The most important risk factor is pre-existing renal insufficiency (serum creatinine >1.5–2.0 mg/dL), followed by diabetes mellitus, advancing age, congestive heart failure, dehydration, high dose of contrast media, and furosemide. Adequate hydration, dose reduction, and use of nonionic contrast media are recommended as preventive measures.

IMAGING IN RENAL PARENCHYMAL DISEASE

Acute Renal Parenchymal Disease

Radiographic appearance of "bilateral, large, smooth" kidneys is usually seen in the setting of renal failure of recent onset. When obstruction is ruled out a similar picture of enlarged smooth kidneys with normal or effaced collecting system is seen that indicates parenchymal disease of recent origin, which is possibly reversible. **Box 1** and **Table 3** enumerate the causes of renomegaly based on morphological criteria.[4]

However, in some conditions certain characteristic appearances are seen in imaging which shall be discussed in the next section of this chapter. Infections, cystic renal diseases, obstructions, renal vascular diseases, and tumors are not included here as they are covered in other chapters in this book.

Box 1: Causes of bilateral large smooth kidneys.[5]

- Proliferative/necrotizing disorders
- Acute glomerulonephritis
- Polyarteritis nodosa (microscopic form)
- Systemic lupus erythematosus
- Granulomatosis with polyangiitis
- Allergic angiitis
- Diabetic glomerulosclerosis
- Lung hemorrhage and glomerulonephritis (Goodpasture's syndrome)
- Anaphylactoid purpura (Henoch-Schönlein syndrome)
- Thrombotic thrombocytopenic purpura
- Focal glomerulonephritis associated with subacute bacterial endocarditis
- Plasma cell dyscrasias
- Multiple myeloma
- Waldenstrom's macroglobulinemia
- Amyloidosis
- Abnormal glycogen deposition
- von Gierke's disease (Glycogen storage disease type-I)
- Abnormal lipid deposition
- Fabry's disease
- *Abnormal fluid accumulation:*
  - Acute tubular necrosis
  - Acute cortical necrosis
- Leukemia
- Acute interstitial nephritis
- Acute blockage of tubules
- Acute urate nephropathy
- Tamm-Horsfall protein
- Acute myeloma nephropathy
- Acromegaly
- Nephromegaly associated with cirrhosis, hyperalimentation, and diabetes mellitus
- Hemophilia
- Homozygous-S disease
- Tyrosinosis type I
- Infectious mononucleosis
- Autosomal recessive polycystic kidney disease
- Physiological response to contrast material and diuretics

Table 3: Large kidney with focal lesion.[5]

Unifocal unilateral	*Multifocal*	
	Bilateral	*Unilateral*
• Simple cyst • Focal hydronephrosis • *Benign neoplasm:* – Adenoma – Mesenchymal tumor – Inflammatory mass • *Malignant neoplasm:* – RCC – Sarcoma – Metastatic deposit	• Autosomal dominant polycystic kidney disease • Lymphoma • Acquired cystic kidney disease	• Multicystic kidney disease Xanthogranulomatous • Pyelonephritis • Malakoplakia

JAYPEE BROTHERS

Acute Tubular Necrosis

Acute tubular necrosis is the most frequent cause of AKI in the renal category. An acute clinical event with ischemic cascade or nephrotoxic agents **(Table 4)** results in ATN.[23] The multicentric observational study concluded with the ischemic ATN as the presumed etiology for ~50% of patients with renal failure, ~12% related to the unresolved prerenal causes, and ~25% were related to the nephrotoxic agents.[24] Generally, ATN follows a pattern of sequential manifestations including the initiation [reduced GFR, with increased creatinine and blood urea nitrogen (BUN)], maintenance (stabilization of low GFR over 1–2 weeks with increased serum creatinine and BUN), and recovery (polyurea with return of serum creatinine and BUN to preinjury level) phases. When the hypoperfusion overwhelms the renal autoregulatory mechanisms, the tubular cell injury (especially at loop of Henle dipping into the medulla) is initiated, but not always, leading to the cellular death. Ischemia leads to the formation of apical blebs and loss of brush border membrane in proximal tubular cells followed by the loss of cell polarity and integrity of tight junctions resulting in ineffective filtration. Cellular casts block the tubular lumen and adds on to the underlying hypoperfusion complex resulting in decreased GFR. Acute tubule or cell damage resulting from the ischemic or nephrotoxic agents follows almost the similar pattern and the altered pathophysiological events.[25]

Imaging Evaluation

Blood tests and urinalysis along with renal ultrasonography findings are useful in identifying the cause for ATN. In ATN, both kidneys are enlarged (especially anteroposterior dimeter) with prominent medulla and smooth in outline. Contrast-enhanced studies are not recommended in ATN. If intravenous (IV) contrast is inadvertently given, persistent dense nephrogram is seen in neurography which may persist for more than 24 hours. As tubules are filled with cellular infiltrates, contrast leaks into the interstitium through the damaged basement membrane, hence, faint or nonopacification of pelvicalyceal system occurs.

Variable appearances of ATN on ultrasonography have been proposed by different authors, which are:[26]

- Normal cortical and medullary echogenicity—ischemic ATN.
- Increase in cortical echogenicity with maintained CMD—drug-related ATN.
- Normal cortical echogenicity with echogenic pyramids—associated with precipitation of Tamm-Horsfall protein. Increased RI (>0.7) on Doppler imaging is present in majority of patients with ATN.[27]

Izumi et al.,[28] proved the superior role of Doppler sonography in evaluation as well as follow-up of the ATN subjects in comparison to the prerenal azotemia with the finding of raised RI (>0.75) and obvious reduction of resistive indices in ATN subjects as compared to the subjects with prerenal azotemia.

Bilateral renomegaly with patchy nephrogram is seen on CT scan. Gadolinium-enhanced MRI demonstrates compartmental renal involvement of cortex, inner and outer medulla, and give complementary information about the pathological condition of the kidney. Perfusion abnormalities were also shown in experimentally induced ATN. Blood-oxygen-level-dependent MRI (BOLD MRI) assesses intrarenal oxygen bioavailability which reflects tissue deoxyhemoglobin levels. Ischemia

Table 4: Etiology of acute tubular necrosis (ATN).

Condition	*Underlying mechanisms*	*Direct causes*
Ischemic ATN	Hypovolemic state	Hemorrhage, fluid loss, burns, and fluid sequestration
	Low cardiac output	Cardiac failure and underlying conditions (arrhythmia, myocardial or pericardial diseases)
	Systemic vasodilatation	Sepsis and anaphylaxis
	Disseminated intravascular coagulation	
Nephrotoxic ATN	Exogenous agents	Aminoglycoside-related toxicity, amphotericin B related toxicity, contrast agents (CIN), cyclosporines, sulfa drugs, etc.
	Endogenous agents	Myoglobinuria (rhabdomyolysis) Hemoglobinuria (transfusion reactions) Acute crystal-induced nephropathy Multiple myeloma

(ATN: acute tubular necrosis; CIN: contrast-induced nephropathy)

JAYPEE BROTHERS

and hypoperfusion in ATN results in reduced tissue oxygen bioavailability which is utilized to discriminate between acute rejection and ATN that may follow renal transplantation.[29]

Acute Cortical Necrosis

Acute cortical necrosis (ACN) is a rare form of acute renal failure which is characterized by ischemic necrosis of renal cortex, including renal column of Bertin with sparing of renal medulla, and thin rim of subcapsular cortex. Both kidneys are involved either diffusely or in patchy distribution; in both instances peripheral renal cortex is spared as it is supplied by the preserved capsular vessels.[5]

More than two-thirds of cases are associated with pregnancy and its complications—abruptio placenta, septic abortion, and placenta previa. Other causes include severe trauma with shock, sepsis, transfusion reaction, severe dehydration, burns, peritonitis, and toxins (e.g. snake venom). Although large numbers of conditions are associated with ACN, the pathophysiology unfortunately remains unclear. Ischemia following vasospasm is probably the initiating event which results due to constriction of small intracortical blood vessels. This may follow exposure to toxins, circulating hormones, or neural stimuli.[30]

Diffuse involvement of both the kidneys may result in complete renal failure requiring either dialysis or transplantation for survival, whereas patchy involvement leads to renal insufficiency.

Imaging Features

Imaging findings depend on the stage of illness. In the acute stage, urographic findings are nonspecific. Kidneys are diffusely enlarged with faint opacification of collecting system. For those surviving the early phase, smooth renal shrinkage occurs over several months. Radiographically, distinctive tram-like or egg shell calcification of cortex may be seen which starts appearing as early as 24 days after the onset of disease.

On ultrasonography, enlargement of both kidneys and loss of the normal CMD with a circumferential hypoechoic zone corresponding to the necrotic cortex is seen. Ultrasound is useful for follow-up. Calcification of cortex causes dense cortical echoes with distal acoustic shadowing.

Specific appearance of ACN is described on CECT scan. The three diagnostic features are (a) enhancement of the medulla, (b) nonenhancement of the renal cortex, and (c) lack of excretion of contrast medium into the collecting system. Enhanced subcapsular cortex, the distinctive "Cortical rim sign" on CECT scan suggests the sparing of the most peripheral region of renal cortex **(Figs. 7A and B)**. "Cortical rim sign" is also seen in other conditions which result in hemodynamic derangement like renal infarction, renal vein thrombosis, and ATN.[31-33]

Magnetic resonance imaging also shows these representative findings. Kidneys are enlarged in the early phase. Low signal intensity of the inner renal cortex and the columns of Bertin on every MRI sequence is the major

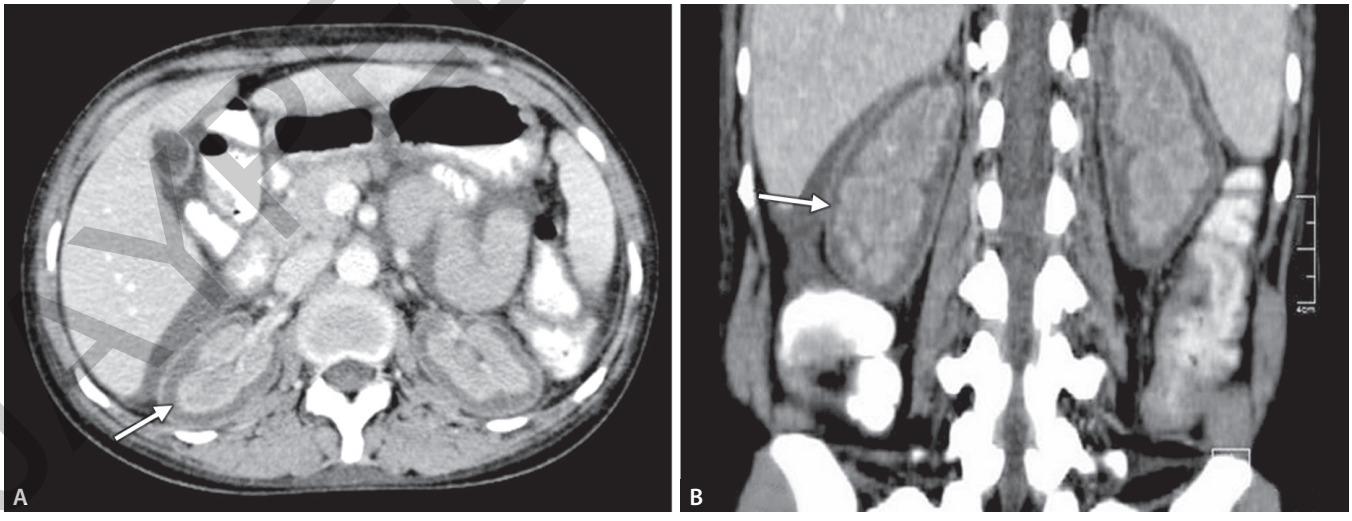

Figs. 7A and B: Acute cortical necrosis in a female patient with septic abortion: Axial and coronal postcontrast computed tomography scans (corticomedullary phase) demonstrate the absence of contrast enhancement in the cortex and relatively hyperdense medulla and subcapsular cortex, the characteristic "cortical rim sign".

JAYPEE BROTHERS

characteristic finding of renal cortical necrosis. Swelling of both kidneys with increased signal intensity of the cortex on T2W images instead of T1W images is another feature of renal cortical necrosis at MRI. Later a thin rim of low signal intensity (T1WI and T2WI) may be seen along the border of kidneys due to calcification.[34]

Leukemia

Leukemia (predominantly lymphocytic leukemia) is the most common malignant cause of bilateral renal enlargement in children. Renal enlargement occurs due to infiltration of kidneys by leukemic cells. Usually, markedly large kidneys are seen, however, sometimes asymmetrical renal involvement or focal renal mass may be seen **(Figs. 8A and B)**.

Imaging Features

In leukemic infiltration of kidney, the nephrogram is faint and the collecting system is attenuated. Pelvicalyceal system is often filled with blood clots or uric acid stones which appear as filling defects.[20]

Acute Interstitial Nephritis

Acute interstitial nephritis (AIN) is an acute hypersensitivity reaction, mediated through immunologic mechanisms. It may result following an exposure to drugs, nonrenal infection (e.g. infectious mononucleosis, legionella, and leptospirosis), systemic autoimmune disorders (SLE, Sjögren's syndrome, and sarcoidosis), and tubulointerstitial nephritis and uveitis (TINU syndrome). However, an idiopathic variety is also described. The most common cause of AIN are drugs particularly—antibiotics (methicillin, penicillin, and amphotericin), Nonsteroidal anti-inflammatory drugs (NSAIDs), sulfonamides, phenytoin, and thiazide.[35]

Fever, skin rashes, eosinophilia, oliguria, and proteinuria are the common clinical signs and symptoms of drug-induced AIN which appear between 5 days and 5 weeks of exposure. Patient recovers with the withdrawal of the causative agent.[36]

Imaging Features

Bilateral renomegaly with diminished to normal opacification of collecting system is seen on urography. Ultrasound shows increased cortical echogenicity with renal enlargement. Enhanced uptake of Gallium citrate in the kidneys on renal scintigraphy is also reported.[35] CT shows low attenuation areas in the cortex and corticomedullary junctions **(Fig. 9)**. Kidneys may become shrunken and irregular as the disease progresses to a chronic course. Calcification of renal papillae may occur in analgesic-induced nephritis. Interstitial fibrosis leads to low signal intensity of renal cortex on T1W MRI.

Amyloidosis

Amyloidosis is a diverse group of diseases that have extracellular deposition and accumulation of an insoluble fibrillar proteinaceous substance with a beta sheath configuration, which is characteristically appreciated as apple green birefringence on congo red staining and when viewed under polarized light.

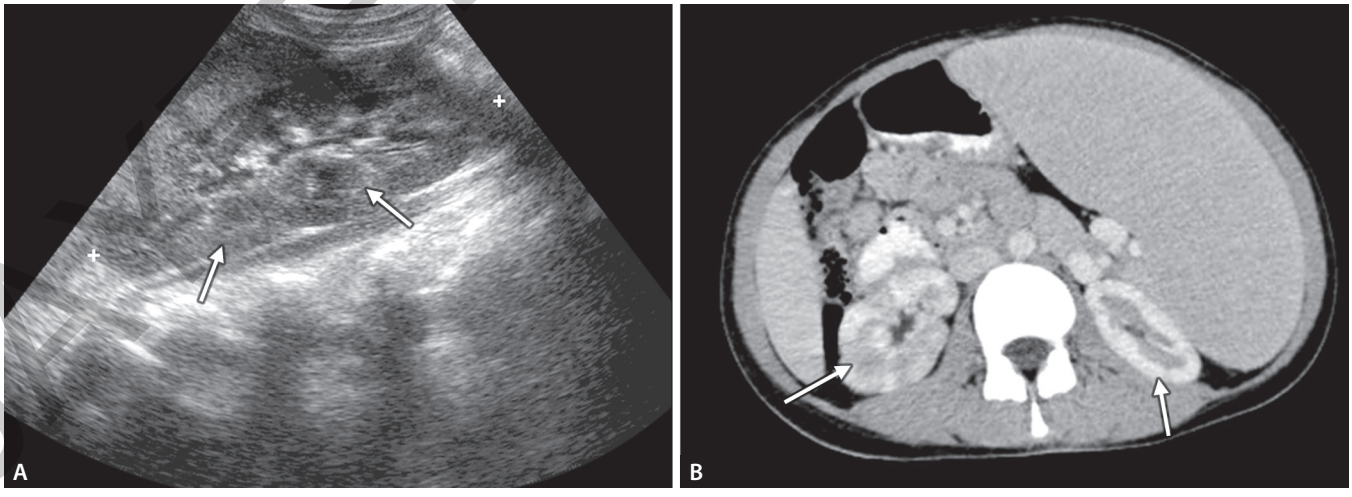

Figs. 8A and B: Renal manifestation of leukemia. (A) Ultrasonography of kidney shows focal, well-defined, and hypoechoic masses; (B) Contrast-enhanced CT axial image in another patient also shows bilateral, multiple, and focal hypodensities suggestive of leukemic deposits. Massive splenomegaly is also seen.

JAYPEE BROTHERS

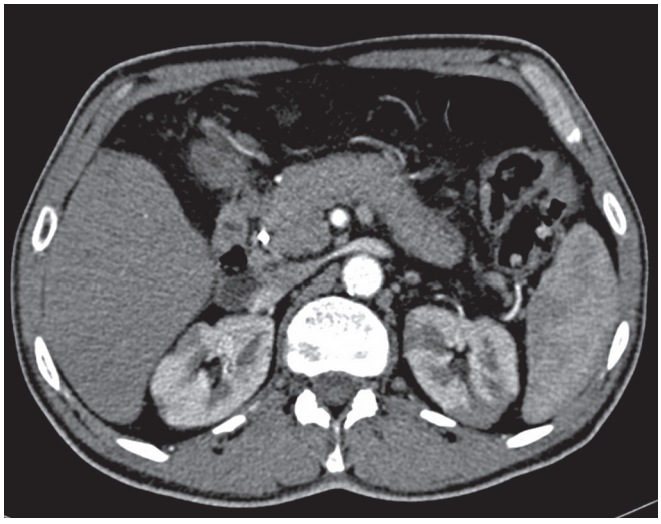

Fig. 9: Acute interstitial nephritis in a case of autoimmune pancreatitis. Multifocal hypodense areas in the cortex of bilateral kidneys.

Amyloidosis can be classified as follows:[37]

- *Primary amyloidosis*: Usually called as primary light chain (AL) amyloidosis resulting from the B-cell or plasma cell dysplasia. Usually involves renal and cardiac organs with poor prognosis. Rarely heavy chain associated amyloidosis is also seen accounting for ~4–6% with no cardiac involvement explaining the good prognosis in affected subjects.
- *Secondary amyloidosis*: Secondary amyloidosis [amyloid-associated disease (AA)] is usually associated with chronic inflammatory conditions such as rheumatoid arthritis, Crohn's disease, tuberculosis, bronchiectasis, and chronic osteomyelitis.

Secondary amyloidosis is more prevalent and more common in underdeveloped countries whereas primary amyloidosis is the most common type of amyloidosis in the Western hemisphere. Other rare familial and senile forms and dialysis-related amyloidosis have also been described.

Older men are more affected than women,[38] usually presenting with nonspecific symptoms like weight loss, fatigue, and weakness. Multiorgan involvement is present in more than 85% of cases. Kidney is affected in 80% patients with secondary amyloidosis and 35–40% patients with primary disease. Isolated involvement of the renal pelvis, ureter bladder, urethra, prostate seminal vesicle, and retroperitoneum can occur.[39]

Imaging Features

Based on the extent of involvement, amyloidosis can also be classified as systemic and localized forms of disease. In acute phase, bilateral renal enlargement is seen. Decrease in size occurs with progression of disease process, smooth outline is, however, maintained. Nephrogram is diminished with variable excretion into normal pelvicalyceal system. Cortical echogenicity is raised as seen in other parenchymal diseases. Rapid deterioration in renal function or sudden onset nephrotic syndrome indicates renal vein thrombosis, a complication of amyloidosis. Thrombosed renal vein is demonstrated on color Doppler, CT scan or MRI. Perinephric soft tissue mass with retroperitoneal and mesenteric extension is seen. CT examination depicts the extent of soft tissue involvement as well as calcification changes resulting from the amyloid proteinaceous material.

Magnetic resonance imaging shows reduced cortical signal intensity on T1W images with subsequent loss of CMD. Bilateral increased delayed uptake of Gallium 67 when other causes of abnormal gallium activity are excluded.[39]

Amyloidosis of renal pelvis-isolated involvement of renal pelvis can occur in amyloidosis. Interesting radiological appearance of calcification or ossification in the amyloid deposits may be seen. These deposits are usually located in the submucosa of the pelvicalyceal system. A lucent band of mucosa separates the IV contrast density from calcification in the pelvis on intravenous urogram (IVU). Other causes for calcification of pelvicalyceal system are tuberculosis, leukoplakia, primary carcinoma of renal pelvis, and renal calculus. Submucosal amyloid deposits appear hypointense on T1W and T2W magnetic resonance images.

Localized forms of amyloidosis are also encountered in the urinary bladder and lower ureter which may mimic chronic granulomatous (tubercular and schistosomiasis) and neoplastic conditions of these organs. It is extremely important to differentiate the systemic form of involvement from the localized variety as therapeutic approaches vary based on the involvement. Biopsy of renal tissue or extra renal tissue, bone marrow biopsy, and urinalysis will aid in establishing and guiding in management of these conditions.

Multiple Myeloma

Multiple myeloma is a plasma cell disorder which originates in the bone marrow and is characterized by involvement of the skeleton at multiple sites. The neoplastic plasma cells produce excess immunoglobulins (Igs) and Bence Jones proteins are characteristically present in the urine. Multiple pathogenic mechanisms contribute to renal injury/failure in multiple myeloma,

JAYPEE BROTHERS

for detailed information on radiology books, visit our website **www.jaypeebrothers.com,** for detailed information on radiology books, visit our w

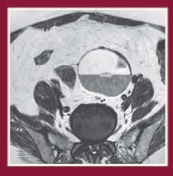

AIIMS-MAMC-PGI IMAGING SERIES

DIAGNOSTIC RADIOLOGY

Genitourinary Imaging

It was the unique vision of the Heads of the Departments of Radiodiagnosis of the three premier institutes of the country, All India Institute of Medical Sciences (AIIMS), Maulana Azad Medical College (MAMC), New Delhi; and Postgraduate Institute of Medical Education and Research (PGIMER), Chandigarh that led to the popular AIIMS-MAMC-PGI Teaching Course Series in the year 1996. The aim was to have a uniform pattern of teaching in Radiology all over the country. The first series of these imaging courses was completed successfully in the year 2000. This was followed by two more series of courses which were completed in the years 2005 and 2013, respectively. The AIIMS-MAMC-PGI imaging course has established itself as one of the best in the country, imparting state-of-the-art medical education and has become immensely popular amongst students. A book compiling all the relevant topics written by the eminent faculty of these three premier institutes has formed an integral part of the courses.

Recent technical advances and novel discoveries make it an exciting but challenging time for imaging. The advances in the field are progressing at a spectacular pace making it essential for radiologists to stay abreast with the latest developments. All this has necessitated a fourth series of these courses and updating of the accompanying book. The present book is devoted to *Genitourinary Imaging* and has 27 chapters. All these chapters have been thoroughly revised, improvised and reorganized. Individual chapters on radiological anatomy and radiological techniques for urinary and genital systems have been added. The latest revisions in management recommendations and guidelines and systematic-algorithmic imaging approaches have been incorporated to simplify reporting in an objective and universal manner.

We hope that this edition will benefit postgraduate students, residents and radiologists from all walks of life.



Anju Garg



Manavjit Singh Sandhu



Arun Kumar Gupta

Available at all medical bookstores
or buy online at www.jaypeebrothers.com



JAYPEE BROTHERS
Medical Publishers (P) Ltd.
www.jaypeebrothers.com

Join us on facebook.com/JaypeeMedicalPublishers

Shelving Recommendation
RADIOLOGY

