.com, for detailed information on cardiology books, visit our website www.jaypeebrothers.com, for detailed information on cardiology books

Get Full Access
with added features at
emedicine360.com

Celebrating 50
Passion, Quality and Innovation in Healthcare Publishing

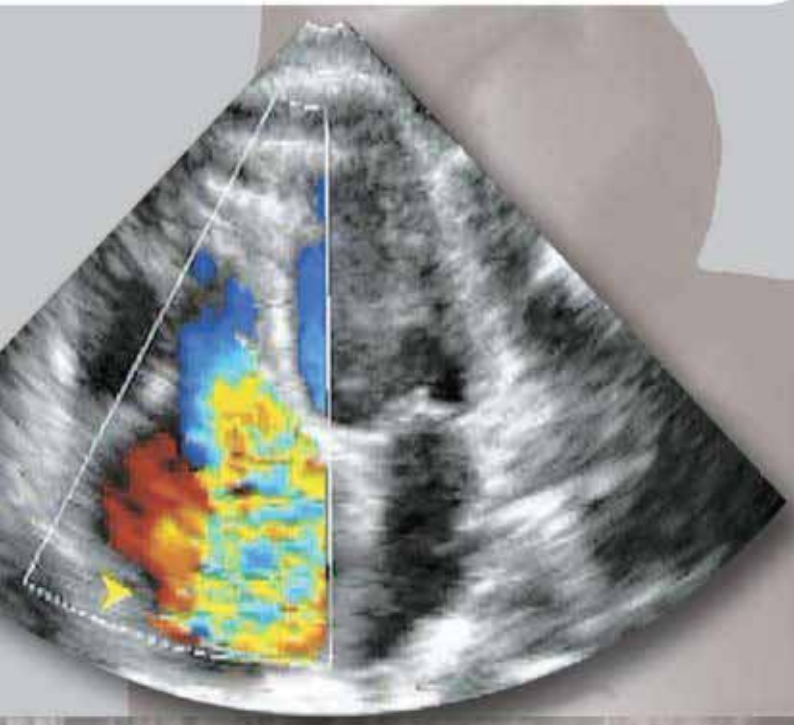

Manual of ECHOCARDIOGRAPHY

Editors
Navin C Nanda
Gültekin Karakuş
Aleks Değirmencioğlu

2nd Edition

JAYPEE

Contents

1. **Basics** 1
   - Artifacts *5*
   - Doppler Echocardiography *8*
   - M-mode Echocardiography *13*
2. **Echocardiographic Examination** 20
   - Indications *43*
   - Contraindications and Precautions *43*
   - Esophageal Intubation *43*
   - Transesophageal Echo Examination *44*
   - Ascending AO, SVC, IVC, Atrial Septum and Pulmonary Veins *45*
   - Tricuspid Valve, RAA and Coronary Sinus *47*
   - Transgastric Examination *47*
   - Aortic Valve, PV, and Coronary Arteries *47*
   - Ascending AO and PA *49*
   - Descending AO *50*
   - Aortic Arch *51*
   - Transpharyngeal Examination *52*
   - Focused Examination *53*
3. **Mitral Valve** 59
   - Mitral Stenosis *59*
   - Mitral Regurgitation *71*
4. **Aortic Valve** 92
   - Aortic Stenosis *92*
   - Aortic Regurgitation *112*
5. **Aortic Diseases** 128
6. **Tricuspid and Pulmonary Valves and Pulmonary Hypertension** 145
7. **Prosthetic Valves** 166
8. **Left and Right Ventricles** 182
   - Left Ventricular Systolic Function *182*
   - Left Ventricular Diastolic Function *196*
   - Right Ventricular Function *212*

JAYPEE BROTHERS

9. Ischemic Heart Disease 215

10. Cardiomyopathies 234

11. Pericardial Disorders 275

12. Cardiac Tumors and Masses 295

13. Congenital Heart Disease 311

- Chamber and Great Vessel Identification *311*
- Shunt Lesions *317*
- Stenotic Lesions *341*
- Complicated Lesions *356*
- Other Lesions *368*

Appendix 373

Index *381*

JAYPEE BROTHERS

CHAPTER 10

Cardiomyopathies

1. How is cardiomyopathy defined?

The World Health Organization (WHO) defined cardiomyopathy as a "disease of the myocardium associated with cardiac dysfunction" in 1995.

In 2006, the American Heart Association scientific statement proposed a more contemporary definition: Cardiomyopathies are a heterogeneous group of diseases of the myocardium associated with mechanical and/or electrical dysfunction that usually (but not invariably) exhibit inappropriate ventricular hypertrophy or dilatation and are due to a variety of causes that frequently are genetic.

In 2008, the European Society of Cardiology's working group on myocardial and pericardial diseases presented an update to the WHO/ISFC classification in which cardiomyopathy was defined as follows: "A myocardial disorder in which the heart muscle is structurally and functionally abnormal in the absence of coronary artery disease (CAD), hypertension, valvular disease, and congenital heart disease sufficient to explain the observed myocardial abnormality".

In summary, the definition and classification of cardiomyopathies continue to evolve with better understanding of the diverse disease states of the myocardium.

2. How are cardiomyopathies classified?

Cardiomyopathies are categorized into two groups:

- Primary cardiomyopathies (predominantly involving the heart)
  - Genetic
    - Hypertrophic
    - Arrhythmogenic right ventricular cardiomyopathy/dysplasia (ARVC/D)
    - Left ventricular noncompaction (LVNC)
    - PRKAG2 and Danon glycogen storage diseases
    - Conduction defects, mitochondrial myopathies, and ion channel disorders.
  - Mixed
    - Dilated
    - Restrictive.
  - Acquired
    - Myocarditis

JAYPEE BROTHERS

  - Stress-induced (Takotsubo)
  - Peripartum
  - Tachycardia-induced
  - Infants of insulin-dependent diabetic mothers.
- Secondary cardiomyopathies (accompanied by other organ system involvement).

3. What is the cut-off value of left ventricular (LV) wall thickness for hypertrophic cardiomyopathy (HCM)?

Hypertrophic cardiomyopathy may be considered when wall thickness is ≥ 15 mm in the absence of any other known cause of hypertrophy [e.g. hypertension, aortic stenosis (AS)].

4. What are the classical features of HCM?

The classical features are hypertrophy of LV walls including in many cases asymmetric hypertrophy of the ventricular septum (VS) as compared to LV inferolateral wall with a ratio of 1.5 or more. The LV outflow tract (LVOT) is narrowed to < 20 mm. This is best measured at the onset of mitral valve (MV) closure as the narrowest distance between the VS and the MV. Systolic anterior movement (SAM) of the anterior MV leaflet is seen. This typically begins during LV ejection sometime after MV closure and reverts to baseline before the next MV opening motion. Systolic anterior movement is considered produced by a Venturi suction phenomenon or more likely a "dragging" phenomenon resulting from the force of LV ejection. The anterior MV leaflet in HCM is generally elongated and this also facilitates the production of SAM. Not only the anterior MV leaflet but also the chordae apparatus can be noted protruding into the LVOT during systole. Systolic anterior movement together with a narrow LVOT may result in a pressure gradient and obstruction of the LVOT. The velocity waveform has a slow initial slope and a rapid deceleration mimicking the shape of a Turkish dagger. This and its onset with LV ejection [generally after the QRS complex of the electrocardiogram (ECG)] differentiate it from mitral regurgitation (MR) that may coexist with HCM. The MR velocity waveform begins as soon as the MV closes (generally just before or within the QRS complex of the ECG) and is more rounded in shape. Mitral regurgitation may also result from SAM and in this case, MR onset will be later as it will then coincide with the development of SAM and is directed posteriorly. Significant obstruction is more likely if the SAM is large and is in contact with the VS for a longer duration. By three-dimensional (3D) echo the medial rather than the lateral portion of the anterior MV leaflet produces contact with the VS. In a patient with no LVOT obstruction at rest, obstruction may be induced by the Valsalva maneuver, administration of sublingual nitroglycerine, exercise or Dobutamine administration. A high gradient may also be seen in the beat following a premature ventricular contraction.

JAYPEE BROTHERS

Another important feature of HCM is LV diastolic dysfunction (DD) and the patient's symptoms are sometimes related more to this than LVOT obstruction. In HCM, RV hypertrophy (RVH) may also occur and the patient may present with RV outflow tract (RVOT) obstruction. I remember a teenager who presented with the clinical diagnosis of PS but on echo the PV was normal and she had HCM with severe RVH and a high gradient across the RVOT clinically mimicking severe PS.

5. What are SAM mimics? What are the other causes of SAM?

Redundant MV chordae or even normal chordae on M-mode may mimic SAM. However, they will not have the typical features of SAM described previously with the onset sometime after MV closure and reversion to baseline before the next MV opening. On the M-mode, chordae may be seen going "through" the MV and this finding differentiates them from true SAMs. Redundant MV chordae are easily visualized and identified on two-dimensional (2D) echo. Atypical SAMs may, however, occur in HCM.

Systolic anterior movements of the MV can potentially develop and cause LVOT obstruction in patients without HCM if the LV is small and markedly hypercontractile, e.g. following Dobutamine administration. Systolic anterior movements have also been noticed with severe aortic regurgitation (AR) but they do not produce obstruction as the LV is generally large in these patients. Systolic anterior movements may also be observed in dextrotransposition of the great vessels when the LVOT is narrow.

6. What are the other types of HCM?

In some patients, HCM manifests as LV mid-ventricular or apical hypertrophy and obstruction. These variants may or may not be associated with proximal hypertrophy/obstruction. In mid-ventricular type, hypertrophy of the mid portions of VS and anterolateral wall is noted with LV mid-cavity obliteration in systole. High gradients may be noted using continuous wave (CW) Doppler. Mid-LV cavity obliteration and obstruction produced by isolated papillary muscle hypertrophy has also been described. In the apical variety, the LV apex is markedly hypertrophied with a small channel that may be visualized by color Doppler or more effectively by contrast echocardiography. Because of the homogenous nature of apical hypertrophy in some patients, the LV apex may appear normal or even hypokinetic and the diagnosis is often missed unless contrast echocardiography is performed. An abnormal ECG with extensive deep T wave inversions with no history of myocardial infarction in the past should alert one to these HCM variants. Both these variants may be associated with an apical aneurysm that can be missed unless the apex is fully examined using multiple transducer angulations. Continuous wave Doppler may show high gradients not only in systole but also

JAYPEE BROTHERS

paradoxically in diastole with flow signals moving from the aneurysm or hypertrophied area into the basal LV. Another variant of HCM occurs in infants born of poorly controlled diabetic mothers. They may present with concentric or asymmetric LV hypertrophy (LVH) with LVOT obstruction or isolated right ventricular (RV) hypertrophy. Although it is fatal in some infants, in most of them it is transient in nature and resolves completely in the first 6 months of life (Figs. 10.1A to D, 10.2A to D and 10.2A and B).

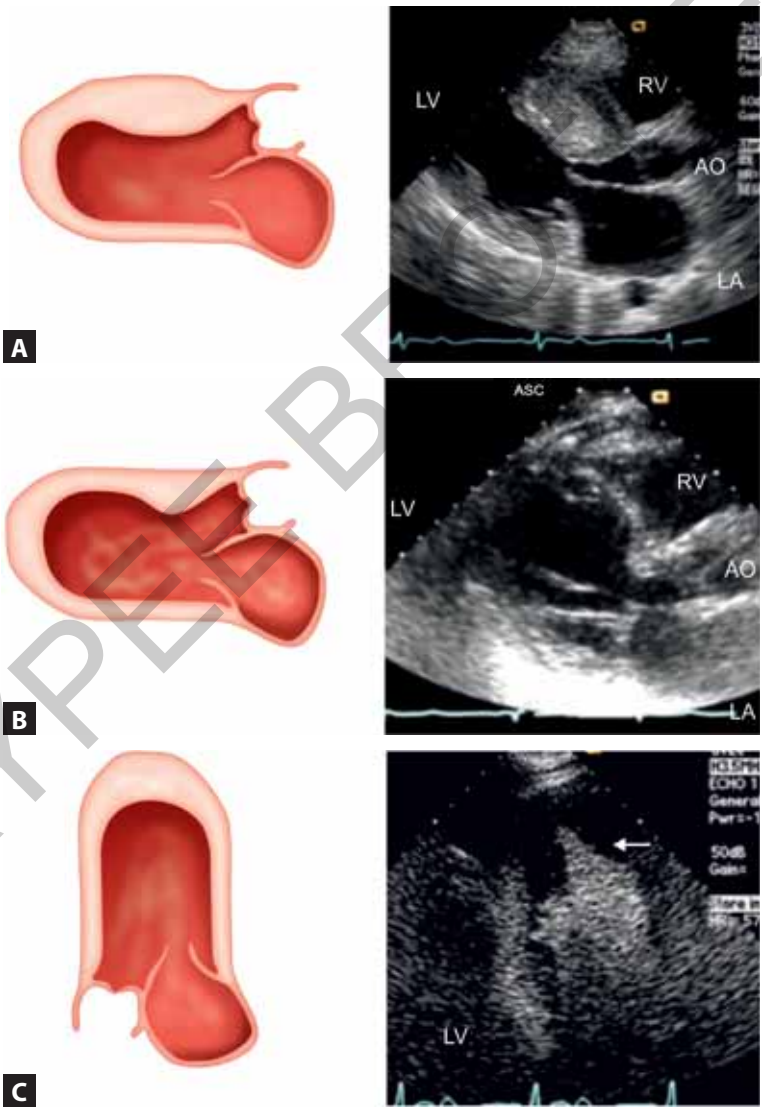

Figs. 10.1A to C

JAYPEE BROTHERS

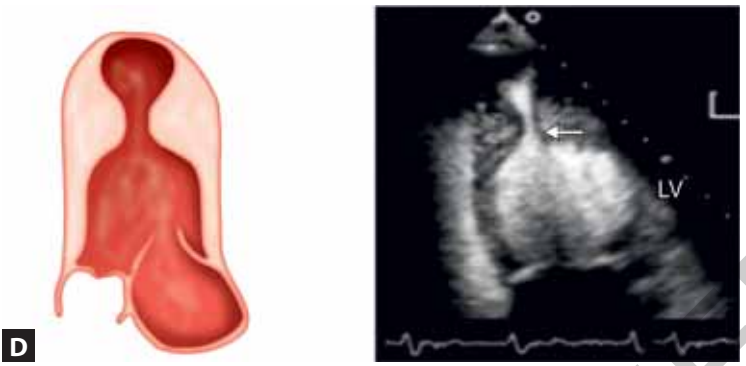

Figs. 10.1A to D: Major patterns of hypertrophy in hypertrophic cardiomyopathy (HCM). Schematic (left panel) versus echocardiographic images (right panel). (A) Anterior septal hypertrophy; (B) Subaortic septal bulge; (C) Apical; (D) Mid–left ventricular with obstruction. Arrow in C and D point to LV cavity narrowing due to hypertrophy. (AO: Aorta, LV: Left ventricle LA: Left atrium; RV: Right ventricle).
Source: Reproduced in part with permission from Shah A et al. Severe symptoms in mid and apical hypertrophic cardiomyopathy. Echocardiography. 2009;26:922–33.

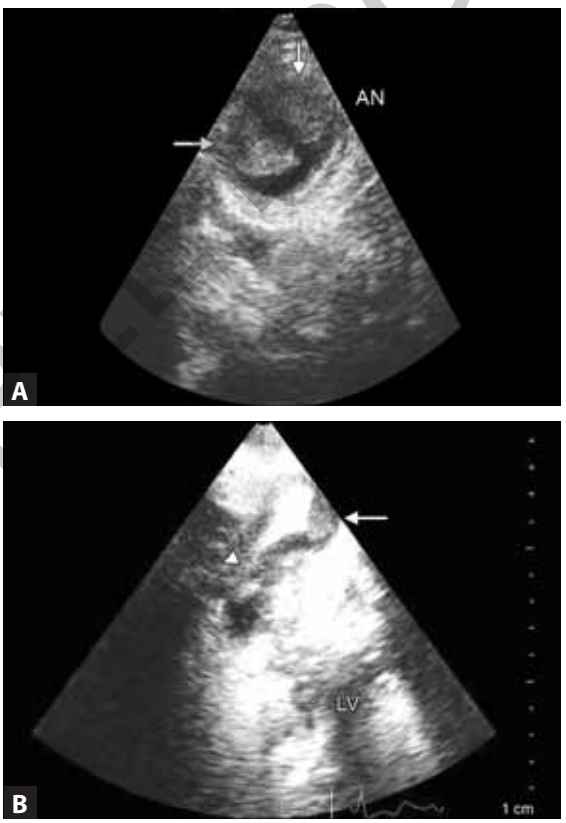

Figs. 10.2A and B

Contd...

JAYPEE BROTHERS

Contd...

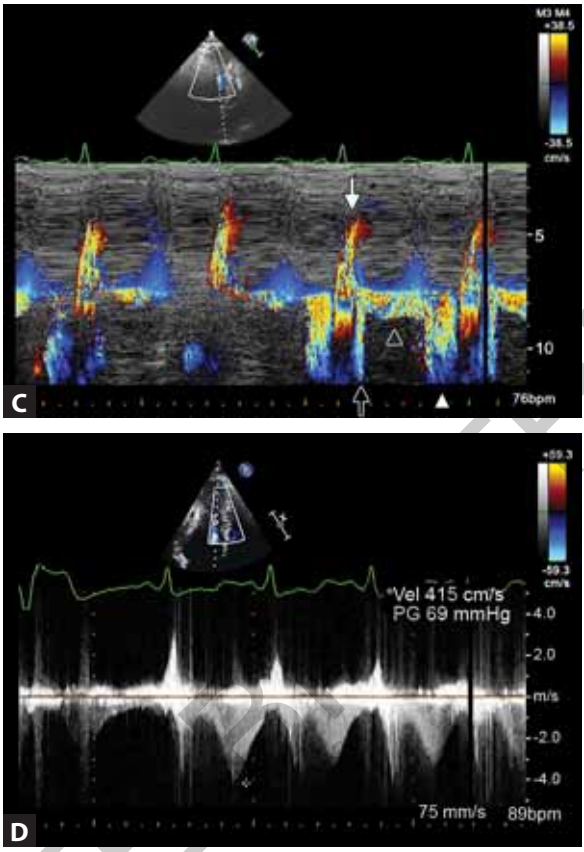

Figs. 10.2A to D: Two-dimensional transthoracic echocardiography in hypertrophic cardiomyopathy with mid-left ventricular obstruction and apical aneurysm. (A) Arrows point to what appear to be two thrombi in the apical aneurysm (AN). (B) Use of an echo contrast agent outlines the AN and a thrombus (arrows). Arrowhead shows the narrow channel. (C and D) Color M-mode and continuous wave Doppler examination. Shows flow signals moving into the AN in late diastole (arrow), then into the left ventricular cavity (LV) with high velocity (hollow arrow) in early systole. Thereafter, the velocity markedly decreases in mid and late systole (hollow arrowhead). Finally, high velocity signals are seen moving from the AN into the LV during diastole (arrowhead).

Source: Reproduced with permission from Thind M, Joson M, Gaba S, et al. Incremental value of live/real time three-dimensional transthoracic echocardiography over two-dimensional echocardiography in hypertrophic cardiomyopathy with mid-ventricular obstruction and apical aneurysm. Echocardiography. 2015;32:565–9. Fig. 1A to D and 1A, 1B Part 1 and 1B Part 2).

JAYPEE BROTHERS

7. What are the other etiologies that predispose to LVH; can they coexist with HCM?

The most common etiology of LV wall thickening is chronic hypertension but others include aortic valve stenosis (AS), discrete subaortic membranous stenosis, athlete's heart, LVNC (pseudo-HCM), amyloidosis, Anderson–Fabry disease (FD) and Friedreich's ataxia. Hypertrophic cardiomyopathy can coexist with AS and discrete subaortic stenosis. A narrow LVOT in a patient with AS should alert one to the possible presence of associated HCM. Systolic anterior movements can be absent because the more distal obstruction at the valve level will prevent a Venturi suction or drag effect. This association has important surgical implications because myectomy can be performed at the time of aortic valve (AV) replacement. Occasionally, coexisting HCM is missed and a full blown scenario of HCM develops after AV replacement with SAMs and a high pressure gradient across the LVOT. This is because the distal obstruction at the AV level has now been removed. Performing a VS myectomy at this stage becomes technically challenging because the replaced AV needs to be unseated first to obtain access to the VS through the aortotomy. Some of these patients without high gradients can be managed conservatively with adequate hydration and beta blockers both of which would tend to enlarge the LV and reduce or abolish SAMs.

A markedly thickened VS may also result in RVOT obstruction and the patient may present with an erroneous clinical diagnosis of infundibular or pulmonary valve (PV) stenosis.

8. Which conditions can mimic HCM?

- VS thickening secondary to RV hypertrophy [e.g. from pulmonary hypertension (PH)].
- Prominent RV papillary muscle/trabeculations adjacent to the VS.
- Thinning of the LV inferolateral wall due to myocardial infarction in the presence of baseline LVH.

9. How is HCM differentiated from systemic hypertension and athlete's heart?

Table 10.1: Differentiation of HCM from systemic hypertension and athlete's heart.

	HCM	Hypertension	Athlete's heart
Thickness (cm)	Generally > 1.5	Generally < 1.5	Generally < 1.3
Relative wall thickness	Increased	Mildly increased	Normal
Left ventricle (LV) dimensions	Decreased	Normal	Increased
Diastolic function	Abnormal	Abnormal	Normal
Asymmetry	Generally present	Absent	Absent
Left ventricle outflow tract gradient	Generally present	Absent	Absent
Deconditioning (exercise stopped for 6 weeks)	No effect	No effect	Regression of LV size and thickness
Systolic anterior movement	Generally present	Absent	Absent

JAYPEE BROTHERS

10. What is dilated cardiomyopathy (DCM) and what are the echo features?

Dilated cardiomyopathy is a progressive disease of heart muscle that is characterized by decreased cardiac output and LV contractility with significantly enlarged LV dimensions in the absence of CAD, hypertension, valvular disease, and congenital heart disease sufficient to explain the observed myocardial abnormality. Both end-diastolic and end-systolic volumes of LV are increased (according to the American Society of Echocardiography guidelines, the normal reference range for LV diastolic dimension for women is 3.9–5.3 cm and for men is 4.2–5.9 cm. When indexed to body surface area, the normal range would be 2.4–3.2 cm/m^2 for women and 2.2–3.1 cm/m^2 for men). In the continuum of disease, the resultant LV DD and functional MR cause left atrial (LA) enlargement (reference range of LA is 2.7–3.9 cm). Right ventricle contractility can be primarily affected by the etiology of the cardiomyopathy or can result from progression of LV failure and subsequent PH. In patients with DCM, wall thickness is variable, but is typically within normal limits. The LV mass though, is uniformly increased. M-mode echo reveals increased E-point septal separation (EPSS) in a patient with DCM due to a reduced stroke volume with poor systolic function and LV enlargement. A normal EPSS should generally be <1 cm (Figs. 10.3A to D and 10.3A to C).

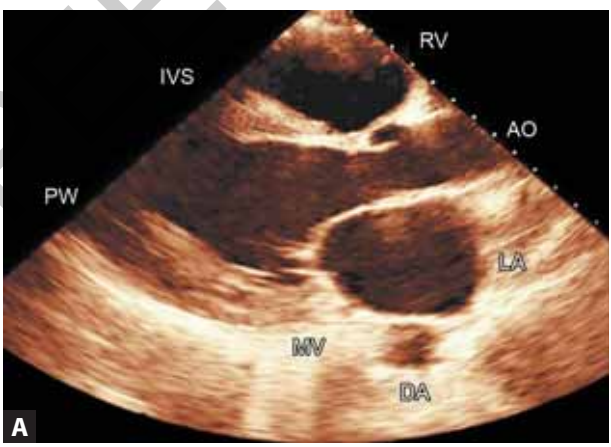

Fig. 10.3A

Contd...

JAYPEE BROTHERS

Contd...

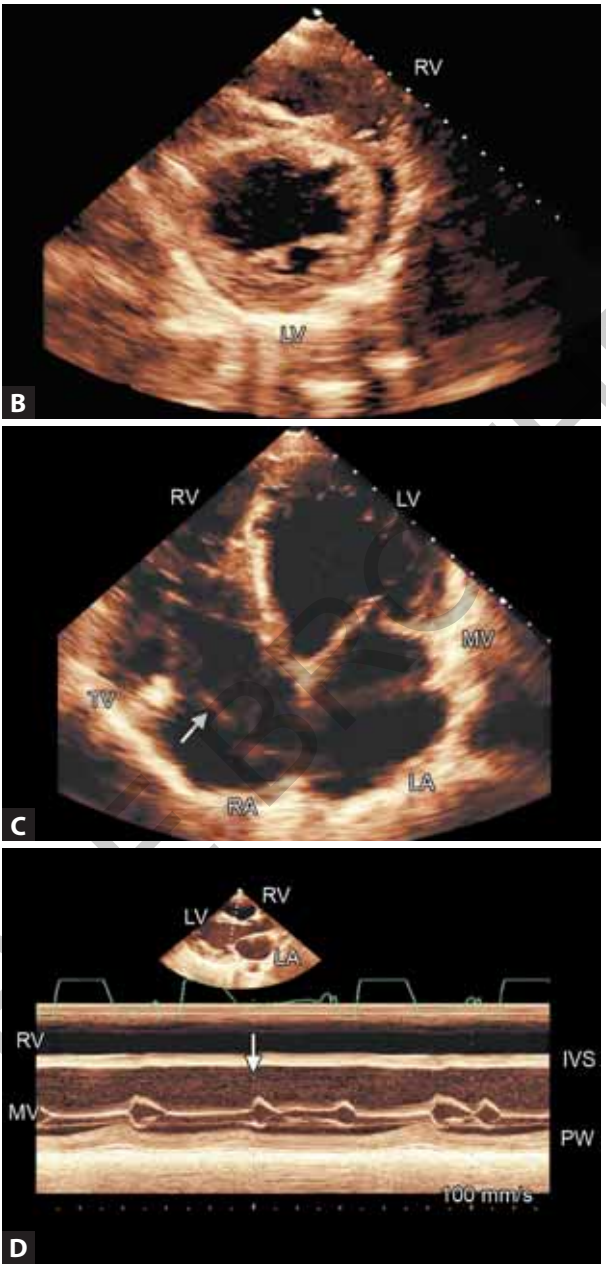

Figs. 10.3A to D: Dilated cardiomyopathy: Two-dimensional transthoracic echocardiography. Parasternal long-axis (A), parasternal short-axis (B), and apical four-chamber (C) views showing marked global left ventricular (LV) hypokinesis. Arrow points to a catheter in the right heart. The echogenic tricuspid valve (TV) annulus probably represents fatty infiltration; (D) M-mode also showing poor LV function with increased mitral E point (arrow in D) to interventricular septum separation. (AO: Aorta; DA: Descending thoracic aorta; IVS: Interventricular septum; LA: Left atrium; MV: Mitral valve; PW: Posterior (inferolateral) wall; RV: Right ventricle; RA: Right atrium).

JAYPEE BROTHERS

11. What are the features that distinguish ischemic cardiomyopathy (ICMP) from nonischemic dilated cardiomyopathy (NICMP)?

It is important to distinguish ICMP from NICMP as management and prognosis may be different. Patients with ICMP may benefit from a revascularization treatment strategy. Furthermore, patients with ICMP have a worse prognosis than NICMP patients. Basically, prominent regional wall motion abnormalities (WMA) in the distribution of coronary blood supply with normal or near normal RV function characterize ICMP. In NICMP, however, both LV and RV tend to be globally hypokinetic and any regional WMA are less prominent and may not necessarily correspond to specific coronary artery distribution. Wall motion abnormalities in NICMP are considered related to microvascular disease since epicardial vessels are normal on the coronary angiogram. Right ventricle apex may be hypokinetic in ICMP when the left anterior descending (LAD) is involved since the LAD supplies both LV and RV apices. Right ventricle infarction may also result in poor RV function in ICMP. Mitral regurgitation is often associated in both varieties and results from displacement of the MV coaptation region into the LV due to stretching and displacement of the papillary muscles and chordae produced by an enlarged and poorly functioning LV. Reduction of MV coapting surfaces in systole results in MR that may be severe. The tenting produced by displacement of the MV coaptation region can be assessed by 2D echo and various tenting parameters as well as the size and area of the mitral annulus have been used to decide which patients will benefit from which type of surgical repair. However, consensus regarding their use is lacking. In ICMP, the MV coaptation point tends to be directed eccentrically as compared to NICMP where it is usually directed centrally. A small kink in the anterior MV leaflet in systole resulting from tethering by a strut chord may produce a "sea gull" appearance in ICMP. Differentiation between ICMP and NICMP is not always easy, but Table 10.2 shows several echo and other parameters that could be helpful (Figs. 10.4A to G and 10.4A to H)

Table 10.2: Comparison of noninvasive findings in ischemic cardiomyopathy and nonischemic dilated cardiomyopathy.

Modality	ICM with Dilated LV	NICM with Dilated LV
Clinical evaluation	• Older patients • History of ischemic heart disease such as angina and myocardial infarction	• May be younger • May not have history of ischemic heart disease • May have history of viral infections, septicemia, alcoholism, metabolic, or infiltrative diseases
Echocardiography	• Segmental WMA/thinning (<6 mm in end-diastole) in coronary artery distribution. Sensitivity 65% to 81%, and specificity 56% to 99%	• Less common. Defects when present may not relate to coronary artery distribution

Contd...

JAYPEE BROTHERS

Contd...

Table 10.2: Comparison of noninvasive findings in ischemic cardiomyopathy and nonischemic dilated cardiomyopathy.

Modality	ICM with Dilated LV	NICM with Dilated LV
	• Endocardial brightening/scarring more common due to infarction	• Less common
	• Biphasic response with dobutamine stress test indicative of hibernating viable myocardium is more common	• Less common
	• Perfusion defects with contrast echo more common	• Less common
	• 2D TTE/Doppler may show stenosis in proximal or other coronary arteries, which may be small	• Coronary arteries may show no stenosis, may be larger
	• Spherical LV less common	• Spherical LV more common
	• May show prominent plaques in larger vessels such as ascending aorta, arch, and abdominal aorta.	• May be normal
	• Asymmetric closure of mitral valve leaflets with eccentric regurgitation jet(s) more common. "Seagull" sign may be present	• Symmetric closure with central jets more common. "Seagull" sign absent
	• LV dilatation less severe	• Severe spherical LV dilatation with malcoaptation of mitral valve leaflets
	• Right ventricle usually not enlarged and function normal except when RCA is stenotic/occluded or RV infarction present	• RV enlargement and/or dysfunction more frequent
Single-photon emission computed tomography (SPECT)	• Perfusion defects in coronary artery distribution. More accurate if combined with WMA	• Perfusion defects less common and if present do not relate to coronary artery distribution
	• Normal sized RV with good function more common	• Large RV with reduced function more common
Coronary computed tomographic angiogram (CCTA)	• Coronary artery calcification more common. Coronary stenosis, both obstructive and nonobstructive may be identified	• Less common
Cardiac magnetic resonance (CMR)	• Increased gadolinium uptake or enhancement indicating scar formation in the previously infarcted areas more common	• Less common
	• Regional WMA/thinning and perfusion defects similar to echocardiography above	• Regional WMA/thinning and perfusion defects similar to echocardiography above
Positron emission tomography (PET)	• Large mismatch defects more common	• Less common

(2D TTE: Two-dimensional transthoracic echocardiography; ICM: Ischemic cardiomyopathy; LV: Left ventricle; NICM: Nonischemic cardiomyopathy; RV: Right ventricle; WMAs: Wall motion abnormalities).

JAYPEE BROTHERS

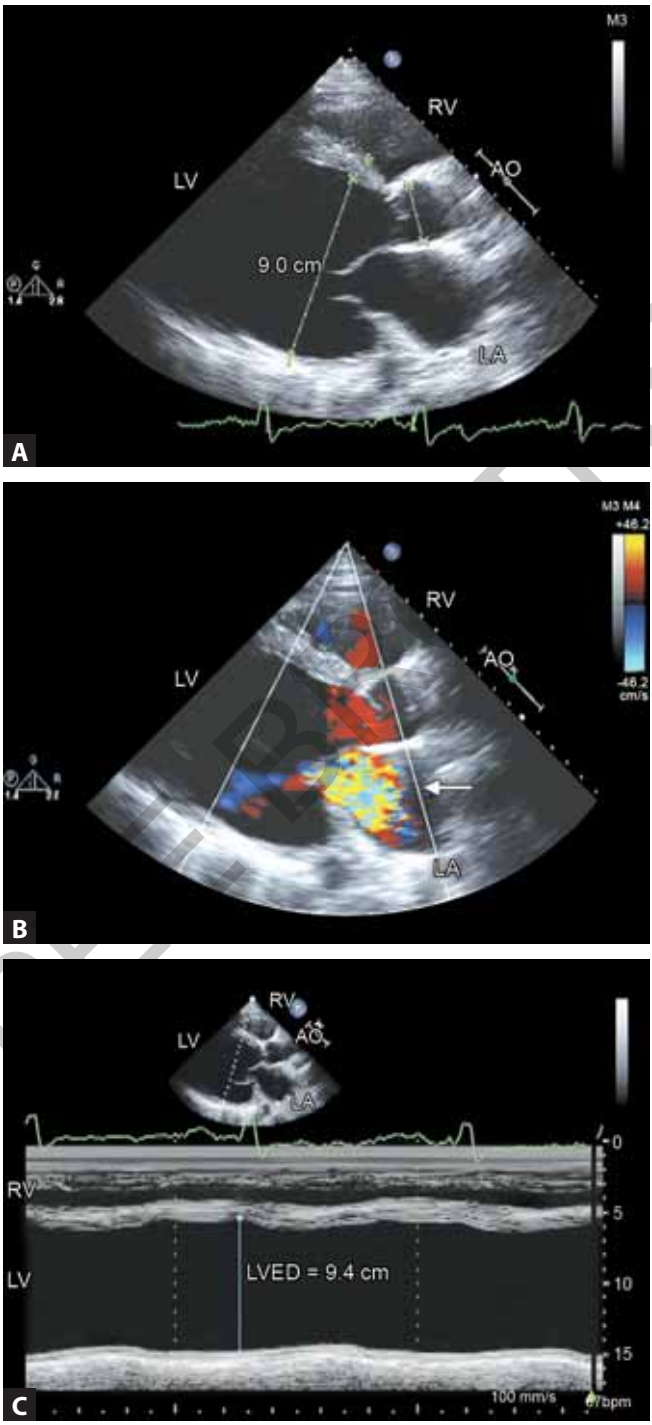

Figs. 10.4A to C

Contd...

JAYPEE BROTHERS

Contd...

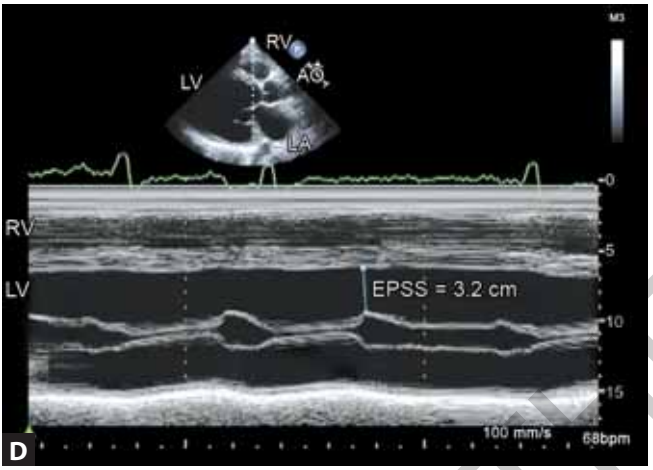





Figs. 10.4D to F

Contd...

JAYPEE BROTHERS

Contd...

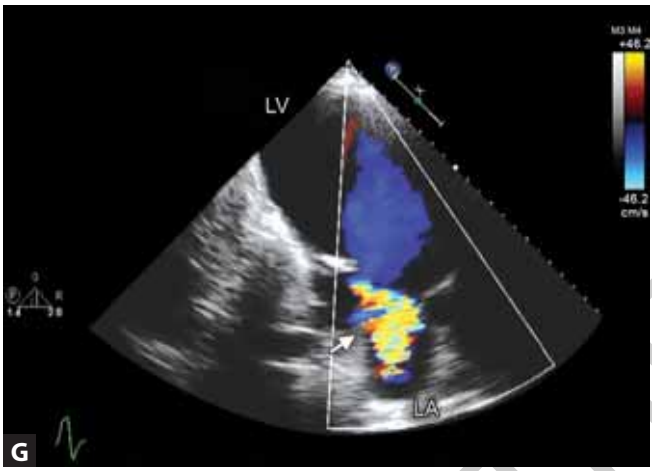

Figs. 10.4A to G: Ischemic cardiomyopathy in a 38-year-old female patient. M-mode/two-dimensional transthoracic echocardiography. (A and B) Parasternal long-axis views demonstrating a huge left ventricle (LV) measuring 90 mm and severe mitral regurgitation (arrow); (C and D) M-mode examination showing a very large LV with severely reduced function. Also note markedly increased E-point septal separation (EPSS) measuring 32 mm in D; (E to G) Apical views; (E) The coaptation point (arrow) of the mitral leaflets is displaced into the LV and directed eccentrically toward the LV free wall, suggesting ischemic origin of cardiomyopathy; (F) Shows dyskinesis (arrow) of the distal LV inferior wall and septum; (G) Severe mitral regurgitation (arrow) resulting from reduced coaptation of the displaced mitral leaflets. (AO: Aorta; LA: Left atrium; RA: Right atrium; RV: Right ventricle).

12. How is restrictive cardiomyopathy (RCM) defined?

Restrictive cardiomyopthy is a disease of myocardium in which diastolic function is primarily affected in the absence of pericardial diseases and the diseases that cause afterload increase (e.g. AS, hypertension).

13. What are the general echocardiographic features of RCM?

- Nondilated ventricles (left ventricular end-diastolic volume < 40 mL/m^2)
- Mildly increased (depends on etiology) LV wall thickness.
- LV DD with restrictive filling pattern [increased *E/A* ratio (> 2), decreased deceleration time (DT < 160 ms), decreased mitral septal annular velocity (< 7 cm/s), decreased mitral propagation velocity (< 50 cm/s)]
- Increased hepatic vein reverse flow with inspiration
- Biatrial enlargement

JAYPEE BROTHERS

for detailed information on cardiology books, visit our website www.jaypeebrothers.com, for detailed information on cardiology books, visit our web

Manual of
ECHOCARDIOGRAPHY

Manual of Echocardiography is a practical manual which will be useful to all those who utilize echocardiography in their day-to-day clinical practice. This manual is expected to serve the needs of both physician and technologist echocardiographers as well as those who are still in training. The manual consists of 13 chapters and an appendix containing useful tables. To facilitate easy reading and understanding, the contents of all chapters are in the form of questions and answers and these are supplemented in some cases by brief case studies. The chapters incorporate the basics of echocardiography, transthoracic, transesophageal, and three-dimensional echocardiography, delineate all aspects of mitral, aortic, tricuspid, and pulmonary valve disease entities as well as pulmonary hypertension. The contents of this manual have been mainly abstracted from the Comprehensive Textbook of Echocardiography published by the same publisher and thus the Manual of Echocardiography will represent a useful and practical companion to the large textbook.

Navin C Nanda MD DSc (Hon) DSc (Med) (Honoris Causa) FACC FAHA FASE FSCU (D) FSGC FICA FACA FICP (Hon) FIAE FICMU (Hon) FACIP FCSC (S) FIACS FICC (Hon) is a Distinguished Professor of Medicine and Cardiovascular Disease at the University of Alabama at Birmingham, Alabama, USA. He is an internationally renowned cardiologist who has done pioneering work in echocardiography. He with his group was the first to discover the pulmonary valve by echocardiography, diagnose a bicuspid aortic valve, invent treadmill exercise echocardiography, and introduce color Doppler in the USA. He introduced fetal color Doppler, pioneered the clinical use of live/real time three-dimensional transesophageal echocardiography, and was the first to demonstrate the usefulness of echocardiography in cardiac pacing and electrophysiology. His contributions "have changed the way cardiology is practiced in the world today" and he has been honored as the "Father of Echocardiography" and "Father of Modern Echocardiography" by many prestigious organizations.

Some of the accolades he has received include the prestigious Ellis Island Medal of Honor, the American College of Cardiology's International Service Award for "enhancing cardiovascular care throughout the world", first recipient of the Tufts University (Boston) award in echocardiography, the Andreas Gruntzig Award from the Swiss Society of Cardiology, "Prince of Echocardiography of the Heart and Great Vessels" by the Italian Society of Echocardiography, "Citizen of Rome" designation by the Mayor of Rome, Special Award by the Government of Egypt, Lifetime Achievement Award by the Government of India, and "the world's best and most respected echocardiographer" designation by the Chinese Society of Ultrasound. He is also the recipient of Lifetime Achievement Award by the American Society of Echocardiography and this year, he was honored as an icon of the century in cardiology and echocardiography by the Health Minister of India.

Gültekin Karakuş MD DM is an Associate Professor of Cardiology at Mehmet Ali Aydinlar Acibadem University School of Medicine in Istanbul, Turkey. He graduated from Marmara University School of Medicine in 2004 and completed his cardiology residency/fellowship in Siyami Ersek Thoracic and Cardiovascular Surgery Center, Istanbul, Turkey in 2010. He trained in 3D Echocardiography under Dr Navin C Nanda at the University of Alabama at Birmingham, Alabama, USA and also in cardiac magnetic resonance imaging at the University of Vienna, Vienna Austria. He has an extensive experience in the field of cardiovascular imaging and has over 40 scientific national and international publications.

Aleks Değirmencioğlu MD DM is an Associate Professor of Cardiology at Mehmet Ali Aydinlar Acibadem University School of Medicine in Istanbul, Turkey. He graduated from Istanbul University, Istanbul Medical Faculty with Honors in 2003. He ranked sixth in the examination for specialty of medicine in Turkey and started his cardiology residency in Siyami Ersek Thoracic and Cardiovascular Surgery Center, Istanbul, Turkey from where he graduated in 2008 as a cardiology fellow. He has an extensive experience in echocardiography and also interventional cardiology. He translated two books on echocardiography and cardiology to Turkish language and has over 40 scientific national and international publications to his credit.

Available at all medical bookstores
or buy online at www.jaypeebrothers.com



JAYPEE BROTHERS
Medical Publishers (P) Ltd.
www.jaypeebrothers.com

Join us on facebook.com/JaypeeMedicalPublishers

Shelving Recommendations
ECHOCARDIOGRAPHY
CARDIOLOGY

ISBN 978-93-89587-96-8

