brothers.com, for detailed information on cardiology books, visit our website www.jaypeebrothers.com, for detailed information on cardiology books

THIRD EDITION

Celebrating 50
Passion, Quality and Innovation in Healthcare Publishing

# Clinical Diagnosis of Congenital Heart Disease



*Editors*
**M Satpathy • BR Mishra**

JAYPEE

# Contents


## Part One: Basics

1. **Basic Embryology of Congenital Heart Diseases** 3
***ML Kulkarni, SN Rahiman***
From Fertilization to Primitive Heart Tube Formation *3*; From Primitive Heart Tube through Looping *4*; From Looping to Wedging *4*; Septation of the Atria *6*; Development of AV Valves *8*; Development of Aortic and Pulmonary Trunks *8*; Development of Aorta and Its Branches *9*

2. **Fetal and Neonatal Circulation** 11
***BR Mishra, AK Samal***
History *11*; Fetal Circulation *11*; Transitional Circulation *12*; Control of Fetal and Transitional Circulation *13*

3. **Bedside Diagnosis and Classification of Congenital Heart Diseases** 15
***IB Vijayalakshmi, M Satpathy***
General and Physical Examination *15*; Clinical Presentation *21*; Cyanosis *22*; Congestive Heart Failure *23* Bedside Approach for Diagnosis and Classification *24*; Classification of Congenital Heart Diseases *25*; Common Congenital Heart *26*; Common Clinical Observation *26*

4. **Electrocardiogram: Clinically Relevant to Congenital Heart Diseases** 27
***ML Kulkarni, M Satpathy***
Electrical Axis Deviation *28*

5. **Radiological Diagnosis of Congenital Heart Diseases** 33
***K Sharada, M Satpathy***
Situs and Cardiac Position *33*; Skeletal Abnormalities *33*; Is the Heart Enlarged? Are the Contours Normal? *34*; Which Chambers are Dilated? *35*; Are the Pulmonary Arterial Markings—Increased, Decreased or Normal? *38*; Pulmonary Edema *41*; Pulmonary Venous Hypertension *41*; Pulmonary Arterial Hypertension *41*

## Part Two: Acyanotic Lesions

6. **Clinical Approach to Diagnosis of Cardiac Malpositions** 45
***BR Mishra, M Behera***
Definition *45*; History *45*; Incidence *45*; Embryology *45*; Situs *46*

7. **Left Ventricular Inflow Obstruction** 55
***B Dalvi, Sumitra Venkatesh, SS Prabhu, BR Mishra***
Obstruction at Mitral Valve Level *55*; Supravalvular mitral Stenosing Ring *58*; Shone's Complex *58*; Dilated Coronary Sinus Causing Left Ventricular Inflow Obstruction *59*; Cor Triatriatum *59*; Congenital Pulmonary Vein Stenosis *61*


JAYPEE BROTHERS

**8. Mitral Valve Prolapse** **63**
***PC Manoria, SK Trivedi, M Satpathy***
The Agony of a Patient *63*; Synonyms *63*; Definition *63*; History *63*; Incidence *64*; Abnormal anatomy *64*; Classifications *64*; Hemodynamics *65*; Clinical Features *65*; Mitral Valve Prolapse Syndrome *67*; Investigations *67*; Diagnosis *69*; Differential Diagnosis *69*; Natural History *69*; Guidelines for Management *70*

**9. Congenital Mitral Regurgitation** **71**
***M Satpathy***
Abnormal Anatomy *71*; Clinical Features *72*; Investigations *72*; Diagnosis *73*; Differential Diagnosis *74*; Guideline for Management *74*

**10. Primary Endocardial Fibroelastosis** **76**
***M Satpathy***
Incidence *76*; Classification *76*; Etiology *76*; Pathology *76*; Hemodynamics *77*; Clinical Features *77*; Signs *77*; Investigations *77*; Diagnosis *77*; Differential Diagnosis *78*; Complication *78*; Prognosis *78*; Guidelines for Management *78*

**11. a. Atrial Septal Defect (Secundum Type)** **79**
***PK Dash, M Satpathy***
Classification *79*; Definition *79*; History *79*; Embryology *79*; Incidence *80*; Types of ASD Secundum *80*; Hemodynamics *80*; Clinical Features *81*; Investigations *83*; Diagnosis *85*; Differential Diagnosis *86*; Complications *86*; Natural History *86*; Guideline for Management *86*; Complicated Atrial Septal Defect *87*

**b. Atrial Septal Defect (Primum Type)** **88**
***Sunita Maheshwari***
Synonyms *88*; Definition *88*; Embryology *88*; Incidence *88*; Hemodynamics *89*; Investigations *89*; Diagnosis *90*; Different Diagnosis *91*; Complications *91*; Natural Course *91*; Guidelines for Management *91*

**c. Atrial Septal Defect (Sinus Venosus Type)** **92**
***Sunita Maheshwari, M Satpathy***
Synonym *92*; Definition *92*; Classifications *92*

**d. Atrial Septal Defect (Coronary Sinus Type)** **94**
***Sunita Maheshwari, M Satpathy***
Guidelines for Management *94*; Guidelines for Management *95*

**12. Atrial Septal Defect with Associated Common Anomalies** **96**
***M Satpathy***
Lutembacher's Syndrome *96*; Partial Anomalous Pulmonary Venous Connection *99*
Guidelines for Management *102*

**13. a. Ventricular Septal Defect** **103**
***PR Gupta, M Satpathy***
Definition *103*; History *103*; Incidence *103*; Embryology *103*; Abnormal Anatomy 104; Classifications *104*; Hemodynamics *105*; Clinical Features *106*; Investigations *107*; Diagnosis *110*; Differential Diagnosis *110*; Complications *111*; Natural History *111*; Prognosis *111*; Guidelines for Management *111*

**b. Ventricular Septal Defect with Aortic Regurgitation** **113**
***BR Mishra***
History *113*; Incidence *113*; Abnormal Anatomy *113*; Hemodynamics *113*; Clinical Features *113*; Signs *114*; Investigations *114*; Diagnosis *114*; Differential Diagnosis *114*; Complications *115*; Natural History *115*; Guidelines for Management *115*

JAYPEE BROTHERS

**c. Ventricular Septal Defect with Pulmonary Stenosis** **116**
***M Satpathy***
Abnormal Anatomy *116*; Clinical Features *116*; Investigations *116*; Diagnosis *117*; Differential Diagnosis *117*; Guidelines for Management *117*

**d. Left Ventricle to Right Atrial Communication** **118**
***M Satpathy***
Synonym *118*; Definition *118*; Classification *118*; History *119*; Incidence *119*; Hemodynamics *119*; Clinical Features *119*; Investigations *119*; Diagnosis *119*; Differential Diagnosis *120*; Guidelines for Management *120*

**14. Patent Ductus Arteriosus** **121**
***M Satpathy, J Jayarajah***
Definition *121*; History *121*; Incidence *121*; Embryology *122*; Abnormal Anatomy *122*; Mechanism of Ductal Closure *122*; Classification of Patent Ductus Arteriosus *123*; Clinical Features *124*; Investigation *125*; Diagnosis *127*; Complications *128*; Lesions Associated with Ductus *129*; Prognosis *129*; Guidelines for Management *129*

**15. Aortopulmonary Window** **131**
***CG Bahuleyan, M Shifas Babu***
Synonyms *131*; Definition *131*; History *131*; Incidence *131*; Embryology *131*; Anatomical Abnormalities *132*; Common Anomalies Associated with Aortopulmonary windows *132*; Classification *132*; Hemodynamics *132*; Clinical Features *132*; Investigations *133*; Diagnosis *134*; Complications *135*; Natural History and Prognosis *135*; Guidelines for Management *135*

**16. Complete Atrioventricular Septal Defect** **136**
***R Juneja, S Shah***
Incidence *136*; Embryology *137*; Pathology *137*; Physiology *141*; Investigations *142*; Diagnosis *145*; Complications *146*; Natural History *146*; Prognosis *146*; Guidelines for Management *146*

**17. a. Congenital Aortic Stenosis** **148**
***S Guha, M Satpathy***
Definition *148*; Valvular Aortic Stenosis *148*; Critical Aortic Stenosis *155*; Differential Diagnosis *155*; Guidelines for Management *156*; Supravalvular Aortic Stenosis *157*; Subvalvular Aortic Stenosis *160*

**b. Congenital Aortic Regurgitation** **163**
***M Satpathy***
Etiology *163*; Abnormal Anatomy *163*; Hemodynamics *163*; Clinical Features *163*; Investigations *164*; Diagnosis *165*; Differential Diagnosis *165*; Guidelines for Management *165*; Aortic Left Ventricular Tunnel *165*; Clinical Features *166*; Investigations *166*; Differential Diagnosis *166*; Guidelines for Management *166*

**18. Coarctation of the Aorta** **167**
***N Sudhayakumar, BSJ Nair, M Satpathy***
Definition *167*; History *167*; Incidence *167*; Embryology *168*; Classification and Types of Coarctation of Aorta *168*; Hemodynamics *169*; Clinical Features *170*; Collaterals in Coarctation *170*; Investigations *172*; Diagnosis *174*; Differential Diagnosis *174*; Complications *174*; Prognosis *175*; Guideline of Management *175*

**19. Aneurysms of Sinuses of Valsalva** **177**
***J Yusuf, HN Mohan Kumar, UA Kaul***
Definition *177*; History *178*; Incidence *178*; Embryology *178*; Etiology *178*; Classifications *178*; Sites of Rupture of Sinus of Valsalva *179*; Pathology *179*; Hemodynamics *179*; Clinical Features *180*; Investigations *180*; Differential Diagnosis *182*; Complications *183*; Natural History and Prognosis *183*; Guidelines for Management 183

JAYPEE BROTHERS

**20. a. Congenital Coronary Artery Anomalies** **185**
***BR Mishra***
Normal Coronary Arteries *185*; Embryology *185*; Anatomy *185*; Classification of Coronary Anomalies *187*; Coronary Anomalies Associated with Specific Congenital Heart Diseases *187*

**b. Congenital Coronary Arterial Fistula** **189**
***CG Bahuleyan, BR Mishra***
History *189*; Incidence *189*; Embryology *189*; Anatomical Abnormalities *190*; Hemodynamic Abnormality *190*; Clinical Features *190*; Investigations *191*; Diagnosis *192*; Differential Diagnosis *193*; Complications *193*; Natural History and Prognosis *193*; Guidelines for Management *193*

**c. Anomalous Left Main Coronary Artery from the Pulmonary Artery** **194**
***Naveen Garg, BR Mishra***
Synonym *194*; Definition *194*; History *194*; Incidence *194*; Embryology *194*; Anatomical Abnormalities *194*; Hemodynamics *194*; Clinical Features *195*; Investigations *195*; Diagnosis *197*; Differential Diagnosis *198*; Complications *198*; Natural History *198*; Guidelines for Management *198*

**21. Aortic Arch Anomalies and Vascular Rings** **199**
***BR Mishra, M Satpathy***
History *199*; Sidedness or Laterality of Aortic Arch *199*; Classifications *199*; Clinical Features *200*; Investigations *200*; Left Aortic Arch *200*; Right Aortic Arch *201*; Double Aortic Arch *203*; Cervical Aortic Arch *203*; Other Rare Aortic Arch Anomalies *204*; Anomalies of Pulmonary Artery *204*; Guidelines for Management *205*

**22. a. Congenital Pulmonary Stenosis** **206**
***N Desai, Sunil Kumar, Arun Srinivas, HP Guruprasad***
Synonyms *206*; Definition *206*; History *206*; Etiology *206*; Embryology *206*; Prevalence *207*; Abnormal Anatomy *207*; Classifications *207*; Hemodynamics *208*; Valvular Pulmonary Stenosis *208*; Complications *213*; Dysplastic Pulmonary Valve *213*; Infundibular Pulmonary Stenosis *213*; Double-Chambered Right Ventricle *213*; Guidelines for Management *215*

**b. Congenital Pulmonary Regurgitation** **217**
***N Desai, Sunil Kumar, Arun Srinivas, HP Guruprasad***
Etiology and Incidence *217*; Incidence *217*; Hemodynamics *218*; Clinical Presentation *218*; Investigations *218*; Complications *219*; Natural History and Prognosis *219*; Guidelines for Management *219*

**c. Idiopathic Dilatation of Pulmonary Trunk** **221**
***BR Mishra***
Definition *221*

**d. Peripheral Pulmonary Artery Stenosis** **223**
***BR Mishra***
Definition *223*; Synonyms *223*; History *223*; Embryology *223*; Incidence *223*; Pathology *224*; Classification of Peripheral Pulmonary Artery Stenosis *224*; Hemodynamics *224*; Clinical Features *224*; Investigations *225*; Guidelines for Management *226*

**23. Congenitally Corrected Transposition of Great Arteries** **227**
***Rohit Manojkumar, BR Mishra***
History *227*; Prevalence *227*; Embryology *228*; Pathophysiology *228*; Associated Defects *228*; Clinical Features *229*; Investigations *229*; Diagnosis *232*; Complications *232*; Natural History *232*; Guidelines for Management *233*

JAYPEE BROTHERS

## Part Three: Cyanotic Lesions


**24. Common Atrium** 237
*M Satpathy*

Synonyms *237*; Definition *237*; Embryology *237*; Incidence *237*; Abnormal Anatomy *237*; Hemodynamics *237*; Clinical Features *238*; Investigations *238*; Cardiac Catheterization and Angiography *239*; Diagnosis *239*; Differential Diagnosis *239*; Guidelines for Management *240*

**25. Tricuspid Atresia** 241
*SR Mittal, M Satpathy*

Definition *241*; History *241*; Incidence *241*; Embryology *241*; Classifications *241*; Pathology *242*; Hemodynamics *243*; Investigations *246*; Differential Diagnosis *248*; Complications *250*; Natural History *250*; Guidelines for Management *250*

**26. Ebstein's Anomaly** 253
*M Satpathy, AK Bhattacharyya*

Definition *253*; History *253*; Incidence *253*; Embryology *253*; Abnormal Anatomy *253*; Classification *254*; Hemodynamics *254*; Clinical Features *255*; Investigations *256*; Diagnosis *259*; Differential Diagnosis *259*; Complications *259*; Natural History and Prognosis *259*; Guidelines for Management *260*; UHL's Anomaly *261*

**27. Pulmonary Atresia with Intact Ventricular Septum** 262
*V Gouthami, BR Mishra*

Definition *262*; History *262*; Incidence *262*; Embryology *262*; Anatomical Abnormalities *263*; Classifications *264*; Pathophysiology *265*; Hemodynamics *265*; Clinical Features *265*; Investigations *266*; Diagnosis *268*; Differential Diagnosis *268*; Complications *269*; Natural History and Prognosis *269*; Guidelines for Management *269*

**28. a. Tetralogy of Fallot** 270
*M Satpathy, PK Pati*

Definition *270*; History *270*; Prevalence *270*; Genetic Factor *271*; Embryology *271*; Abnormal Anatomy *271*; Other Abnormal Anatomical Features *272*; Hemodynamics *272*; Clinical Features *273*; Investigations *276*; Diagnosis *278*; Guidelines for Management *279*

**b. Absent Pulmonary Valve Syndrome** 281
*BR Mishra*

History *281*; Incidence *281*; Embryology *281*; Associated Lesion *281*; Abnormal Anatomy *281*; Clinical Features *281*; Investigations *282*; Diagnosis *282*; Differential Diagnosis *282*; Natural History *282*; Guidelines for Management *283*

**c. Pulmonary Stenosis with Interatrial Septal Defect** 284
*M Satpathy*

Hemodynamics *284*; Clinical Features *284*; Investigations *285*; Differential Diagnosis *287*; Guidelines for Management *287*

**29. Pulmonary Atresia with Ventricular Septal Defect** 288
*V Gouthami, M Satpathy*

Prevalence *288*; Embryology *288*; Abnormal Anatomy *289*; Classifications *290*; Pathophysiology *291*; Clinical Features *291*; Investigations *291*; Diagnosis *293*; Differential Diagnosis *293*; Complications *294*; Natural History and Prognosis *294*; Guidelines for Management *294*; Management of Sick Infants *295*

**30. Double Outlet Right Ventricle** 297
*AN Patnaik*

Definition *297*; "Tetralogy of Fallot" Like Presentation *299*; "Taussig–Bing Anomaly" Presentation *301*; "Nonrestrictive VSD" Like Presentation *303*


JAYPEE BROTHERS

**31. Single Ventricle** **307**
***AN Patnaik***
Synonyms *307*; Definition *307*; History *307*; Incidence *307*; Embryology *307*; Anatomical Abnormalities/Classifications *308*; Hemodynamics *309*; Clinical Features *309*; Investigations *310*; Diagnosis *313*; Differential Diagnosis *313*; Complications *313*; Natural History and Prognosis *313*; Guidelines for Management *313*

**32. Truncus Arteriosus** **315**
***Anita Saxena***
Synonyms *315*; Definition *315*; History *315*; Embryology *315*; Etiology *315*; Incidence *315*; Classifications *316*; Pathology *317*; Hemodynamics *317*; Clinical Features *317*; Investigations *318*; Diagnosis *320*; Differential Diagnosis *320*; Complications *320*; Natural History *321*; Guidelines for Management *321*

**33. Complete Transposition of the Great Arteries** **322**
***Rohit Manojkumar, M Satpathy***
History *322*; Incidence *322*; Embryology *323*; Pathophysiology *323*; Coronary Arteries *323*; Associated Lesions *323*; Physiology *324*; Clinical Features *325*; Physical Examination *325*; Investigations *326*; Diagnosis *328*; Differential Diagnosis *328*; Natural History *328*; Guidelines for Management *329*

**34. Hypoplastic Left Heart Syndrome** **331**
***N Sudhayakumar, G Rajesh, BR Mishra***
History *331*; Incidence *331*; Noncardiac Anomalies *331*; Embryology *331*; Abnormal Anatomy *332*; Coronaries in Hypoplastic Left Heart Syndrome *333*; Hemodynamics of HLHS *333*; Clinical Features *334*; Investigations *334*; Diagnosis *335*; Differential Diagnosis *336*; Natural History *336*; Guidelines for Management *336*

**35. Total Anomalous Pulmonary Venous Connections** **338**
***M Satpathy, CD Gupta***
Synonym *338*; Definition *338*; History *338*; Incidence *338*; Embryology *338*; Classifications of TAPVC *338*; Hemodynamics *339*; Clinical Features *341*; Without Pulmonary Venous Obstruction and Low PVR *341*; Without Pulmonary Venous Obstruction and High PVR *341*; With Pulmonary Venous Obstruction *341*; Investigations *342*; Diagnosis *344*; Differential Diagnosis *345*; Complications *345*; Natural History *345*; Guidelines for Management *345*

**36. Anomalous Systemic Venous Connections** **347**
***BR Mishra***
Classification *347*; Embryology *347*; Persistent Left Superior Vena Cava *348*; Hemodynamics *348*; Clinical Features *348*; Investigations *348*; Left Superior Vena Cava Draining into Left Atrium *349*; Hemodynamics *349*; Clinical Features *349*; Investigations *349*; Inferior Vena Cava Interruption with Azygos Continuation *350*; Anomalous Connection of IVC to Left Atrium *351*; Anomalies of Coronary Sinus *351*; Total Anomalous Systemic Venous Connection *352*; Anomalies of Ductus Venosus *352*; Anomalies of the Valve of the Sinus Venosus *352*

**37. Congenital Pulmonary Arteriovenous Fistula** **353**
***BR Mishra, SN Routray***
Synonym *353*; Definition *353*; History *353*; Incidence *353*; Embryology *353*; Pathology *354*; Hemodynamics *354*; Clinical Features *354*; Investigation *355*; Cardiac Catheterization and Angiocardiography *355*; Diagnosis *356*; Differential Diagnosis *356*; Prognosis *356*; Complications *356*; Guidelines for Management *356*

**38. Complete Interruption of Aortic Arch** **358**
***BR Mishra, M Satpathy***
Definition *358*; History *358*; Incidence and Prevalence *358*; Classifications *358*; Embryology *358*; Associated Lesions *359*; Hemodynamics *359*; Clinical Features *359*; Investigations *360*; Diagnosis *360*; Differential Diagnosis *361*; Prognosis *361*; Guidelines for Management *361*

JAYPEE BROTHERS

**39. Eisenmenger Syndrome** **362**
*M Satpathy, SR Anil*
Causes *363*; Incidence *363*; Physiological Changes After Birth *363*; Pathology *363*; Heath–Edward Classification of Pulmonary Vascular Obstructive Disease *364*; Hemodynamics *364*; Clinical Features *364*; Investigations *365*; Diagnosis *367*; Differential Diagnosis *367*; Complications *368*; Prognosis *369*; Guidelines of Management *369*

## Part Four: Miscellaneous

**40. Fetal Echocardiography** **375**
*BR Mishra, HN Mishra*
Echocardiographic Anatomy and Physiology of Fetus *375*; Assessment of Fetal Cardiac Function *378*; Diagnosis of Fetal Arrhythmia *378*; Fetal Cardiac Interventions *378*

**41. Transcatheter Interventions in Congenital Heart Diseases** **380**
*BRJ Kannan, BR Mishra*
History *380*; Interventions Involving Dilatations *380*; Interventions Involving Occlusions *381*; Newer Interventions *381*; General Principles of Transcatheter Interventions *381*; Valvular Pulmonary Stenosis *382*; Valvular Aortic Stenosis *383*; Coarctation of Aorta *383*; Patent Ductus Arteriosus *384*; Atrial Septal Defect *384*; Ventricular Septal Defect *385*; Creation of Defect *385*; Other Interventions *386*

**42. Congenital Heart Disease in India** **387**
*Balu Vaidyanathan, M Satpathy*
Prevalence of Congenital Heart Disease *387*; CHD as a Contributor of Neonatal and Infant Mortality: Global Perspective *388*; Prevalence of CHD: Indian Scenario *388*; CHD as a Contributor to Infant Mortality: Indian Scenario *389*; Current Status of CHD Treatment in India *390*; Suggested Action Plan for CHD Management in India *391*

***Index*** ***393***

JAYPEE BROTHERS

CHAPTER 14

# Patent Ductus Arteriosus

M Satpathy, J Jayarajah

## DEFINITION

Patent ductus arteriosus (PDA) is the most common type of extracardiac shunt seen in clinical practice. It represents persistent patency of the vessel (duct) that normally connects the pulmonary artery (PA) and the aorta in fetus (**Fig. 14.1**). The functional closure of the duct occurs within 24 hours of birth in most of the cases. When this ductus remains patent after 3 months of birth in an infant born at term, is called persistent or PDA.

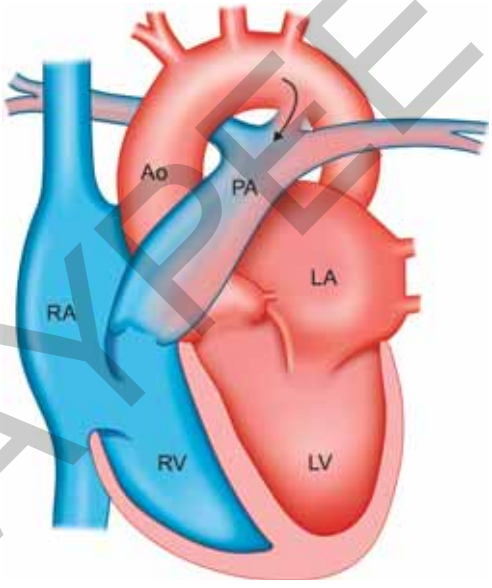


(Ao: aorta; RA: right atrium; RV: right ventricle)

**FIG. 14.1:** Schematic diagram, arrow showing a large patent ductus arteriosus communicating from aorta to pulmonary artery (PA) (arrow) with left atrial (LA) and left ventricular (LV) enlargement.

## HISTORY

Galen, the second century Greek physician, was aware of the presence of a connecting vascular channel, which was later on thought to be a ductus. The postnatal closure was first described by Highmore in 1651, a close friend of William Harvey, who demonstrated the importance of ductus in fetal life. George Alexander Gibson in 1900 described for the first time the typical continuous murmur of PDA. First PDA ligation surgery was done by Robert Edward Gross at Boston in 1938 and first catheter closure of PDA was by Rashkind and Cuaso in 1971.

## INCIDENCE

Patent ductus arteriosus accounts for 10–12% of all varieties of congenital heart diseases, excluding in premature infants. The incidence of PDA is high in infants born with low birth weight; with congenital rubella syndrome and at high altitude. In some families with PDA genetic predisposition is observed. Incidence of PDA is high in Char (heart-hand) syndrome an autosomal dominant disorder with typical 'duck-billed' facies and absence or hypoplasia of the phalanges due to mutation in the *TFAP2B* gene. Two-third cases of premature infants weighing <1.5 kg and almost all weighing <1 kg have PDA, which persists for days to months. Female preponderance is seen with a ratio of 2:1. Incidence of asymptomatic silent PDA

JAYPEE BROTHERS

in children and adults has increased due to wide availability of colour Doppler echocardiography.

## EMBRYOLOGY

The ductus arteriosus is derived from the sixth aortic arch. On the left side of the sixth aortic arch, the connection between the PA and aorta persists, which is known as ductus arteriosus, but on the right side, this connection to dorsal aorta regresses and disappear in fetal life. The ductus is interposed between the proximal portion of the left PA and the beginning of the descending aorta, just distal to the left subclavian artery. This vascular channel starts functioning from 6th week and remains open throughout the fetal life, which plays an important role by providing a communication between the pulmonary and systemic circulation. The ductus connects with aorta in an acute angle (about 35°) in the fetal life, which persists till neonatal period. If the aortic arch is right sided, the ductus may also persist on the right side. In this situation, it connects the right PA to right aortic arch just distal to right subclavian artery.

## ABNORMAL ANATOMY

In the neonatal period, the duct size and shape varies greatly from case to case. It may be long and narrow or short and wide. Usually, the ductus is conical in shape because closure starts from the pulmonary end, the aortic end is dilated known as ductus ampulla or ductus bump. The average length of the ductus is about 1 cm and the width varies from 0.2–2 cm. In fetal life, the diameter of the duct is almost equal to the diameter of the descending aorta and in neonatal period it is approximately one-half of it. Normally the ductus continues from the anterior surface of the aortic isthmus to the origin of the left PA on the left side of the trachea known as 'left-sided' ductus. Anatomical variations of the duct are, it may be on right side, the duct may be absent or there may be two ducti, one on each side or both may be on one side. When the ductus continue on the rightside of the trachea and enters the base of the right PA it is called 'right-sided' ductus, It is usually associated with right aortic arch or as a part of vascular ring. In some cases PDA takes an abnormal course known as vertical or tortuous PDA, seen in complex congenital cyanotic heart diseases with pulmonary atresia. When the aortic end is as wide as descending aorta, if persists after birth, is known as Window ductus.

## MECHANISM OF DUCTAL CLOSURE

Once the baby is born at full term starts crying and takes breath, the collapsed fetal lungs expand and pulmonary circulation starts functioning. The venous blood from right atrium (RA) goes to right ventricle (RV), passes through PAs to lungs, where it get saturated and return to left atrium (LA) through pulmonary veins and subsequently go to systemic circulation. Ductus arteriosus that was an essential channel in fetal life, because it was carrying almost all venous blood from the main pulmonary artery (MPA) to descending aorta, then to lower limbs and to placental circulation, is no more needed. In normal course, the ductus starts closing from the very 1st day of life. Functional closure starts by 12 hours and becomes complete in most of the cases (80%) within 48 hours. In some cases, it may be delayed for, 2–3 days more but the anatomical closure may take up to 3 months (normally 2–3 weeks). In premature infants, it is delayed for some weeks to 3 months and in some premature infants it may take 1 year for closure of ductus.

Initially, when ductus starts closing the thickened intimal layer is being pressed by contraction of the smooth muscles of the medial layer. Then infolding of the endothelium occurs due to migration of medial smooth muscles into the thickened intima that contains more mucoid substance. Then, further it leads to necrosis of the inner wall, caused by anoxia. This process is completed by dense fibrosis, causing complete closure and converting the duct to a ligamentous structure, within 2–3 weeks of birth. This ligamentous structure in later life is known as ligamentum arteriosum.

**Note:** The histology of medial layer of the ductus arteriosus is different as compared to other arteries including aorta and PA. The media of ductal artery consists of spirally arranged smooth muscles and increased content of hyaluronic acid; whereas media of other arteries consist of elastic fibers.

The closure of ductus arteriosus mainly involves a complex interaction of increased oxygen tension in the blood ($PO_2$) and reduction in circulating and locally produced vasodilating prostaglandin. Before birth $PO_2$ in the lumen of the PDA is about 18 mm Hg while after birth it is about 100 mm Hg. This increase in $PO_2$ triggers calcium influx into the cells of medial layer resulting in constriction of ductus. Rapid decrease in prostaglandin $E_2$ ($PGE_2$) also play important role for constriction of the ductus. Increased level of acetylcholine, bradykinin, and endogenous catecholamines also play some role for constriction of the duct. Nitric oxide (NO) and adenosine cause vasodilatation resulting in patency of ductus.

The underlying mechanism of delayed closure of ductus are decreased $PO_2$ due to any cause mainly respiratory disease and increased concentration of circulating $PGE_2$. For this reason, the incidence of patent ductus is about three times greater at high altitude and also high in premature or low birth weight infants. After birth to keep a prematured baby alive, the fluid balance, ventilator support, drugs, phototherapy indirectly help to keep the duct patent. Intrauterine closure of ductus is mainly due to inhibition of $PGE_2$, which causes fetal congestive cardiac failure and intrauterine death.

JAYPEE BROTHERS

## CLASSIFICATION OF PATENT DUCTUS ARTERIOSUS

### Clinical Classification

- *Small:* Continuous murmur is present but no or minimum signs of volume overload.
- *Moderate:* Continuous murmur is present with signs of volume overload.
- *Large:* Continuous murmur is present with mitral diastolic flow murmur and florid signs of volume overload.

### Hemodynamic Classification

- PDA is classified according to the degree of pulmonary arterial hypertension (PAH).
  - PDA with PAH
  - PDA with severe PAH but no reversal of shunt.
  - PDA with severe PAH and reversal of shunt
  - *Eisenmenger's PDA:* Short ejection systolic murmur (ESM) (no continuous murmur) with differential cyanosis (upper limb normal, pink, but lower limb cyanosis, blue)
- Classified as per pulmonary to systemic flow ratio.
  - *Flow ratio (Qp/Qs):* <1.5:1 = Small PDA
  - *Flow ratio (Qp/Qs):* 1.5–2.2:1 = Moderate PDA
  - *Flow ratio (Qp/Qs):* >2.2:1 = Large PDA

### Morphologic Classification

Morphologic classification (Toronto classification) is based upon the location of the narrowest diameter of the vessel

- *Type A*: Common type (65%) funnel or conical shaped PDA with a prominent ductal ampulla on the aortic end with the narrowest diameter s at the PA end.
- *Type B*: Seen in 18%, window type ductus, it is short with narrowing at the aortic end without an ampulla.
- *Type C*: It is long and tubular without significant narrowing along its course.
- *Type D*: Multiple areas of constriction in the ductus.
- Type E: It is long with a narrowing that is well anterior to the trachea.

  Types C, D, and E occur in <10% of cases of PDA.

### Angiographic Classification

As per internal ductal diameter

- <1 mm (silent duct)
- 1–1.5 mm (very small duct)
- 1.5–3 mm (small duct)
- 3–5 mm (moderate duct)
- >5 mm (large duct)

**Note:** Duct diameter <3 mm is considered small one. It is usually clinically not detected due to absent murmur known as "silent PDA" but two-dimensional (2D) echo with Doppler detect it.

In infants the duct diameter varies from 8 to 10 mm, which is equivalent to aortic diameter, the average length of the duct is 5–10 mm. In adults, duct size varies from 15 to 20 mm diameter.

### Pathophysiology

Normally, after birth the pulmonary vascular resistance (PVR) falls due to expansion of both lungs but systemic vascular resistance is increased due to elimination of low resistance placental circulation. The fetal blood flow from PA to aorta is reversed in neonatal period, so a left-to-right shunt starts functioning across the ductus/PDA (the term ductus and PDA are used interchangeably) that is from aorta to PA. As the aortic pressure remains higher than PA pressure throughout the cardiac cycle, a continuous left-to-right shunt is established. Excess blood through the ductus goes to PAs and then to lungs, which comes through pulmonary veins to LA, then to left ventricle (LV) and to aorta and from aorta again goes to the ductus. When PDA is small, a continuous left-to-right shunt is present but there is no PAH and there is no hemodynamic burden, LA, and LV size remains normal. With moderate shunt and no PAH, there occurs significant shunt, LA, and LV are volume loaded with enlargement of both chambers. With a large PDA, aorta, and pulmonary arterial pressure are equal. In addition to left-sided volume overload, there occurs pressure overload of RV. Infants with moderate to large PDA may develop heart failure. Gradually, the LV compensates with dilatation and hypertrophy leading to disappearance of features of heart failure. However, with increased flow, there occurs gradually progressive pulmonary vascular disease. As the PVR goes on increasing the left-to-right shunt gradually decreases and with the development of suprasystemic pressure right-to-left shunt is established. Left-sided volume overload is replaced by right-sided pressure overload.

The hemodynamic changes that occur in premature infants having PDA are different from that of mature infants (full-term baby) with similar sized ducts. Premature infants weighing <1.5 kg are not able to tolerate any extra volume; even though the ductus is a relatively small one, the LA and ventricle start dilating and give rise to left ventricular failure (LVF) and subsequently congestive heart failure (CHF), as because the compensatory mechanisms are not well developed. The sympathetic innervation of myocardium is not adequate and the premature infants have, low calcium

JAYPEE BROTHERS

level with increased amount of fetal hemoglobin. Because of low oxygen content, subendocardial ischemia occurs. In premature infants of birth weight <1 kg, acute respiratory distress syndrome is a common presenting feature and persistence of ductus arteriosus gives rise to added cardiovascular and hemodynamic (volume overload) burden. These very sick infants need intensive care management for their survival.

In some premature infants with patent duct, pulmonary hypertension remains equal with systemic one, and the PVR regresses very slowly because the fetal pattern persists for a long time for which a left-to-right shunt is not established early.

**Remember:** All large (nonrestrictive) post-tricuspid defects develop pulmonary hypertension due to direct transmission of systemic (LV) pressure through the defect to pulmonary circulation that leads to increased PVR, even in infants.

## CLINICAL FEATURES

The clinical manifestations of PDA are described under two main headings that is small and large PDA although hemodynamically there is another subset moderate sized PDA. The clinical pictures of moderate and large PDA are by and large similar with a few differentiating points. But again to emphasize, clinical course of premature infants differ from infants born with full term.

### Small PDA

These infants are normally asymptomatic, and have normal growth, they lead a normal life. Cases may remain undetected until examined for some other problems. Pulse is normal with pulse pressure within normal limit. Precordial activity is normal with apex beat of left ventricular type. A systolic thrill or a continuous thrill is palpable over left upper sternal border or infraclavicular area. First and second heart sounds are normally heard. No third heart sound is appreciated. A continuous murmur is audible over left first and second intercostal space and also over left infraclavicular area that is the hallmark of the diagnosis of PDA. This murmur is known as Gibson's murmur and typically, there occurs a late accentuation of systolic murmur that spills over the second sound and continues as diastolic murmur. It is relatively soft high-pitched murmur, heard better on supine position and more prominent after exercise. In infants, a short crescendo systolic murmur, just spilling over to diastole or even only a short crescendo systolic murmur is enough to diagnose small PDA. But in children with a similar sized PDA, it gives rise to a classical continuous murmur with a longer diastolic component. Sometimes a small duct, which is narrow but have a patent lumen may not produce audible murmur, it is only detected by colored Doppler echocardiogram (silent PDA or Doppler PDA).

### Large PDA

Infants born full term with a large PDA are symptomatic either by minor or major forms from early infancy. Tachypnea, tachycardia, feeding difficulty are main symptoms. In later days, repeated respiratory infections occur and the infant may develop CHF. Congestive heart failure is uncommon in 1st week of life. Usually, most of these infants thrive the crisis (repeated chest infection and CHF) but their growth is retarded. In childhood and adolescent period, they complain of easy fatigability, effort intolerance, and palpitation on mild-to-moderate exertion.

High-volume (water-hammer or bounding) radial pulse, wide-pulse pressure (due to diastolic steal of blood to the pulmonary circulation), hopping carotid pulsation, hyperdynamic precordium with forceful left ventricular apex are usual features of large PDA. A continuous thrill over left second space and sometimes left infraclavicular area up to axillary region may be palpable in children, but in infants usually only a systolic thrill is felt.

First heart sound is normally heard, second sound (both components) is usually not audible as buried within the continuous murmur and a left ventricular $S_3$ is present over the apex. In case of adult, $S_2$ is loud. Paradoxical splitting of $S_2$ occurs in some older patients because the pulmonary valve closes prematurely due to pressure of blood shunted into PA from aorta. Eddies sounds (multiple sounds) heard within the continuous murmur is another typical finding in cases of large PDA. These sounds are produced by turbulent flow inside the duct. This turbulence is caused by front-to-front collision of directionally opposite flow from the ductus and at the same time from RV to PA. The hallmark of PDA is the continuous murmur audible better over left upper sternal border and infraclavicular area; sometimes heard up to upper axillary region. In some cases, murmur is also audible over para vertebral area on the back. It is a high-pitched, harsh or rasping murmur better heard on supine position with crescendo and decrescendo quality. The continuous murmur is increased during inspiration, due to fall in PVR. The diastolic part of the murmur is usually short not long as in small PDA. This continuous murmur has several names, commonly known as Gibson's murmur or machinery murmur. The other names are cartwheel, humming top, churning, mill wheel, and train in tunnel murmur. In infants and children up to 3 years of age commonly an ESM is audible, the diastolic portion of murmur is not appreciable or very short. A mid-diastolic low-frequency murmur is heard over the apex, due to increase flow through the normal mitral valve in children and adolescents.

JAYPEE BROTHERS

In due course of time, when a patient attains adulthood, the clinical picture of large duct usually manifests in two ways: (1) Large duct with pulmonary hypertension but no shunt reversal, and (2) large duct with pulmonary hypertension with shunt reversal. With increase in age, some patients of first group change over to the second group when PVR increases causing shunt reversal. In this clinical setting, the following changes occur: (A) Signs and symptoms wise the infants show improvement but severe pulmonary hypertension with shunt reversal becomes clear. (B) The hyperdynamic precordium becomes quiet, left parasternal heave is felt and LV apex becomes RV type. (C) Cyanosis appears in lower limb (differential cyanosis) and rarely cyanosis on left upper limb is also noticed when left subclavian artery originates distal to ductus. (D) The second sound becomes prominent with $P_2$ louder than $A_2$ and closely split. (E) The ejection click is better audible over upper left sternal border and in expiration. (F) The diastolic part of continuous murmur disappears. The long systolic murmur becomes a short ESM and no flow mid-diastolic murmur (MDM) is audible over apex. In this setting in some cases an early diastolic murmur of pulmonary regurgitation over upper left sternal border and pansystolic murmur of tricuspid regurgitation over lower left sternal border are audible. In other words, florid signs of severe pulmonary hypertension with shunt reversal (Eisenmenger's syndrome) occur.

### Premature Infants with PDA

It is a well-known observation that in premature infants normal ductal closure is delayed. Another concomitant fact is premature infants have pulmonary disease with persistence of increased pulmonary resistance. With the advent of recent medical techniques and management, the survival of these premature infants has greatly improved.

Premature infants behave differently depending on the magnitude of left-to-right shunt, pulmonary vascular disease and their maturity status (that is birth weight and myocardial development) so the symptoms and signs of these premature infants vary from case to case. Infants without pulmonary vascular disease become stable early. A short systolic murmur is audible within 72 hours of birth indicating the presence of a left-to-right shunt and gradually the murmur becomes a long systolic one (high pitch and rocky quality) with $P_2$ louder than $A_2$ as the neonate gets older. In due course of time, all signs of large PDA appear with electrocardiography (ECG) and radiological evidences. Two-dimensional echo with Doppler confirms the size and hemodynamic status. The biomarker such as B-type natriuretic peptide (BNP) is raised in premature infants with PDA (not in older infants >2 week of age).

Premature infants with pulmonary vascular disease present with respiratory distress syndrome. It is to be managed first in ICU setting having all facility of assistance ventilatory support like continuous positive airway pressure (CPAP) and inotropic agents for intravenous use. Due to advent of recent medical techniques and management, the survival of these premature infants has greatly increased. With the treatment of surfactant replacement therapy the PVR decreases quickly thereby pulmonary function improves. In this situation, signs of PDA are not clinically detectable but seen with 2D-echo with Doppler (silent ductus). In some premature infants, with moderate-to-large shunt, because of redistribution of blood occur to different organs suffer from (1) cerebrovascular accidents and intraventricular hemorrhage, (2) renal function impairment, (3) subendocardial ischemia leading to myocardial dysfunction, and (4) gastrointestinal problems such as necrotizing gastroenteritis. If the infant survives the crisis and becomes stable, clinical signs of PDA gradually appear. The clinical evidence of the ductus becomes apparent by high-volume pulse, loud second sound and a systolic murmur heard over left upper sternal border. Initially, this systolic murmur varies with intensity or may be absent, only after some weeks of birth, it is persistently audible. If the ductus remains patent gradually the murmur extends into diastole overlapping the second sound, giving rise to a continuous murmur.

**Remember:** Systemic hypotension leads to multiorgan failure.

**Note:** The early manifestations of congestive cardiac failure in premature infants (not in matured ones) are episodes of apnea, bradycardia and raised arterial $PCO_2$. Hepatomegaly usually occurs after some weeks of CHF.

## INVESTIGATION

### Electrocardiography

The ECG is normal when the PDA is small. With a moderate or a large PDA left atrial enlargement (LAE) and left ventricular hypertrophy (LVH) are common (**Fig. 14.2**). Narrow deep "q" waves are present in $V_5$ and $V_6$ with upright "T" wave indicating volume overload of LV. This pattern regresses to normal after surgical closure of PDA. The ECG changes such as P-pulmonale (RAE), QRS axis toward right (>+110°) and right ventricular hypertrophy (RVH) are present, when pulmonary hypertension is severe with reversed shunt occurs.

### Radiography

The chest X-ray is normal when the shunt is small. Cardiomegaly with LV contour, LA enlargement and increased pulmonary vascularity (Plethora) (**Fig. 14.3**) are usual features of large PDA. The dilatation of MPA is the earliest radiological sign known as the cap of Zinn. Sometimes plethora is more on the right side. Aortic knuckle

JAYPEE BROTHERS




**FIG. 14.2:** Electrocardiography of large patent ductus arteriosus (PDA) showing left ventricular hypertrophy (LVH) (taken with half standardization 5 mm/mV).

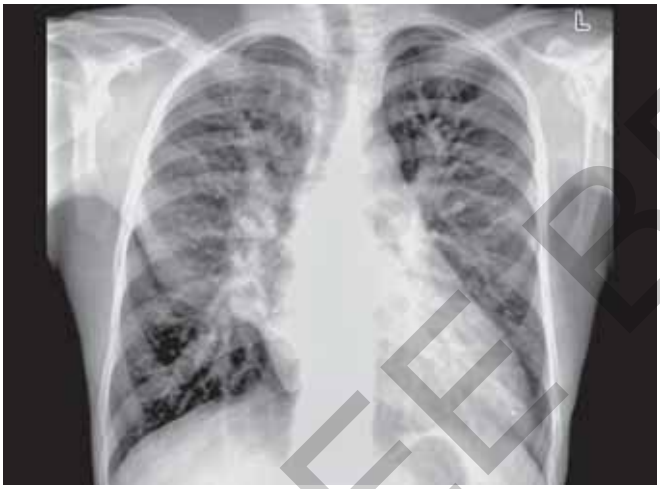

**FIG. 14.3:** Chest X-ray of PDA showing cardiomegaly, LV contour, left atrial enlargement and plethoric lung fields.

is prominent. Pruning of peripheral pulmonary vessels with prominent MPA indicate severe pulmonary hypertension. Calcification of ductus is seen in older patients. In infants with large duct, the ductal bump is seen in X-ray as a distinct shadow between the aortic knuckle and MPA.

## Echocardiography

Echocardiography is diagnostic. Parasternal short-axis view shows the origin of PDA from the descending aorta at the origin of LPA from MPA. A high-left parasternal view with tilting and angulation of the transducer in the plane of LPA images the whole length of PDA where MPA is seen to trifurcate into MPA, RPA and PDA (Ductal View). Size of the PDA is measured at the narrowest point before entry into the MPA. Small PDA is <1.5 mm, moderate PDA is between 1.5 and 3 mm, and large PDA is >3 mm. In infants subcostal and suprasternal windows can visualize a ductus and estimate its size and length. It is important to delineate the diameter of the duct at its joining site with descending aorta. In premature neonates, ductal diameter >1.5 mm is taken as hemodynamically significant PDA. Color Doppler imaging is highly sensitive in picking of a ductal flow. In a parasternal short-axis view near the base color flow detects a continuous mosaic jet entering the MPA near the origin of LPA and passing proximally along the left margin of the MPA. Colour Doppler overestimates size of the ductus and is not used for estimation of the size of PDA. Continuous wave (CW) Doppler signal by aligning the cursor along the jet gives a continuous high-velocity Doppler spectrum (**Figs. 14.4A and B**). Pressure gradient can be obtained by Bernoulli equation from peak velocity in systole and diastole. Presence of pulmonary and tricuspid regurgitation also helps in estimating PA pressure. Moderate-to-large PDA with significant left-to-right shunt shows features of left-sided volume overload like LA and LV enlargement. Ratio of LA to aorta dimension is directly proportional to the amount of shunt. PW Doppler detection of pan-diastolic flow reversal in descending aorta seen from supra-sternal window also indicates a significant left-to-right shunt. Color flow also helps in detecting the direction of shunt whether left to right, bidirectional or right to left. Calculation of quantity of flow at different sites by integrating 2D (cross-sectional area) and Doppler data (time velocity integral) measures the amount of shunt (Qp/Qs). To measure minimal diameter and ampulla size of the PDA is mandatory before device closure.

JAYPEE BROTHERS

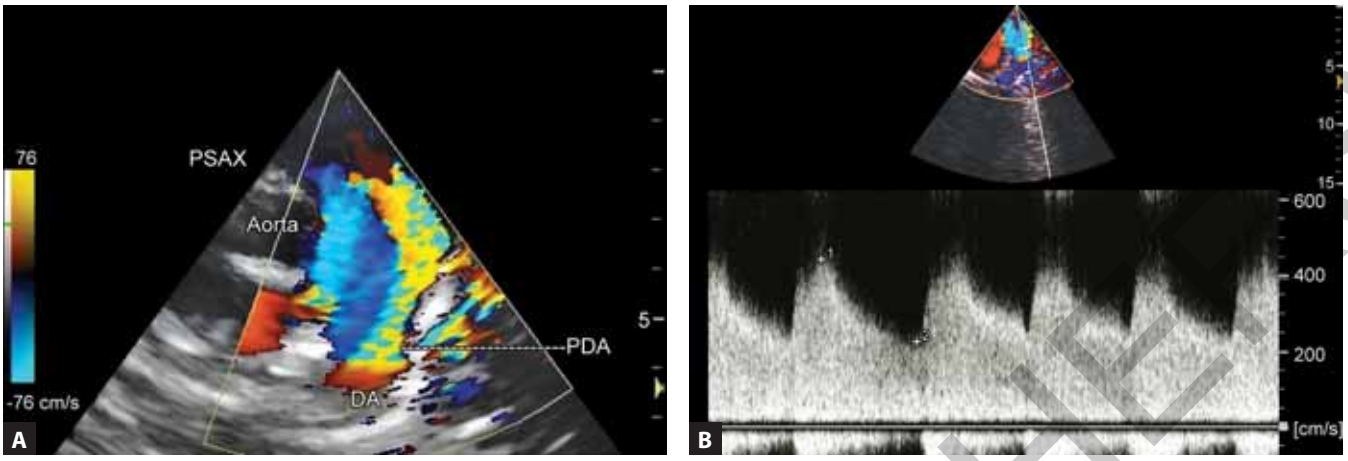


(PSAX: parasternal short-axis; DA: descending aorta)

**FIGS. 14.4A AND B:** Echocardiography of patent ductus arteriosus (PDA). (A) Showing color flow from descending aorta to pulmonary artery along its left margin and, (B) showing continuous turbulence obtained from the same site. Measurements in systole and diastole shows high gradient (pressure difference) between aorta and pulmonary artery indicating no significant pulmonary arterial pressure.

### Magnetic Resonance Imaging

Routine use of MR is unnecessary. In unusual situation such as ductal aneurysm or endarteritis, magnetic resonance imaging MRI may be helpful in diagnosis.

### Cardiac Catheterization and Angiography

Because echocardiography is a noninvasive and an accurate diagnostic procedure, cardiac catheterization is not necessary in most of the cases. It is necessary in cases of premature infants with cardiomegaly to exclude other associated lesions. The right heart catheterization is performed to measure PA pressure, PVR and the ratio of pulmonary to systemic flow. The catheter can pass from RA to RV to PA and through ductus to descending aorta. Sometimes, the catheter can pass from RA to RV then through ventricular septal defect (VSD) (if present) to aorta and then to descending aorta. However, LV angiogram or retrograde aortogram differentiates VSD from PDA. Selective angiography is done for definite diagnosis of ductus. Oxygen step-up by 5% at PA level over RV is suggestive of the presence of ductus. When oxygen step-up occurs at RV or RA level, other lesions such as VSD or atrial septal defect (ASD) are suspected and need to be excluded. Oxygen saturation, if less in lower limbs than upper limbs, the reversal of shunt may be considered. Depending on angiographic profile, to facilitate percutaneous catheter closure, PDA is classified into five groups (Group A–Group E) by Krichenko in 1989. Type A, conical type (narrow end at pulmonary insertion); Type B, window type (short and wide); Type C, tubular type (in between constriction); Type D, complex type; and Type E, elongated type (it is bizarre-shaped).

## DIAGNOSIS

### Small PDA

Patients are asymptomatic. General examination reveals no abnormality. The hallmark of diagnosis is a continuous murmur with longer diastolic component audible over upper left sternal border and infraclavicular area. Second sound is normally audible (not buried within murmur) and there are no eddies sounds. ECG findings and radiological pictures are not contributory. Echocardiography confirms the presence of ductus with its size and flow pattern.

### Large PDA

These patients may have history of heart failure in infancy and repeated chest infection from early childhood. High-volume pulse; precordial pulsation, cardiomegaly with left ventricular apex, a continuous thrill over left base, are usual findings. The hallmark of diagnosis is again the continuous murmur, rough and high-frequency in character (machinery murmur) audible over left base or left infraclavicular area and may extend up to left axillary area. It is a crescendo–decrescendo murmur with longer systolic and shorter diastolic component. The second sound is not audible, as it is buried in between the continuous murmur. Prominent eddies sounds are heard within the murmur. Left ventricular $S_3$ and a mid-diastolic flow murmur over apex are often present. ECG shows LAE and LVH. In adults, evidence of RVH, if noticed indicates severe PAH and reversal of shunt. Radiological signs of cardiomegaly with evidence of LAE and LV contour; prominent MPA and increased pulmonary vascularity are very helpful for the diagnosis of large PDA. Echocardiography confirms the site, size and the flow pattern of large PDA.

JAYPEE BROTHERS

## Differential Diagnosis

Conditions producing CHF in early infancy come as differential diagnosis. On clinical grounds, it is difficult to differentiate conditions such as large VSD, complete atrioventricular (AV) septal defects and persistence truncus arteriosus who present with heart failure in infancy. However, subtle clinical finding combined with ECG, X-ray and finally echocardiography can easily differentiate them.

Later age when these patients present with continuous murmur, other clinical conditions giving rise to continuous murmur are to be differentiated. They are (1) venous hum, (2) ruptured sinus of Valsalva aneurysm, (3) aortopulmonary (AP) septal defect, and (4) coronary arteriovenous (AV) fistula.

## Venous Hum

Venous hum commonly comes as a differential diagnosis for PDA but also most easily eliminated out. The continuous murmur (venous hum) is present over supra or infraclavicular areas due to functional narrowing of the veins. The character and intensity of which is significantly changed on pressure (or change of posture) of head and neck position, whereas it is not altered in case of PDA. Venous hum changes its character with phase of respiration but PDA murmur does not change. On clinical examination, no other abnormal cardiac findings are detected in case of venous hum.

## Rupture of Sinus of Valsalva Aneurysm

Sinus of Valsalva aneurysm usually ruptures into RV and sometimes into RA producing a continuous murmur. History of sudden onset of chest pain, dyspnea and CHF following unusual exertion in young adults, arose suspicions of rupture of sinus of Valsalva aneurysm. The murmur produced is a rough and continuous but superficial in character without eddies sounds. The long diastolic component of continuous murmur over upper sternal border goes in favor of PDA not for sinus rupture of Valsalva. It is echocardiography give the final diagnosis.

## Aortopulmonary Window

Aortopulmonary window may rarely have a continuous murmur. When present, it is difficult to differentiate from PDA. This murmur is better heard at one space lower than the usual site of PDA murmur. PAH develops early in AP widow with ECG evidence of RVH along with LV volume overload pattern. However, it is echocardiogram and in some cases angiography particularly retrograde aortography that establish the diagnosis.

## Coronary Arteriovenous Fistula

Relatively asymptomatic (sometimes complains of chest pain on exertion), acyanotic child with a superficial continuous murmur audible over lower sternal border (both the left and the right side) arose the suspicion of coronary AV fistula, which is differentiated from PDA by its characteristic murmur and eddies sounds.

For academic interest, causes of continuous murmurs are: (A) *Acyanotic group*—rupture of sinus Valsalva, coronary AV fistula, systemic AV fistula, AP window, anomalous left coronary artery from PA and coarctation of aorta. (B) *Cyanotic group*—pulmonary AV fistula, total anomalous pulmonary venous connection (TAPVC), tetralogy of Fallot (TOF )or TOF such as physiology with PDA, surgically created shunts and PA-VSD with AP collaterals. Conditions producing systolic murmur and early diastolic murmur (to and fro murmur) are also confused with continuous murmur, mainly VSD with aortic regurgitation (AR), AS with AR and absent pulmonary valve.

## COMPLICATIONS

- *Repeated chest infection:*
  - Severe form (bronchopneumonia) in infants, particularly in premature infants.
  - Mild-to-moderate form (in children and adolescents)
- *CHF:*
  - In premature infants with large PDA congestive failure develops in 1st week of life.
  - CHF develops in later age, if duct is large one.
  - CHF may occur due to infective endarteritis.
  - CHF develops in elderly patients having reverse shunt due to chronic RV pressure overload and polycythemia.
- *Infective endarteritis:* It is more common in adolescence and adults. Vegetations form at the pulmonary end of ductus, rarely at aortic end and over aortic valve. Small ducts are more prone for vegetations. It gives rise to CHF, pulmonary embolism, pulmonary infarction, pulmonary abscess, and systemic embolization.
- *Pulmonary hypertension and pulmonary vascular disease:* It is due to increased blood flow through large duct to PA which on long run leads to irreversible pulmonary vascular obstructive disease known as Eisenmenger syndrome.
- *Aneurysm of ductus arteriosus:* It is common in infancy and childhood. It develops at aortic end as an aortic diverticulum. It may develop as such (genetic factor) or due to infective endarteritis or iatrogenic after transcatheter occlusion. Falcon and Perloff classification states four types of aneurysmal dilatation: (1) Ductus

JAYPEE BROTHERS

patent at both ends, (2) nonpatent pulmonary end, (3) postoperative, and (4) spontaneous rupture of aneurysm. This aneurysmal dilatation of duct on chest X-ray gives an impression of mediastinal mass (ductal bump).

## LESIONS ASSOCIATED WITH DUCTUS

- Desirable lesions (ductus dependent lesions) when survival depends upon patency of ductus.
  - Partially dependent—pulmonary atresia with VSD, tricuspid atresia, TOF with severe pulmonary stenosis (PS) and TGA with PS.
  - Totally dependent—mitral atresia, aortic atresia, pulmonary atresia with intact septum, complete interruption of aortic arch and hypoplastic left heart syndrome (HLHS).
- Undesirable lesions—(survival is difficult due to patency) VSD, ASD, infradiaphragmatic TAPVC and AV canal defect. In these conditions, the duct should close early because it adds to the hemodynamic burden.

## PROGNOSIS

In general, patients having small duct lead normal life till late adulthood. Infective endarteritis is the only serious complication of a small duct that may shortens the lifespan. Patients having large duct are usually symptomatic from infancy. However, most of them live-up to adulthood. A few infants having large PDA with CHF die during infancy. The average age of death is 24 years in Abbott's group and 36 years in Shapiro and Key group (1943) in presurgical era. The downhill course occurs when these patients develop reversal of shunt due to pulmonary vascular disease. Those who suffer infective endarteritis also have poor prognosis at any stage of life. Surgery has changed the prognosis in these patients of large PDA.

## GUIDELINES FOR MANAGEMENT

### Medical Management

Patients having small PDA are asymptomatic and lead a normal life except the risk of developing infective endarteritis. Previously, it was left as such but nowadays PDA is closed either by catheter closure (device or coil closure) or by surgical ligation mainly to prevent the deadly complication of infective endarteritis.

The medical management for a premature infant is different from a full-term infant with same size PDA. Routine hemoglobin estimation is mandatory because anemia in these infants leads to multiorgan failure. High level of fetal hemoglobin is to be replaced by exchange transfusion. Once hemoglobin level is restored, myocardial affection (myocarditis), and peripheral tissue perfusion are corrected (show high oxygen content). Volume overload precipitate LVF which has to be treated or prevented. In this setting, diuretics like furosemide are used commonly. Lanoxin is used with caution, as it has no effect in premature infants, rather it invites toxicities. In matured infants with LVF due to PDA, lanoxin, and diuretics are drugs of choice. Electrolytes, blood glucose, and nutritional equivalent are to be corrected. Pharmacological closure of duct by drugs such as indomethacin and Ibuprofen are very often used because of their promising effect.

Indomethacin is used commonly to constrict the duct (to prevent volume overload) since 1983. Preferably, it is used within 10 days of birth. It has less effect in matured and later part of infancy or in children. The dose schedule is to start 0.2 mg/kg given by intravenous route or by nasogastric tube. It can be repeated after 1 day that is 24 hours later. In case infants have renal problem, it should not be used. In these cases, Ibuprofen is advised since 2000 for constriction of the duct (dose–10 mg/kg to start for 24 hours then by 5 mg/kg in two doses for 2 weeks). It is as effective as indomethacin, but longer use has its side effects.

In case of repeated LVF, or persistent CHF, besides conventional anti-failure drugs (lanoxin and diuretics) and ACE inhibitors, intravenous dopamine, and other inotropic agents are used to combat hypotension and to stabilize the infant before surgical procedure.

### Percutaneous Transcatheter Intervention

For patients having large PDA dictum is to advice for catheter closure or surgical ligation as soon as it is diagnosed mainly to prevent complications. Catheter closure (by single or multiple coils or plugs or double umbrella devices) is the method of choice in infants and young children. Smaller PDAs (<3 mm) are closed by different sizes of coils and large PDA is mainly closed by devices. Since 1998 PDA is mostly closed by Amplatzer duct occluder (ADO II or ADO II AS) of different sizes in infants to adulthood. It is a very safe and acceptable procedure, in spite of its potential complications such as coil embolization, femoral vessels occlusion and residual shunt problem.

### Surgical Management

Surgery is done irrespective of the size of PDA, particularly for large PDA (>8 mm diameter). Robert E Gross in 1957 did the first successful surgical ligation of PDA. Surgery (ligation and division of ductus under cardiopulmonary bypass) still has its own importance and it is indicated in cases of failure device closure, CHF, pulmonary hypertension (reversible) and repeated chest infection (controlled), calcified PDA and PDA with complex lesions. Since 1991 minithoracoscopic closure and video-assistant endoscopic surgery are emerging procedures for PDA closure. Surgery is rewarding and the

JAYPEE BROTHERS

mortality rate is <1%. Care should be taken to avoid injury to recurrent laryngeal nerve that is close to PDA besides phrenic nerve and thoracic duct.

## SALIENT FEATURES

- The ductus arteriosus connects normally the PA to aorta in fetal life through which major portion of RV output goes to descending aorta bypassing collapsed nonfunctional lungs.
- In postnatal period, functional closure of ductus starts by 10–15 hours and complete anatomical closure occur subsequently.
- Most of the premature infants have PDA even up to 3 months. Patent ductus arteriosus is essential in some patients having complex heart disease for their survival (duct-dependent lesions), whereas PDA becomes hazardous in some forms of congenital heart disease because it adds to the hemodynamic burden (LV failure in VSD and AV canal defect).
- Small PDA remains asymptomatic, it is suspected when a continuous murmur is heard over left infraclavicular area.
- Large PDA is diagnosed by high-volume pulse, LV apex, $S_2$ not audible as because berried within the continuous murmur with eddies sounds.
- ECG and X-ray show LA and LV enlargement with pulmonary plethora on X-ray. Echocardiogram with Doppler detects the continuous flow from aorta to PA. It also demonstrates the size of the duct, PA pressure, and LV function.
- Infective endarteritis is a potential life-threatening complication at any age irrespective of size of the duct.
- Early nonsurgical (device/coil closure) and surgical closure for all types of PDA is advised.

JAYPEE BROTHERS

for detailed information on cardiology books, visit our website www.jaypeebrothers.com, for detailed information on cardiology books, visit our webs

# Clinical Diagnosis of Congenital Heart Disease

***Salient Features***

- Each chapter has been thoroughly revised and updated.
- All importance has been given on clinical diagnosis keeping in view the need of students.
- A guide to recent management has been incorporated in each chapter.
- Every chapter has been described in a simple understandable language under clinically important headings.
- Simple schematic diagrams depicting the abnormal anatomy and its pathophysiological consequences are given for clear understanding of the disease.
- Salient features at the end of each chapter summarizing important points provide a short ready review.
- Characteristic points of electrocardiography, radiography, and echocardiography leading to correct diagnosis are well explained.
- Newer diagnostic modalities helpful for clinical diagnosis besides basic ones have been added for complete assessment.

**M Satpathy** completed MD (Medicine) from Utkal University, Odisha, India in 1970 and DM (Cardiology) from PGI Chandigarh, India in 1980. He is a retired professor of cardiology with 35 years of teaching experience in different medical colleges of Odisha, India. He is one of the editors of the book on "Rheumatic Fever and Rheumatic Heart Disease" published in 2013 by M/S Jaypee Brothers Medical Publishers (P) Ltd., New Delhi, India. He presented several scientific papers in state and national level conferences particularly in all Annual Conferences of Cardiological Society of India (CSI) from 1980 to 1990 and in some international conferences held in India. He has served as President of CSI, Odisha Chapter and Vice President of API, Odisha Chapter. He is a life member of CSI and a fellow of Indian College of Cardiology.

**BR Mishra** did his DM (Cardiology) from SCB Medical College, Cuttack, Odisha, India in 1994. He served as a teacher of cardiology in Medical Colleges of Odisha, India, before settling for practicing noninvasive cardiology. Echocardiography is his field of interest. He is one of the editors of the book on "Rheumatic Fever and Rheumatic Heart Disease" published in 2013 by M/S Jaypee Brothers Medical Publishers (P) Ltd., New Delhi, India. As a good academician and organizer, he has a number of publications and awards from many academic and nonacademic societies. He remained a regular contributor to the "Cardiology Update, CSI" since 2012, contributed to many textbooks and joined as faculty in many events of national and international repute. He is the fellow of Cardiological Society of India, Indian Academy of Echocardiography, Indian College of Cardiology, and European Society of Cardiology. He served as the secretary of the Cardiological Society of India, Odisha Chapter and as a reviewer to Indian Heart Journal. He is now the senior consultant cardiologist at the MAX Diagnostic Center at Cuttack, Odisha, India.

**Available at all medical bookstores**
**or buy online at www.jaypeebrothers.com**




**JAYPEE BROTHERS**
**Medical Publishers (P) Ltd.**
**www.jaypeebrothers.com**

Join us on facebook.com/JaypeeMedicalPublishers

Shelving Recommendation
**CARDIOLOGY**

