books, visit our website www.ejaypee.com, for detailed information on cardiology books, visit our website www.ejaypee.com, for detailed information on cardiology b

CLINICAL CARDIOLOGY

A Disease Specific Approach



Achyut Sarkar

JAYPEE

Contents

Section 1: Rheumatic Heart Disease

1. Acute Rheumatic Fever 3
2. Mitral Stenosis 32
3. Chronic Rheumatic Mitral Regurgitation 47
4. Secondary and Atrial Mitral Regurgitation 62
5. Aortic Stenosis 72
6. Aortic Regurgitation 92
7. Tricuspid Regurgitation 107
8. Tricuspid Stenosis 115
9. Multivalvular Heart Disease 119
10. Mixed Single Valve Disease 130

Section 2: Continuous Murmur

11. Patent Ductus Arteriosus 137
12. Aortopulmonary Window 146
13. Aneurysm of Sinus of Valsalva 149
14. Coronary Arteriovenous Fistula 154
15. Pulmonary Arteriovenous Fistula 159

Section 3: Congenital Left Ventricular Outflow Obstruction

16. Congenital Valvular Aortic Stenosis 169
17. Subaortic Stenosis 179
18. Supravalvular Aortic Stenosis 182
19. Hypertrophic Cardiomyopathy 186

Section 4: Fallot's Physiology

20. Tetralogy Physiology 201
21. Tetralogy of Fallot 206
22. Tetralogy of Fallot: Variants 225
23. Absent Pulmonary Valve Syndrome 232
24. Ventricular Septal Defect and Valvular Pulmonary Stenosis 237
25. Double Outlet Right Ventricle Subaortic VSD Pulmonary Stenosis 239

Section 5: Congenital Cyanotic Heart Disease with Continuous Murmur

26. Basic Approach 251
27. Tetralogy of Fallot and Pulmonary Atresia 254
28. Truncus Arteriosus 262

Section 6: Congenital Cyanotic Heart Disease: Management Issues

29. Congenital Cyanotic Heart Disease: A Multisystem Disorder 271
30. Surgical Outline of Complex Congenital Cyanotic Heart Disease 277

Section 7: Unequal Pulse

31. Basic Approach to Peripheral Artery Disease 299
32. Coarctation of Aorta 303
33. Takayasu's Disease 314

Section 8: Constrictive versus Restrictive Physiology

34. Constrictive Pericarditis 327

35. Restrictive Cardiomyopathy 337

Section 9: Left-to-right Shunt

36. Basic Approach to Left-to-right Shunt 353

37. Ventricular Septal Defect 358

38. Atrial Septal Defect 368

39. Transcatheter Closure of Atrial Septal Defect 379

Section 10: Right Ventricular Outflow Obstruction

40. Pulmonary Valve, Infundibular, Subinfundibular, and Artery Stenosis 389

Section 11: Electrocardiography

41. Basic Approach to Electrocardiography 405

42. Rheumatic Heart Disease 419

43. Congenital Left Ventricular Outflow Obstruction 421

44. Tetralogy Physiology 423

Section 12: X-ray Chest

45. Basic Approach to X-ray Chest 429

46. Tetralogy of Fallot 442

47. Congenital Cyanotic Heart Disease with Continuous Murmur 445

48. Unequal Pulse 447

49. Constrictive versus Restrictive Physiology 450

Section 13.: Echocardiography

50. Acute Rheumatic Fever 455
51. Mitral Stenosis 458
52. Mitral Regurgitation 468
53. Aortic Stenosis 475
54. Aortic Regurgitation 480
55. Tricuspid Valve Lesion 484
56. Patent Ductus Arteriosus 488
57. Hypertrophic Cardiomyopathy 491
58. Tetralogy of Fallot 496
59. Coarctation of Aorta 503
60. Constrictive versus Restrictive Physiology 506

Section 14: Hemodynamic

61. Basic Approach to Hemodynamic 515
62. Mitral Stenosis 519
63. Mitral Regurgitation 524
64. Aortic Stenosis 528
65. Aortic Regurgitation 533
66. Tricuspid Stenosis 536
67. Tricuspid Regurgitation 538
68. Continuous Murmur 542
69. Hypertrophic Cardiomyopathy 546
70. Tetralogy of Fallot 550
71. Double Outlet Right Ventricle 554

72. Mixing Physiology 556

73. Tetralogy of Fallot and Pulmonary Atresia 558

74. Truncus Arteriosus 561

75. Unequal Pulse 563

76. Constrictive Pericarditis 566

77. Cardiac Tamponade 571

78. Restrictive Cardiomyopathy: Endomyocardial Fibrosis 574

Index 577

2
CHAPTER

Mitral Stenosis

INTRODUCTION

In February 1819, Laennec examined a boy, aged 16 years, with a thrill and accompanying murmur, both ascribed to the prolonged contraction of the left auricle, the murmur being "dull but strong, exactly like that produced by the stroke of a file on wood." That was the first description of mitral stenosis murmur.

ETIOLOGY

Mitral stenosis is the most common cause of left ventricular inflow obstruction (**Box 1**). Rheumatic heart disease is still the most common etiology (**Box 2**) of mitral stenosis.[1]

EPIDEMIOLOGY

Rheumatic change is evidenced in 99% cases. During surgical excision,[2] in spite of the fact that in 40–50% of patients with mitral stenosis, there is no history of rheumatic fever.[3] Mitral stenosis is called a "female disease" with a 4:1 female preponderance; when associated with mild mitral regurgitation, ratio is 3:1; when regurgitation is severe, ratio is 1:1.[4] Mitral stenosis is commonly associated with other valvular lesions (**Table 1**).[5]

BOX 1 LV inflow obstructions.

- MS
- Left atrial myxoma
- Left atrial ball—valve thrombus
- IE with large vegetation
- Cor triatriatum

(IE: infective endocarditis; LV: left ventricular; MS: mitral stenosis)

BOX 2 Etiology of nonrheumatic MS.

- Congenital MS
- Carcinoid disease
- SLE
- Rheumatoid arthritis
- Fabry disease
- Whipple disease
- Methysergide therapy
- Extensive mitral annular calcification

(MS: mitral stenosis; SLE: systemic lupus erythematosus)

TABLE 1: Rheumatic MS and associated valve lesions.[5]

Lesion patterns	Frequency (%)
Isolated MS	37.1
MS + MR	35.7
MS + AR	26.9
MS + AS	2.3
Multivalvular involvement	38% of patients with MS

(AR: aortic regurgitation; AS: aortic stenosis; MR: mitral regurgitation; MS: mitral stenosis)

JAYPEE BROTHERS

PATHOLOGICAL ANATOMY

Initial valvulitis causes abnormal flow pattern, which over a long period, results in leaflet thickening, commissural fusion, and chordal thickening, shortening and fusion, leading to symptom-producing mitral stenosis. Posterior mitral leaflet (PML) is thickened and rigid in almost all cases. However, PML involvement does not produce obstruction. Anterior mitral leaflet (AML) thickening and rigidity may produce obstruction. Obstruction is mostly due to:[6]

- *Commissural type*: Most common and due to commissural fusion.
- *Cuspal type*: Cups become stiff, rigid structure.
- *Chordal type*: Chordae are thickened, fused, and shortened.

Initial rheumatic valvulitis causes inflammatory thickening, pseudoprolapse, and retraction leading to variable degree of mitral regurgitation. Over years, mitral regurgitation may increase or abate. What factors lead to severe obstructed lesion is still debatable.

- Subclinical recurrence
- Smoldering myocarditis
- *Selzar and Cohn theory*: Mitral stenosis begets mitral stenosis.[6]

PATHOPHYSIOLOGY

Described in the Chapter 62.

CLINICAL PRESENTATION

Age of Presentation[7]

The age of presentation after the initial rheumatic fever is variable. Presentation at younger age indicates severe initial carditis and recurrent carditis whereas, late presentation indicates a less severe initial carditis, which deteriorates gradually over decades.

In Wood's series, average age of presentation was 31 years of age, with acute rheumatic fever at the age of 12 years with a latent period of 19 years.[4] In developing country like India, Africa, average age of presentation is before 20 years of age.[8] In developed country like America, Canada, it takes 15–20 years of latent period for symptoms to occur and another 5–10 years to severe symptoms with average age of presentation between 45 and 65 years of age. Patient with juvenile mitral stenosis may present with features of severe mitral stenosis within 6–12 years of age.

Presentation

Common mode of presentations is:

- Symptoms due to pulmonary venous hypertension.
- Symptoms due to pulmonary hypertension.
- Symptoms due to atrial fibrillation (AF).
- Symptoms due to thromboembolic complications.
- Others

Pulmonary Venous Hypertension

Dyspnea, orthopnea, and paroxysmal nocturnal dyspnea are the most common presenting symptoms. Class of dyspnea depends on the valve area, age, and severity of pulmonary venous hypertension (**Table 2**). As stenotic process may progress slowly, patient may accommodate lifestyle to accommodate the symptom. Proper history taking only can reveal the class of dyspnea.

Paroxysmal dyspnea due to pulmonary edema is more common than classical paroxysmal nocturnal dyspnea. Over years, frequency of both events comes down due to thickening of the alveolar-capillary membrane and overgrowth of the pulmonary lymphatic system. Precipitating factors are:

- Paroxysmal AF
- Infection
- Fever
- Overexertion
- Mental stress

TABLE 2: Mitral valve area (MVA) and functional class.

Classes	MVA	Symptoms
I	>2.5 cm^2	No symptoms
II	1.5–2.5 cm^2	Dyspnea on average exertion
III	1.0–1.5 cm^2	Dyspnea on minimum activities, orthopnea, and paroxysmal nocturnal dyspnea (PND)
IV	<1 cm^2	Dyspnea at rest
V	<1 cm^2	Both fatigue and dyspnea at rest, bedridden

JAYPEE BROTHERS

Pulmonary Hypertension

As commonly thought, development of pulmonary hypertension does not reduce symptom of pulmonary venous congestion. In a study on pulmonary hypertension in mitral stenosis,[9] conclusion was—"these results tend to confirm our clinical impression that severe pulmonary hypertension is associated with attacks of dyspnea and suggests that the increased arteriolar resistance may not be "protective" in nature."

As resting cardiac output starts reducing in severe mitral stenosis on development of significant pulmonary hypertension, patient develops both fatigue as well as dyspnea. Gorlin[10] described a functional classification (**Table 3**) of symptoms correlating valve area and pulmonary hypertension.

Left Ventricular Dysfunction

Vide Chapter 62.

Atrial Fibrillation

Atrial fibrillation is common in mitral stenosis. Its prevalence increases with age and left atrial size. Severity of mitral stenosis is only partially related. In severe mitral stenosis, prevalence of AF is 10% in younger than 30 years of age whereas, 50% in those older than 50 years of age. Holter monitoring may show silent AF in 50% cases of mitral stenosis, out of which 95% are asymptomatic. The mechanism[11] of AF in mitral stenosis is:

TABLE 3: MVA, PH, and functional class.

Groups	MVA (cm^2)	PVR	Symptoms
1	>1.3	Normal	Mild dyspnea
2	0.7–1.3	Up to four times to normal	PND, orthopnea
3	0.4–0.7	Four to seven times to normal	Balanced, fatigue
4	0.4–0.7	More than seven times to normal	Severe symptom, right heart failure

(MVA: mitral valve area; PH: pulmonary hypertension; PND: paroxysmal nocturnal dyspnea; PVR: pulmonary vascular resistance)

- Atrial dilation
- Fibrosis of atria, internodal fiber, and sinoatrial node, possibly due to initial carditis involving atrial tissue.

Paroxysmal AF is the most common mechanism of sudden deterioration of a stable mitral stenosis patient. However, in long-standing mitral stenosis, left atrium losses its "booster" effect. Thus, loss of atrial booster on development of AF may not always have a clinical deterioration. Persistent or permanent AF in severe mitral stenosis leads to increasing gradient on one hand and reduced cardiac output on other hand. Patient presents with both dyspnea as well as fatigue. AF itself causes atrophy of atrial muscle and inhomogenicity of conduction, leading to permanent AF.

Thromboembolic Complications

Left atrial thrombus formation and embolic events decide the major morbidity. About 20% newly diagnosed mitral stenosis patient not on anticoagulant show left atrial thrombus[12] whereas 90% of patients with detectable thrombus have concomitant AF. Left atrial enlargement is the most important predictable factor for thrombus formation. Due to increased size as well as incomplete emptying, blood velocity is diminished in left atrium, expressed as swirling motion of echogenic blood. This is spontaneous echo contrast, which is an independent risk factor for left atrial thrombus.

Left atrium in mitral stenosis has been described as a region-specific hypercoagulable state.[13] Mitral stenosis patients, even on sinus rhythm, may be associated with increased plasma concentration of D-dimer and antithrombin III,[14] indicating enhanced coagulation activation and thrombogenesis.

Cerebral embolism is most common and occurs in this location in 60–70% cases. Lower limb artery, splenic artery, mesenteric artery, and renal artery embolism may occur. Acute chest pain should raise the suspicion of coronary artery embolism. Pulmonary embolism from right atrium leads to pulmonary infarct. Following factors, predictors of pulmonary embolism, are:

1. Presence of left atrial thrombus.
2. Duration of disease and age are other factors.
3. Severity of mitral stenosis has no direct effect on the probability of event.
4. Presence of significant aortic regurgitation.

JAYPEE BROTHERS

Incidence is around 16–18% cases. Thromboembolic event may occur in presence of sinus rhythm in 20% cases, which raise the probability of transient AF or infective endocarditis. In 40% cases of mitral stenosis with sinus rhythm, there may be spontaneous echo contrast. Left atrial clot has been demonstrated in few patients with sinus rhythm. Left atrial appendicular dysfunction, leading to stasis and thrombus formation, is the plausible explanation. Prognosis may be significantly affected by systemic thromboembolic event. Mortality is high and may be around 20%. In 25% cases, embolic event may be recurrent.

Hemoptysis

Incidence of hemoptysis in mitral stenosis is coming down in recent era. As classically described by Paul Wood, hemoptysis may be due to:

- Profuse bright red hemorrhage, due to rupture of bronchopulmonary varices, secondary to sudden rise of pulmonary venous pressure.
- Pink, frothy sputum associated with acute pulmonary edema.
- Blood-streaked sputum associated with paroxysmal dyspnea.
- Blood-streaked sputum associated with attacks of "winter bronchitis." Mitral stenosis causes chronic passive pulmonary venous congestion, leading to chronic bronchial hyperemia. Hyperemia results in excessive bronchial mucous production, which presents as "winter bronchitis."
- Hemoptysis associated with pulmonary embolism.

In Wood's series, massive hemoptysis or pulmonary apoplexy was found in 18.3% cases and blood-stained sputum or congestive hemoptysis in 16.5% cases. Shunting of blood from high-pressure pulmonary veins to bronchial veins, so called bronchopulmonary varices, which tend to bleed easily, explains massive hemorrhage. Pleurohilar veins, a connection between pulmonary veins and azygos veins, may be another source of pulmonary apoplexy.[15] In early stage of mitral stenosis, these vessels are thin walled and bleed easily. Over years, their walls thicken appreciably and do not bleed easily. This explains why massive bleeding tends to cease spontaneously by 2–3 years. When pulmonary vascular resistance is >10 units, hemoptysis is uncommon.

Persistent Cough and Hoarseness

Pulmonary venous hypertension and left atrial enlargement compressing left main bronchus may cause persistent cough. Enlarged left atrium and pulmonary artery may compress left recurrent laryngeal nerve, leading to hoarseness, described as Ortner's syndrome or Cardiovocal syndrome.

Chest Pain

Angina is more common, when pulmonary hypertension is severe. Wood explained it due to functional impairment of coronary blood flow due to limitation of cardiac output. Right ventricular hypertrophy secondary to pulmonary hypertension may cause angina-like chest pain. Rarely, coronary or pulmonary embolism may cause sudden severe chest pain.

CLINICAL EXAMINATION

Mitral Facies

This is rarely seen nowadays. It may be found in severe mitral stenosis, with low cardiac output and increased peripheral resistance leading to cyanosis in fingers, face, and occasionally lips. On the background of bluish tinge, there will be malar flush, due to engorged veins in the cheeks, secondary to systemic venous congestion.

Jugular Venous Pulse

Jugular venous pulse is unremarkable in uncomplicated mitral stenosis. Associated pulmonary hypertension produces a prominent *a* wave and tricuspid regurgitation may produce a prominent *v* wave. On development of AF, *a* wave is lost, *x* descent becomes inconspicuous, and *v* wave occurs earlier, followed by *y* descent. Accordingly, pressure pulse shows only a positive *v* or *cv* wave and one descent.

Pulse

Severe mitral stenosis, particularly in presence of pulmonary hypertension, may produce low volume pulse. Otherwise it is unremarkable, excepting its irregularity in presence of AF.

JAYPEE BROTHERS

Palpation

Left ventricle may be normally filled in presence of moderate mitral stenosis, but is underfilled in presence of severe mitral stenosis, particularly in presence of pulmonary hypertension. Under filled-left ventricle, in left lateral decubitus, it may impart a palpable impulse, which is less than normal in amplitude. It is associated with a palpable sound, first heart sound (S1) producing a taping feeling, described traditionally as taping apical impulse. A tapping apical impulse indicates a pliable mitral leaflet. In severe right ventricular hypertrophy, right ventricle may form the apex, which may be misinterpreted as left ventricular apex. Diastolic thrill is usually present in left lateral position.

Though second heart sound (S2) (P2 component) may be palpable, pulmonary artery pulsations is rarely palpable. Opening snap (OS) may be palpable over a wider area.

Left parasternal impulse of varying grade is palpable depending upon degree of pulmonary hypertension.

Palpable left ventricular third heart (S3) sound or fourth heart sound (S4) is unusual in significant mitral stenosis, even in presence of other lesions.

Auscultation

First heart sound is loud as because of the high atrioventricular (AV) gradient keeps the mitral valve (MV) leaflets wide open at the onset of ventricular systole. More open the valve remains at the onset of ventricular systole, more distance the leaflets have to travel from the open to closed position. This long travel results in the valve closure during the steeper part of the left ventricular pressure pulse, producing loud S1. Thus, increased velocity from a wide opening position creates the effect.

Its quality is short, sharp, and slapping. First heart sound may be heard all over precordium and exceeds S2 in loudness even at base. Rheumatic process commonly makes PML fixed whereas, loudness of S1 depends upon leaflet mobility. This may be explained by larger AML, which remains more mobile than PML and AML contributes mostly for the nature and loudness of S1.

The intensity of S1 bores no relation to severity of mitral stenosis. A loud S1 only rules out significant mitral regurgitation.[4] First heart sound is also delayed in mitral stenosis. This is because first 0.01 second of systole is occupied with raising the left ventricular pressure to atrial level. First heart sound may occasionally be soft (**Box 3**).

BOX 3 **Soft first heart sound.**

- Calcified nonpliable valve
- Mitral regurgitation
- Aortic regurgitation
- Low output syndrome
- Severe PAH and RVH displacing LV

(LV: left ventricular; MS: mitral stenosis; PAH: pulmonary arterial hypertension; RVH: right ventricular hypertrophy)

Second heart sound (P2 component) is loud. Its loudness, audibility on wider area, and split depend on the severity of pulmonary hypertension. However, P2 is rarely transmitted to apex, unless the apex is formed by right ventricle. Associated findings of severe pulmonary hypertension may be present.

Opening snap: Opening of a normal AV valve is acoustically silent. Sudden tensing of the stenosed MV at its full opening produces the mitral OS. It is like S1, mostly contributed by AML. It occurs 40–120 ms after second heart sound, well after isovolumic relaxation time. This is because OS is occurring not exactly with MV opening, rather after its full excursion. Thus, transmitral flow begins before OS with maximum flow occurring after OS.

Opening snap is a high-pitched sound, which is best heard medial to the apex. As it is a loud sound, it can be heard over a wide area of the precordium. Occasionally, it may be palpable. As mentioned in the study[16]—"*the OS was best heard in the supramammary area. Maximum audibility, however, was shared between two or more areas being the left sternal edge and the mitral area and the least common the pulmonary area.*"

An audible OS[17] indicates that the valve is pliable and probably suitable for valvuloplasty. More importantly, it is the most important indicator of severity of MS. Severe the stenosis, higher will be the left atrial pressure. Left atrial pressure cross over the left ventricular pressure pulse, which indicates opening of MV, will be earlier. A2-OS interval varies from 40 to 140 ms. Shorter the A2-OS interval, severe will be the MS (usually below 80 ms). One should focus during

JAYPEE BROTHERS

expiration, when two components are S2 and OS. If the cadence simulates a closed split, it indicates early OS and severe mitral stenosis. If the cadence simulates S3, it indicates late OS and mild mitral stenosis.

However, this interval may be affected by other factors, such as tachycardia (shortened diastole, shorter time for left atrium for emptying leading to shorter interval), bradycardia (longer diastole and increased interval), aortic stenosis (delayed A2 and shorter interval), mitral regurgitation (early OS and shorter interval), low cardiac output (low atrial pressure, delayed OS, and longer interval), and high left ventricular end-diastolic pressure (low gradient across MV, delayed OS, and longer interval).

Light exercise shortens A2-OS interval by tachycardia and increased preload. Thus, exercise may unmask severity of mitral stenosis in otherwise doubtful case. AF does influence S2-OS interval. After short cycle, as left atrium gets lesser time and its pressure remains high, OS occurs earlier with lesser A2-OS interval than after long cycle.

Opening snap is absent when stenosed MV is calcified and nonpliable. Only tip calcification does not affect, but its extension to the body affects OS. This sound is often absent in congenital mitral stenosis as because the leaflets are not pliable. OS may persist even after valvuloplasty.

Mitral OS may be present in situations, other than mitral stenosis (**Box 4**).[18,19] In an elegant study[20] with echocardiogram and phonocardiogram correlation, mitral OS was found in many other situations.

Increased flow across MV may produce an opening sound. It typically occurs 90–110 ms after A2, of lesser intensity and correlates to full descent of AML opening and before rapid filling phase, i.e., S3.

BOX 4 **OS in lesions, other than MS.**

- MR
- VSD
- PDA
- Tricuspid atresia with a large ASD
- TOF occurring after BT shunt
- Thyrotoxicosis

(ASD: atrial septal defect; BT: Blalock–Taussig; MR: mitral regurgitation; MS: mitral stenosis; OS: opening snap; PDA: patent ductus arteriosus; TOF: tetralogy of Fallot; VSD: ventricular septal defect)

TABLE 4: **Opening snap (OS) versus S3.**

	OS	S3
Frequency	High	Low
Location	Wider area	At apex
Best heard	With diaphragm, anybody position	Left lateral decubitus position with bell
Interval: A2 to: OS	40–140 ms	100–200 ms
Character	Sharper and louder	Dull and softer

Opening snap versus A2-P2: OS may be confused with P2, particularly when A2-P2 is relatively wide or A2-OS is very closed in severe mitral stenosis. Deep inspiration causes A2-P2 gap wider and one should get three sounds in left upper parasternal area—A2, P2, and OS. Inspiration widens A2-P2 gap and increases intensity of P2 whereas, A2-OS gap remains unaltered and intensity of OS may be diminished. As it is a high frequency sound, it is sharper than P2. Standing reduces A2-P2 gap but increases A2-OS gap (**Table 4**).

Well's index[21] is another indicator of severity before the era of echocardiography. It is an electrocardiogram (ECG)-phonocardiogram correlation and is expressed as Q-S1 interval. More severe is the stenosis, more will be the left atrial pressure. Thus, MV closure, which occurs when left ventricular pressure exceeds left atrial pressure, is delayed. Q wave is the onset of left ventricular contraction, i.e., isovolumetric contraction phase. Thus, severe is the stenosis, more prolonged will be Q-S1 interval. In the same tune, severe the stenosis, shorter is the A2-OS interval, i.e., isoventricular relaxation phase. This may be expressed in a better way: Q-S1—A2-OS, which was named Well's index (**Fig. 1**). When this value is over –1, mitral stenosis is severe.

Mid-diastolic murmur (MDM) is very characteristic of significant mitral stenosis. Patient should be in left lateral position; apex should be localized where the bell should be placed. It starts with OS, denoting the beginning of rapid filling phase. Then it is reduced in slow filling phase. It reappears during active atrial contraction, producing the presystolic component, ending in S1. Essentially, it is a decrescendo-crescendo murmur. Presystolic murmur is described as accentuation because of the waning phase of the murmur during slow filling phase.

JAYPEE BROTHERS

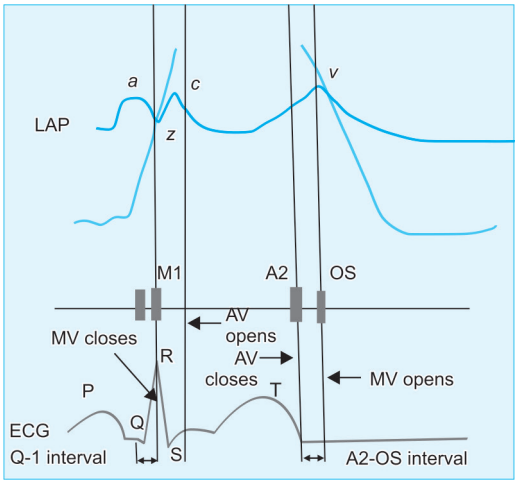

(AV: aortic valve; ECG: electrocardiogram; MV: mitral valve; OS: opening snap)

Fig. 1: When left ventricular pressure crosses up left atrial pressure curve at z point, the mitral valve closes (S1 or M1). Q1 interval is the interval from Q wave in ECG to M1/S1. As left ventricular descending curve crosses down left atrial pressure (v), the mitral valve opens to produce opening snap (OS). Thus, A2-OS interval is determined.

From the duration of the diastolic murmur, severity of mitral stenosis can be decided. In mild mitral stenosis, as pressure gradient between left atrium and left ventricle dissipates shortly, the murmur does not extend much in late diastole. It may or may not reappear in presystole with a silent phase in between. Sometimes, murmur may have only presystolic component without the mid-diastolic phase. In moderate mitral stenosis, there are two distinct components, with a decrescendo phase in between. In severe mitral stenosis, with a persistent left atrial-left ventricular gradient throughout, MDM extends in late diastole and ends as presystolic component at S1. Longer the murmur, severe is the stenosis.

Hemodynamically being a low gradient, high flow situation, mitral stenosis murmur is of low frequency in nature. As being low frequency murmur, it is very much localized. It is best heard in left lateral position at apex only with the bell of stethoscope being pressed on chest wall very lightly. A few sits up make the murmur more prominent. In high output situation such as fever, infection murmur may become of mixed frequency, rougher, and more audible over wider area.

Intensity of MDM is not related to severity of mitral stenosis. Rather high flow across the stenosed valve may produce excess turbulence and high-grade murmur. However, flow remaining constant, severe the stenosis more will be the turbulence across the valve. Thus, intensity of murmur may have a thin relation to severity of mitral stenosis. In low flow situations, such as heart failure, severe pulmonary hypertension, and severe mitral stenosis itself, intensity of MDM may be diminished. Concomitant severe aortic regurgitation or aortic stenosis by enhancing left ventricular diastolic pressure may reduce intensity of the murmur. In Lutembacher's syndrome, as left atrium is decompressed through atrial septal defect (ASD), intensity of MDM may be reduced. On the other hand, intensity of MDM may be increased during tachycardia, post-short cycle length of AF, and associated mitral regurgitation.

A study[22] comprising echocardiogram, phonocardiogram, and apex cardiogram proposed a new concept regarding the mechanism of diastolic rumble. The diastolic rumble begins after the E point in echocardiogram, related to the closure of the MV and is never recorded during opening movement of the MV. Opening movement of the MV ends at E point, 20–30 ms after OS. Thus, the mechanism of diastolic rumble is due to impact between increased velocity of forward flow and the backward movement of the closing mitral leaflet.

The above study concluded—"this mechanism explains (1) the frequently noted gap between the OS and the onset of the diastolic rumble, (2) the reduction in amplitude or disappearance of the diastolic rumble in calcified mitral stenosis."

According to Levine and Love, mitral stenosis may be silent in 5–10% cases (**Box 5**).[23]

Presystolic component was described by Fauvel long back in 1843. This component can be heard in all cases of mitral stenosis, even when mitral stenosis is mild. A pressure gradient across MV as low as 5 mm Hg can produce

BOX 5 Silent MS.

- Calcified nonpliable valve
- Mitral regurgitation
- Aortic regurgitation
- Low output syndrome
- Severe PAH and RVH displacing LV

(LV: left ventricular; MS: mitral stenosis; PAH: pulmonary arterial hypertension; RVH: right ventricular hypertrophy)

JAYPEE BROTHERS

presystolic murmur. This may be present not only in sinus rhythm but also in AF, which denotes mechanism other than late atrial contraction for this presystolic component. Initial concept was that the component is due to vibration of the AML or due to tricuspid valve closure. Criley first proposed that the component occurs after atrial systole, when MV is closing.[24] There is progressive narrowing of the MV annulus in the last phase of ventricular diastole. In fact, the valve closure starts 60 ms before final closure and S1. In presence of significant gradient, flow continues through the closing valve, producing the presystolic component. At the same time, motion of the AML contributes to the murmur—"the movement of the valve leaflets in an opposite direction to the continued forward blood flow provides a mechanism for vortex shedding, i.e., conditions for the production of a murmur."[25]

Atrial contraction may have a role, when the rhythm is sinus. Atrial contraction reinforces the forward flow, as a result of which the impact of forward flow and closing leaflet is more pronounce and the presystolic component starts earlier. Thus, in mitral stenosis with AF, presystolic component does not have any contribution from atrial contraction and starts later than that in sinus rhythm. In presence of AF, presystolic component occurs after short cycle, as there is inadequate emptying and left atrial pressure remains high in compare to the long cycle.

This concept has been challenged for the following reasons:[26]

- Presystolic component in presence of AF occurs later in timing in compare to sinus rhythm.
- The accentuation occurs after the ventricle has started contracting. Thus, the sound is not truly presystolic, rather early systolic or preisovolumic. Thus, it is difficult to understand conceptually, how mitral flow velocity can be enhanced during early ventricular systole.
- Early systolic sound may be found in AF without mitral stenosis. The sound resembles crescendo murmur, which is accentuated on short cycle.
- The sound results from the initial contraction of the ventricle, which acts to decelerate abruptly the flow of blood from left atrium. Like S3, the sound is ventricular in origin.

Effect of Atrial Fibrillation

- First heart sound is variable in intensity and it varies inversely with preceding cycle length. Thus, it is louder after short cycle. Occasionally, the intensity does not vary or it may show a paradoxical relation to cycle length.
- A2-OS interval varies directly with previous cycle length.
- Presystolic component is preserved in short cycle.
- In severe mitral stenosis, presystolic component may be present, even in long cycle.

Evolution of Clinical Finding

Paul Wood described three grades.

- *Grade I*: Mild stenosis—Loud S1and presystolic murmur.
- *Grade II*: Moderate stenosis—Appearance of OS and long diastolic murmur.
- *Grade III*: Considerable stenosis.

Paul Wood put critical stenosis of MV area (MVA) at 1 cm^2. At this orifice area, adequate cardiac output can only be maintained with a left atrial pressure around 20–25 mm Hg at rest. This causes pulmonary venous congestion. Exercise, excitement, or any cause leading to tachycardia causes further rise of pulmonary venous pressure above 30 mm Hg (plasma oncotic pressure) and significant symptoms of pulmonary edema.

Dynamic Auscultation

- Any maneuver like, which increases heart rate, will increase the intensity of murmur. These maneuvers include few sit-ups, deep coughs, squatting equivalent, etc.
- Inspiration does not affect much, but expiration by increasing venous return to left-sided chamber increases mitral stenosis murmur.
- Amyl nitrate inhalation, by inducing reflex tachycardia, increases the intensity of mitral stenosis murmur. It helps in differentiating mitral stenosis murmur with Austin-Flint murmur.

JAYPEE BROTHERS

DIAGNOSTIC EVALUATION

Electrocardiogram

Vide Chapter 42.

X-ray of Chest

Vide Chapter 45.

Echocardiography

Vide Chapter 51.

Hemodynamic Study

Vide Chapter 62.

NATURAL HISTORY

As mentioned earlier, disease progression is rapid in area, where rheumatic fever is endemic. Average rate of reduction of MVA is 0.09 cm^2/year whereas in rapidly progressing area, it is 0.1–0.3 cm^2/year.[27] About 80% of patient with a Wilkins score >8 showed a progressive reduction of valve area, in compare to only 5% of patients with a score <8.

Factors, which determine the disease progression from initial rheumatic carditis to rheumatic heart disease, are:[28]

- Severity of initial carditis
- Recurrence
- Mother's education level

In Row's series[29] of unoperated patient, total mortality at 10 years was 39% whereas mortality in class III and class IV patients were 85% and 100%, respectively. Overall, 20-years mortality are around 80%. Mode of death in 61% cases is congestive heart failure and in 19% cases are thromboembolic events. In asymptomatic patients, survival at the end of 20 years is >80%. In another series[30] of Olesen, in symptomatic patients, 70% patients were dead by 10 years (**Table 5**).[31]

TABLE 5: Functional class and survival.[31]

Functional class	10-year survival (%)
Class I	84
Class II	34–42
Class III	40
Class IV	0
At 1 year	42
At 5 years	10

MEDICAL MANAGEMENT

Pulmonary Venous Congestion

Diuretics, which will work by reducing the preload, may help to reduce dyspnea. Beta-blockers and nondihydropyridine calcium channel blocker (CCB), which work by producing bradycardia and prolongation of diastolic filling period, may be used. Those molecules, however, do not have any beneficial effect on treadmill exercise time, aerobic capacity, and ventilatory performance. This may be due to blunted effect of beta-blocker on cardiac output.

Hemoptysis

- Upright posture
- Sedation
- Diuresis

Atrial Fibrillation

Rate control can be achieved by intravenous beta-blockers or nondihydropyridine CCB. When those agents cannot control ventricular rate, digoxin or amiodarone can be added. Anticoagulant should be started immediately in the form of intravenous heparin and concomitant oral warfarin. Electrical cardioversion and drugs can achieve sinus rhythm. At least, one trial always may be given for cardioversion. However, recurrent trial of cardioversion, when sinus rhythm cannot be maintained, should be avoided, as it increases the chance of embolic event. In severe mitral stenosis, cardioversion should be deferred till intervention because chance of cardioversion is minimal. When AF is suspected having for >24 hours, patient should be anticoagulated for 3 weeks before any attempt for cardioversion. Otherwise, transesophageal echocardiography (TEE) can be done under coverage of optimum anticoagulation by heparin and cardioversion, if left atrial clot is not found. Rate control in chronic AF can be achieved by combination of digoxin, along with beta-blocker or nondihydropyridine CCB. As such, in chronic AF, a resting heart rate 80 beats/minute and moderate-exercise heart rate <100 beats/minute are recommended as per guidelines. However,

JAYPEE BROTHERS

in presence of mitral stenosis, resting heart rate should be kept controlled at 60 beats/minute.

Maze procedure can be done for AF, when operated for mitral valve replacement (MVR) or repair. Balloon mitral valvuloplasty at optimum time may prevent development of AF.

ANTICOAGULANT PROTOCOL[32,33]

In many of the cases, anticoagulant medication is indicated to prevent thromboembolic event (**Box 6**). International normalized ratio (INR) should be maintained between 2 and 3. Newer oral anticoagulants are not recommended. Low-dose aspirin (81 mg) can be added to anticoagulant to further lower the risk of embolic event.

INTERVENTION

In most of the patients with mitral stenosis, mechanical intervention is eventually needed (**Boxes 7** and **8**). The mechanical interventions available are:

- Balloon mitral valvotomy (BMV)
- Closed mitral commissurotomy (CMC)
- Open mitral commissurotomy (OMC)
- Mitral valve replacement (MVR)

FOLLOW-UP PROTOCOL

In significant mitral stenosis without symptom, when planned not to intervene, follow-up should be done frequently and serial echocardiography should be done yearly. In mild-to-moderate mitral stenosis, serial echo may be done at 2–3 years interval.

BOX 6 **Indications of anticoagulant**

- Patients with atrial fibrillation (AF) or history of AF
- Left atrial clot
- History of any embolic event
- Left atrial diameter >55 mm
- Spontaneous echo contrast in left atrium

BOX 7 **Indications to mechanical intervention: symptomatic.[32,33]**

- MVA <1.5 cm^2, class I, II, III, or IV
- MVA >1.5 cm^2, class I, II, III, or IV and PASP >60 mm Hg, PCWP >25 mm Hg, or mean mitral valve gradient >15 mm Hg on exercise

(MVA: mitral valve area; PASP: pulmonary artery systolic pressure; PCWP: pulmonary capillary wedge pressure)

BOX 8 **Indications to mechanical intervention: asymptomatic.[32,33]**

- MVA <1 cm^2
- MVA <1.5 cm^2, recent or paroxysmal AF
- MVA <1.5 cm^2, previous history of embolism
- Dense echo contrast in left atrium
- PASP >50 mm Hg at rest
- Major noncardiac surgery
- Woman patient planning for pregnancy

(AF: atrial fibrillation; MVA: mitral valve area; PASP: pulmonary artery systolic pressure)

BALLOON MITRAL VALVOTOMY

Balloon mitral valvotomy (BMV) is a less morbid procedure. Besides, a delayed approach may increase the probability of development of persistent AF and higher periprocedural morbidity. Thus, one should intervene before patient passes in class III symptoms or develops pulmonary hypertension. BMV can be done safely, when mitral leaflets are pliable and subvalvular fusion is not severe. There should not be any significant mitral regurgitation or left atrial clot attached to septum, closed to mitral orifice.

Being a safe procedure, BMV is a worthy attempt in most of the cases. Reuse of the balloon in the developing country has made the procedure reasonably cost-effective. It may be attempted in presence of:

- Mild mitral regurgitation
- Organized clot in left atrium.
- Suboptimum morphologies, with significant comorbid diseases precluding surgical intervention.
- Pregnancy

Antegrade Inoue technique is the present procedure of choice, first described by Kanji Inoue. Previous double balloon and retrograde techniques are uncommonly used. Balloon dilatation acts by separation of the fused commissure and fracture of the calcified tissue. Desired endpoint of BMV procedure is:[34]

- MVA >1 cm^2/m^2 of body surface area.
- Complete opening of at least one commissure.
- Appearance or increment of mitral regurgitation more than a grade I classification in a four-grade classification.

JAYPEE BROTHERS

BOX 9 Contraindications for BMV.[31-33]

- MVA >1.5 cm^2
- More than mild MR
- Persistent, floating left atrial clot
- Extensive subvalvular disease
- Absence of commissural fusion
- Bilateral calcific commissural fusion
- Severe calcification
- Severe concomitant aortic valve disease
- Sever concomitant combined tricuspid stenosis and regurgitation

(BMV: balloon mitral valvotomy; MR: mitral regurgitation; MVA: mitral valve area)

Optimal result of BMV is defined as[35] MVA >1.5 cm^2 and regurgitation not more than grade II (**Box 9**). Procedural failure is in 1–17% cases and mortality is in 0–3% cases.[34,35] Complications include hemopericardium in 0.5–12% cases, embolism in 0.5–5% cases, and severe mitral regurgitation in 2–19% cases.[36] Leaflet tearing and chordal rupture are the mechanism of severe mitral regurgitation.

Immediate Results of Balloon Mitral Valvotomy (Tables 6 to 8)

In all large series,[37] immediate results are excellent (**Box 10**). MVA is increased up to 0.6–1 cm^2. Mean gradient reduction is around 50–80%. Pulmonary arterial pressure comes down and cardiac index may increase up to 20%.

Long-term Outcome of Balloon Mitral Valvotomy

Long-term result after BMV is reasonably good. In one of largest series of follow-up, BMV is described in **Table 9**.[38,39]

In another longer 20 years follow-up series,[40] 30% still had good functional result.

Mitral Restenosis after Balloon Mitral Valvotomy

Its incidence varies grossly in different reports from 2 to 40%[41] in duration of 10 years follow-up. Reappearance of symptoms after BMV do not indicate always restenosis and may be due to residual stenosis, progressive mitral regurgitation or aortic valve (AV) disease, and recurrence of

TABLE 6: Immediate results of BMV: Inoue versus Hung (patient profile).[38]

Patient data	Hung	Inoue
Number	572	981
Sex: F/M	71%/29%	74%/26%
AF	71%	74%
MR	24%	26%
Embolism history	11%	19%
Post-CMC	2%	12%

(AF: atrial fibrillation; BMV: balloon mitral valvotomy; CMC: closed mitral commissurotomy; MR: mitral regurgitation)

TABLE 7: Immediate results of BMV: Inoue versus Hung (hemodynamic profile).

Hemodynamics	Hung	Inoue
MV gradient (mm Hg): Before/After	13.0/5.7	11.7/5.6
MVA (cm^2): Before/After	1.0/2.0	1.1/1.9
Cardiac index: Before/After	4.4/4.7	4.0/4.4

(BMV: balloon mitral valvotomy; MVA: mitral valve area)

TABLE 8: Immediate results of BMV: Hung versus Inoue.

Complications	Hung	Inoue
MR: Increase/Severe	29.9%/5.2%	19.1%/2.5%
Tamponade	0.2%	1.1%
Embolic event	2.1%	0.3%
ASD	10.2%	11%
Mortality	0.2%	0.0%

(ASD: atrial septal defect; BMV: balloon mitral valvotomy; MR: mitral regurgitation)

BOX 10 Factors affecting immediate result.

- Age
- Pliability of AML
- Degree of subvalvular fusion
- Calcium burden
- Degree of commissural thickening
- Pre-existing grade of MR
- Prior CMC
- Presence of AF

(AF: atrial fibrillation; AML: anterior mitral leaflet; CMC: closed mitral commissurotomy; MR: mitral regurgitation)

JAYPEE BROTHERS

TABLE 9: Long-term follow-up after balloon mitral valvotomy (BMV).

Total patients	Average follow-up	Age at the time of BMV	Symptomatic improvement persists in	Restenosis
4,832	32 months	37 years	98% cases	5.2% cases

rheumatic carditis. Restenosis is defined as a loss of >50% of initial gain along with MVA <1.5 cm^2. BMV is a worthy trial after mitral restenosis, only when:

- Patient is symptomatic
- Restenosis develops after several years.
- Commissural fusion is the mechanism of restenosis.

Thromboembolism and Atrial Fibrillation after Balloon Mitral Valvotomy

Balloon mitral valvotomy favorably reduces the markers of thromboembolism, like density of left atrial spontaneous echo contrast, left atrial size and function. May be those factors reducing the incidence of thromboembolic complications after BMV in compare to medical management alone. However, BMV does not reduce the incidence of AF.

Predictive Score for Long-term Result (Table 10)[42]

Long-term result after optimum BMV is predictable by a scoring system. Most important factors are age, grade of calcification, and gradient across MV after BMV. Optimum result means MVA >1.5 cm^2 and mitral regurgitation less than grade II.

In this 13-point scoring system, three risk groups can be defined: (1) Low-risk group (0–2), (2) Intermediate-risk group (3–5), and (3) High-risk group (>6).

TABLE 10: Prediction score.[42]

Predictive factors	Score
Age (years) and post-MVA (cm^2)	
• <50 and >MVA 2	0
• <50 and MVA 1.5–2	2
• 50–70 and MVA > 1.75	5
• >70 and MVA > 1.5	
Valve anatomy and sex	
• No calcification	0
• Calcification: Male	3
• Calcification: Female	0
Rhythm and NYHA class	
• Sinus rhythm or AF and I-II	0
• AF and III-IV	2
Post-BMV mean gradient/mm Hg	
• <3	0
• 3–6	1
• >6	3

(AF: atrial fibrillation; BMV: balloon mitral valvotomy; MVA: mitral valve area; NYHA: New York Heart Association)

CLOSED MITRAL COMMISSUROTOMY

Closed mitral commissurotomy was the most common procedure for mitral stenosis, prior to BMV. CMC had an operative mortality averaging 1–2%.[43] Reoperation was required in 76% cases within 20 years after CMC.

OPEN MITRAL COMMISSUROTOMY

In one of the largest series[44] of 1,280 patients with mitral stenosis undergoing open-heart surgery, OMC was done in 276 (21.6%) patients. The procedure includes splitting the commissure, incising the fused chordae and papillary muscle, calcium debridement, and repairing mild-to-moderate mitral regurgitation, if any. In that series, there were four early deaths and three reoperations to combat severe mitral regurgitation. There was no late death. Freedom from MV failure at 10 years was 87%.

MITRAL VALVE REPLACEMENT

Most data are on the MVR for mixed MV disease. Operative mortality is between 2 and 7%.[45] Prosthesis-related mortality is 2.5% per year and prosthesis-related complications are 5% per year. Usually, Wilkins score >12 indicates the valve is not suitable for valvuloplasty. However, focus of attention should be to following specific factors (**Box 11**), rather than an overall scoring for a decision for valve replacement, rather than BMV.

A large prospective survey showed that BMV is used in more than one-third cases. In remaining

JAYPEE BROTHERS

BOX 11 Nonsuitability for BMV.

- Grossly calcified valve apparatus and bicommissural calcification
- Severe subvalvular fusion
- Nonpliable mitral leaflets
- More than mild-to-moderate MR
- Left atrial (nonorganized) clot
- Associated severe aortic valve disease
- Concomitant combined tricuspid stenosis and regurgitation

(BMV: balloon mitral valvotomy; MR: mitral regurgitation)

cases, valve replacement is done.[46] CMC and OMC have been replaced by these two procedures.

Management of mitral stenosis can be outline in the following **Flowchart 1**.

JUVENILE MITRAL STENOSIS

Sujoy B Roy presented juvenile mitral stenosis in India at the 7th International Congress on Diseases of the Chest, held in New Delhi, February, 1963. He presented the data of 108 patients below the age of 20 years with pure rheumatic mitral stenosis. The series showed male dominance—there were 66 boys and 42 girls.

History of one attack of rheumatic fever was present in 66% of patients and more than one episode in another 28% of patients. The interval between first attack of rheumatic fever and onset of symptoms was 5 years in 70% among patients in whom the history of rheumatic fever was present.

Exertional dyspnea was the most common symptom found in 78% of patients. Heart failure was present in 45% of patients. Angina was not very uncommon in 12% of patients. Angina was suggested due to functional impairment of the coronary flow caused by limitation of the cardiac output. There were patients with dusky appearance due to pallor and mild cyanosis. They were described as mitral stenosis with "fragile" look.

Valve calcification was rare and found only in one patient during surgery. Similarly, left atrial thrombus was found in one patient.

The prevalence of significant pulmonary hypertension was very high, almost in two-thirds of patients. The gross pulmonary vascular change was suggested due to hypersensitive reaction of the pulmonary vasculature to a fulminating rheumatic process.

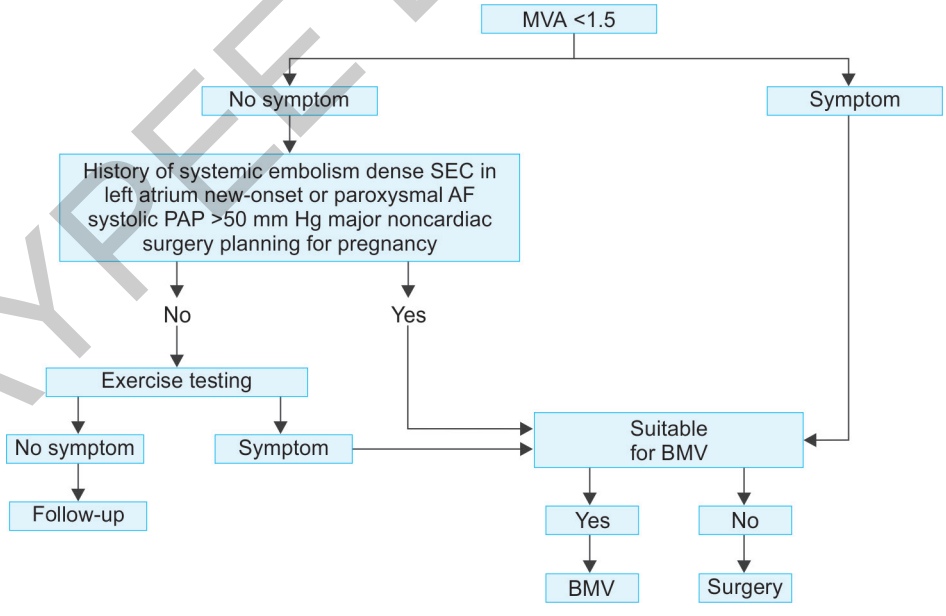

(AF: atrial fibrillation; BMV: balloon mitral valvotomy; MS: mitral stenosis; MVA: mitral valve area; PAP: pulmonary artery pressure; SEC: spontaneous echo contrast)

Flowchart 1: Comprehensive management approach for MS.

JAYPEE BROTHERS

CONCLUSION

Mitral stenosis is still a clinical disease, which can be diagnosed and severity is assessed by clinical examination. For confirmation and decision-making, a simple imaging like echocardiogram is good enough. Pulmonary edema, AF, and thrombo-embolic stroke are the major complications. Clinically and hemodynamically, critical valve area is 1 cm^2. However, valve area of 1.5 cm^2 is now the cutoff level for mechanical intervention.

REFERENCES

1. Lung B, Vahanian A. Epidemiology of valvular heart disease in the adult. Nat Rev Cardiol. 2011;8:162-72.
2. Chambers JB, Bridgewater B. Epidemiology of valvular heart disease. In: Otto CM, Bonow RO (Eds). Valvular Heart Disease: A Companion to Braunwald's Heart Disease, 4th edition. Philadelphia: Saunders; 2013. pp. 1-13.
3. Marijon E, Ou P, Celermajer DS, Ferreira B, Mocumbi AO, Jani D, et al. Prevalence of rheumatic heart disease detected by echocardiographic screening. N Engl J Med. 2007;35:470-6.
4. Wood P. An appreciation of mitral stenosis I-Clinical features. Br Med J. 1954;1:1051-63.
5. Manjunath CN, Srinivas P, Dhanalakshmi C. Incidence and pattern of valvular heart disease in a tertiary care high-volume center: a single-center experience. Indian Heart J. 2014;66:320-6.
6. Selzar A, Cohn KE. Natural history of mitral stenosis: a review. Circulation. 1972;45:878-90.
7. Carroll JD, Feldman T. Percutaneous mitral balloon valvotomy and the new demographics of mitral stenosis. JAMA. 1993;270:1731-6.
8. Joswig BC, Glover MU, Handler JB, Warren SE, Vieweg WV. Contrasting progression of mitral stenosis in Malayans versus American-born Caucasians. Am Heart J. 1982;104:1400-3.
9. Davies LG, Goodwin JF, and van Leuven BD. The nature of pulmonary hypertension in mitral stenosis. Br Heart J. 1954; 16: 440-446.
10. Gorlin R. The mechanism of the signs and symptoms of mitral valve disease. Br Heart J. 1954;16:375-80.
11. Horstkotte D. Arrhythmias in the natural history of mitral stenosis. Acta Cardiol. 1992;47:105-13.
12. Vigna C, de Rito V, Criconia GM, Russo A, Testa M, Fanelli R, et al. Left atrial thrombus and spontaneous echo-contrast in nonanticoagulated mitral stenosis. A transesophageal echocardiographic study. Chest. 1993;103:348-52.
13. Peverill RE, Harper RW, Gelman J, Gan TE, Harris G, Smolich JJ. Determinants of increased regional left atrial coagulation activity in patients with mitral stenosis. Circulation. 1996;94:331-9.
14. Marin F, Roldan V, Monmeneu JV, Bodí V, Fernández C, de Burgos FG, et al. Prothrombotic state and elevated levels of plasminogen activator inhibitor-1 in mitral stenosis with and without atrial fibrillation. Am J Cardiol. 1999;84:862-4.
15. Scarlat A, Bodner G, Liron M. Massive hemoptysis as the presenting symptoms in mitral stenosis. Thorax. 1986;41: 413-4.
16. Delman AJ, Gordon GM, Stein E, Escher DJ. The Second Sound-Mitral Opening Snap (A2-OS) Interval during Exercise in the Evaluation of Mitral Stenosis. Circulation. 1966;33:399-403.
17. Mounsey P. The opening snap of mitral stenosis. Br Heart J. 1953;15:135-42.
18. Nixon PG, Wooler GH, Radigan LR. The opening snap in mitral incompetence. Br Heart J. 1960;22:395-402.
19. Neill C, Mounsey P. Auscultation in patent ductus arteriosus. Br Heart J. 1958;20:61-75.
20. Millward DK, McLaurin LP, Craige E. Echocardiographic studies to explain opening snaps in presence of nonstenotic mitral valves. Am J Cardiol. 1973;31:64-70.
21. Davies JP. A simple phonocardiographic formula for predicting left atrial pressure in mitral stenosis. Br Heart J. 1967;29:843-51.
22. Toutouzas P, Koidakis A, Velimezis A, Avgoustakis D. Mechanism of diastolic rumble and presystolic murmur in mitral stenosis. Br Heart J. 1974;36:1096-105.
23. Levines A, Love DE. Mitral stenosis without murmurs. Cardiologia. 1952;21:599-611.
24. Criley JM, Hermer AJ. The crescendo presystolic murmur of mitral stenosis with atrial fibrillation. N Engl J Med. 1971;285:1284-7.
25. Fortuin NJ, Craige E. Echocardiographic studies of genesis of mitral diastolic murmurs. Br Heart J. 1973;35:75-81.
26. Travel ME, Bonner AJ. Presystolic murmur in atrial fibrillation: fact or fiction? Circulation. 1976;54:167-8.
27. Sagie A, Freitas N, Padial LR, Leavitt M, Morris E, Weyman AE, et al. Doppler echocardiographic assessment of long-term progression of mitral stenosis in 103 patients: valve area and right heart disease. J Am Coll Cardiol. 1996;28:472-9.
28. Gordon SP, Douglas PS, Come PC, Manning WJ. Two-dimensional and Doppler echocardiographic determinants of the natural history of mitral valve narrowing in patients with rheumatic mitral stenosis: implications for follow-up. J Am Coll Cardiol. 1992;19:968-73.
29. Rowe JC, Bland EF, Sprague HB, White PD. The course of mitral stenosis without surgery: ten- and twenty-year perspectives. Ann Intern Med. 1960;52:741-9.
30. Olesen KH. The natural history of 271 patients with mitral stenosis under medical treatment. Br Heart J. 1962;24: 349-57.
31. Kawanishi DT, Rahimtoola SH. Mitral stenosis. In: Rahimtoola SH (Ed). Atlas of Heart Disease: Valvular Heart Disease. St. Louis: Mosby; 1997.
32. Nishimura RA, Otto CM, Bonow RO, Carabello BA, Erwin JP, Guyton RA, et al. 2014 AHA/ACC guideline for the management of patients with valvular heart disease: A report of the American College of Cardiology/American Heart Association Task Force on Practice Guidelines. J Am Coll Cardiol. 2014;63:e57-185.
33. Joint Task Force on the Management of Valvular Heart Disease of the European Society of Cardiology (ESC), European Association for Cardio-Thoracic Surgery (EACTS), Vahanian A, Alfieri O, Andreotti F, Antunes MJ, et al. Guidelines on the management of valvular heart disease (version 2012). Eur Heart J. 2012;33:2451-96.

JAYPEE BROTHERS

34. Vahanian A, Cormier B, Iung B. Mitral valvuloplasty. In: Topol EJ (Ed). Textbook of Interventional Cardiology, 5th edition. Philadelphia: Saunders/Elsevier; 2008. pp. 879-93.
35. Marijon E, Iung B, Mocumbi AO, Kamblock J, Thanh CV, Gamra H, et al. What are the differences in presentation of candidates for percutaneous mitral commissurotomy across the world and do they influence the results of the procedure? Arch Cardiovasc Dis. 2008;101:611-7.
36. Fawzy ME, Shoukri M, Al Buraiki J, Hassan W, El Widaal H, Kharabsheh S, et al. Seventeen years' clinical and echocardiographic follow up of mitral balloon valvuloplasty in 520 patients, and predictors of long-term outcome. J Heart Valve Dis. 2007;16:454-60.
37. Kang DH, Park SW, Song JK, Kim HS, Hong MK, Kim JJ, et al. Long-term clinical and echocardiographic outcome of percutaneous mitral valvuloplasty: randomized comparison of Inoue and double-balloon techniques. J Am Coll Cardiol. 2000;35:169-75.
38. Inou K, Hung JS. Percutaneous transvenous mitral commissurotomy (PTMC): the far east experiences. In: Topol EJ (Ed). Textbook of Interventional Cardiology, 2nd edition. Philadelphia: Saunders Elsevier; 1994. pp. 1226-42.
39. Hung JS, Chern MS, Wu JJ, Fu M, Yeh KH, Wu YC, et al. Short and long-term results of catheter balloon percutaneous transvenous mitral commissurotomy. Am J Cardiol. 1999;67:854-62.
40. Chen CR, Chen TO. Percutaneous balloon mitral valvuloplasty by the Inoue technique: a multicenter study of 4832 patients in China. Am Heart J. 1995;129:1197-203.
41. Song JK, Song JM, Kang DH, Yun SC, Park DW, Lee SW, et al. Restenosis and adverse clinical events after successful percutaneous mitral valvuloplasty: immediate post-procedural mitral valve area as an important prognosticator. Eur Heart J. 2009;30:1254-62.
42. Bouleti C, Iung B, Laouénan C, Himbert D, Brochet E, Zeitoun DM, et al. Late results of percutaneous mitral commissurotomy up to 20 years: development and validation of a risk score predicting late functional results from a series of 912 patients. Circulation. 2012;125:2119-27.
43. Detter C, Fischlein T, Feldmeier C, Nollert G, Reichenspurner H, Reichart B. Mitral commissurotomy, a technique outdated? Long-term follow-up over a period of 35 years. Ann Thorac Surg. 1999;68:2112-8.
44. Choudhary SK, Dhareshwar J, Govil A, Airan B, Kumar AS. Open mitral commissurotomy in the current era: indications, technique, and results. Ann Thorac Surg. 2003;75:41-6.
45. Hammermeister K, Sethi GK, Henderson WG, Grover FL, Oprian C, Rahimtoola SH. Outcomes 15 years after valve replacement with a mechanical versus a bioprosthetic valve: final report of the Veterans Affairs randomized trial. J Am Coll Cardiol. 2000;36:1152-8.
46. Iung B, Baron G, Butchart EG, Delahaye F, Bärwolf CG, Levang OW, et al. A prospective survey of patients with valvular heart disease in Europe: The Euro Heart Survey on Valvular Heart Disease. Eur Heart J. 2003;24:1231-43.

JAYPEE BROTHERS

etailed information on cardiology books, visit our website www.ejaypee.com, for detailed information on cardiology books, visit our website www.ejaypee.com, for deta

Clinical Cardiology
A Disease Specific Approach

The book *Clinical Cardiology: A Disease Specific Approach* will appeal to a wide audience of students, teachers, practicing physicians, and cardiologists, who are used to seeing patients with cardiac problem.

Key Features

- This book presents a selection of over 14 Sections. Each section contains a clinical theme. Under the umbrella of the theme, there are 78 Chapters, containing specific disease.
- Each chapter describes how to interpret and formulate a bedside diagnosis, how to correlate the clinical formulation with imaging and hemodynamic, and how to outline the management.
- A discussion on basic investigations such as ECG, chest X-ray, and echocardiography has been made precise.
- Cardiac catheterization and hemodynamic data of each disease have been discussed in a very comprehensive and lucid approach.
- More than 370 figures, flowcharts, and numerous tables let the reader refer to key facts quickly.
- This book summarizes a wide breadth of material from basic to clinical science in one convenient volume.

Achyut Sarkar is a Professor of Cardiology and Senior Interventional Cardiologist. He is associated with medical education for over three decades. He is the author of *Bedside Cardiology*, Jaypee Brothers Medical Publishers (P) Ltd. He has edited the West Bengal Chapter in *Update in Cardiology*, 2007 for Cardiological Society of India. He has contributed chapters in *Protocol Book, Current Trends in Cardiology, Nonspecific Aortoarteritis,* and *Tropical Heart Disease in India*. He has several national and international publications to his credit.

Shelving Recommendation
CARDIOLOGY

ISBN 978-93-89776-04-1

9 789389 776041

Buy from ejaypee

JAYPEE BROTHERS