ebrothers.com/ for detailed information on obstetrics & gynecology books, visit our website www.jaypeebrothers.com/ for detailed information on obstetrics & gynecology books

FEDERATION OF OBSTETRIC AND GYNAECOLOGICAL SOCIETIES OF INDIA™
FOGSI

WE FOR स्त्री
Safer • Stronger • Smarter

Celebrating 50 Years
Passion, Quality and Innovation in Healthcare Publishing

FOGSI Focus

Imaging in OBSTETRICS & GYNECOLOGY

Editor-in-Chief
Nandita Palshetkar

Editor
Meenu Agarwal

Co-Editors
Rohan Palshetkar
Chinmay Umarji

Video Legend: Right Sided Ectopic Pregnancy
Description: Uterus is empty and on right side gestational sac is seen with yolk sac within it. Considerable amount of blood present in pouch of Douglas (POD) and anterior to uterus. Although patient was hemodynamically stable, presence of significant amount of blood requires urgent intervention. We did laparoscopic salpingectomy for this patient and it was incomplete tubal abortion.

JAYPEE

Contents

1. Basic Principles of Ultrasound Machine 1
Sonal Panchal, Chaitanya Nagori

- Optimizing B-mode Image *1*
- Optimizing Doppler Image *3*
- Understanding the Artifacts *10*
- Safety of Doppler *11*
- Apart from this a Few Practical Tips on Planning your Setup *11*

2. Stepwise Standardized Approach to Ultrasound Examination of Female Pelvis 13
Sonal Panchal, Chaitanya Nagori

- Method *14*
- Adnexa *17*

3. Three-dimensional/Four-dimensional Ultrasound in Obstetrics: An Entertainment or an Empowerment 19
Sachin Nichite, Pragya Nichite

- Advantages of Three-dimensional/Four-dimensional or Volume Imaging *19*
- Various Modes and Tools Used in Three-dimensional/Four-dimensional Imaging *19*
- Practical Steps for Three-dimensional/Four-dimensional Ultrasound *21*
- Clinical Applications of Three-dimensional/Four-dimensional Ultrasound *22*
- Limitations of Three-dimensional/Four-dimensional Ultrasound *23*

4. Role of Color Flow and Doppler in Gynecology and Infertility 25
Amogh Chimote, Neharika Malhotra, Narendra Malhotra

- What is Color Doppler? *25*
- Variables in Doppler *25*
- Calculations in Doppler *26*
- How the Color Image is Formed? *26*
- Types of Doppler *26*
- Aliasing *26*
- Use of Doppler in Gynecology *27*
- Endometrial Polyp *29*
- Adnexal Ovarian Torsion *30*
- Endometriosis *31*
- Endometrioma *32*
- Peritoneal Endometriosis *32*
- Gestational Trophoblastic Disease *32*
- Gestational Trophoblastic Tumors *33*
- Ectopic Pregnancy *33*
- Scar Ectopic Pregnancy *34*
- Pelvic Congestion Syndrome *34*
- Malignant Uterine Tumors *34*
- Endometritis and Endometrial Carcinoma *34*

ROLE OF COLOR DOPPLER IN INFERTILITY 35

- Study of Menstrual Cycle by Color Doppler *35*
- Changes in the Ovary *35*
- Uterine Perfusion *36*
- Changes in the Endometrium *37*
- Luteal Phase Scan *37*
- Ultrasound Technique for Uterine Biophysical Profile *38*
- Conception Rates with Uterine Scoring System for Reproduction Scores *39*

5. Ultrasound in Infertility: Follicular Dynamics and Endometrium 42
Sonal Panchal, Chaitanya Nagori, Meenu Agarwal
- Baseline Scan and Deciding the Stimulation Protocol *42*
- B-mode Features of a Mature Follicle *43*
- Doppler Features of a Good Preovulatory Follicle *44*
- B-mode Features of Pretrigger Endometrium with Good Receptivity *45*
- Secretory Phase Assessment *47*

6. Imaging in Endometriosis 49
Glossy Sabharwal, Meenu Agarwal, Liselotte Mettler
- Clinical Examination *50*
- Serum Markers *50*
- Diagnostic Imaging Modalities *50*
- Ultrasound Scan *50*
- Magnetic Resonance Imaging *51*
- Computed Tomography Scan *51*
- Laparoscopy and Biopsy with Histological Examination *52*
- Diagnostic Algorithm *52*
- Recent Advanced in the Imaging Techniques for Endometriosis *52*

7. Ultrasound in Gynecology 55
Aarti Deenadayal Tolani, Hema Desai, Mamata Deenadayal
- Requirements *55*
- Techniques *55*
- Settings *56*
- Modalities of Ultrasound *56*
- Congenital Uterine Anomalies *58*
- Morphological Uterus Sonographic Assessment *59*
- International Endometrial Tumor Analysis Group *59*
- Ovaries *62*
- International Ovarian Tumor Analysis Collaboration *64*
- Endometriosis *65*
- Pregnancy *65*
- Torsion *66*
- Reporting Pelvic Ultrasound *66*

8. Ultrasound of Ectopic Pregnancy 67
Punam Dixit, Aashita Shrivastava
- Diagnosis *67*
- Assessment of Adnexa *68*
- Different Morphological Types of Ectopic Pregnancy *68*
- Criteria for Diagnosis of Scar Ectopic *68*

9. Ultrasound of Adnexa 70
Punam Dixit, Jhillmill Kumari
- Common Indications of Ultrasound of Adnexa *70*
- Common Causes of Benign Adnexal Masses *70*
- Solid Masses of Adnexa *72*
- Malignant Adnexal Masses *72*

10. Ultrasonography for Bleeding in Obstetrics 74
PK Shah, Keshav Pai
- Causes of Bleeding in Obstetrics *74*
- Bleeding in Late Pregnancy *78*

11. Ultrasound in First Trimester 82
Archana Baser, Anshu Baser, Varsha Mahajan, Mumtaz P
- Critical Conditions in Early Pregnancy Scan *85*
- Prognostication of Pregnancy *87*

12. Ultrasound and Doppler in Multiple Pregnancy 90
Parth Shah, Jayprakash Shah

- Mechanism of Multifetal Gestation *90*
- Genesis of Monozygotic Twins *91*
- Role of Prenatal Ultrasound in Multifetal Gestation *91*
- Diagnosis of Multiple Gestation *92*
- Gestational Age Assessment in Multifetal Pregnancy *92*
- Determining Chorionicity and Amnionicity in Multifetal Pregnancy *92*
- Labeling of the Fetuses *93*
- Monitoring of the Multifetal Pregnancy *93*
- Screening for Aneuploidy in Multifetal Gestation *94*
- Invasive Prenatal Diagnosis in Multifetal Gestation *94*
- Ultrasound Screening for Structural Anomalies *94*
- Management of Twin Pregnancy Discordant for Fetal Anomaly *94*
- Fetal Reduction/Selective Termination in Multifetal Gestation *95*
- Screening for Risk of Preterm Birth in Multifetal Gestation *95*
- Fetal Growth Restriction *95*
- Managing the Surviving Twin after Demise of its Co-twin *96*
- Complications Specific to Monochorionic Twin Pregnancies *97*
- Conjoined Twins *97*
- Twin Reversed Arterial Perfusion Sequence *98*
- Twin Anemia Polycythemia Sequence *99*
- Twin-Twin Transfusion Syndrome *100*
- Monochorionic Monoamniotic Twins *102*

13. Ultrasound in Second Trimester 104
Chinmayee Ratha

- Scope of the Second Trimester Scan *104*
- Fetal Biometry in the Second Trimester *104*
- Targeted Imaging for Fetal Anomalies *106*
- Placental Localization in the Second Trimester *108*
- Uterine Artery Doppler Studies in the Second Trimester *108*
- Cervical Length Assessment in the Second Trimester *109*

14. Placental Abnormalities 111
Shreyasi Sharma

- Normal Placenta *111*
- Size and Shape Abnormalities *111*
- Extrachorial Placentation *113*
- Abnormalities of Location *113*
- Placenta Accreta Spectrum/Morbidly Adherent Placenta *114*
- Circulatory Disturbances *116*
- Placental Calcification *118*
- Placental Tumors *118*
- Abnormalities of the Umbilical Cord *118*

15. Amniotic Fluid Assessment 124
Seetha Ramamurthy Pal, Kanchan Mukherjee

- Normal Amniotic Fluid Volume *125*
- Oligohydramnios *127*
- Polyhydramnios *128*

16. Ultrasound in Third Trimester 131
Vandana Bansal, Rujul Jhaveri, Neha Singh

- Current Scenario of Obstetric Imaging in India *131*
- Third Trimester Ultrasound as a Diagnostic Tool *132*
- Indications/Components of Ultrasound Examination in Third Trimester *132*
- Imaging Parameters for a Standard Examination in Third Trimester *132*
- Fetal Central Nervous System Abnormalities *139*

- Fetal Genitourinary Anomalies *140*
- Fetal Gastrointestinal Anomalies *140*
- Congenital Lung Malformations *140*
- Cardiac Anomalies *141*
- Fetal Musculoskeletal Abnormalities *142*
- Intrapartum Ultrasonography *142*

17. Fetal Intervention 144
Vandana Bansal

- Genetic Counseling *144*
- Invasive Prenatal Diagnosis *145*
- Indications for Amniocentesis or Chorionic Villus Sampling *145*
- Amniocentesis *146*
- Chorionic Villus Sampling *147*
- Fetal Blood Sampling *148*
- Fetal Therapy and its Principles *149*

18. Gastrointestinal Tract Anomalies 156
Parul Choudhary Vali, Jayprakash Shah

- Esophageal Atresia *156*
- Duodenal Atresia *158*
- Small Bowel Atresia *159*
- Meconium Ileus *160*
- Meconium Peritonitis *161*
- Anal Atresia and Anorectal Malformations *161*
- Agenesis of Ductus Venosus *162*
- Persistent Right Umbilical Vein *163*
- Enteric Duplication Cyst *163*
- Mesenteric Cyst *164*
- Meconium Pseudocyst *164*
- Hepatic Cyst *164*
- Splenic Cyst *164*
- Choledochal Cyst *164*
- Echogenic Bowel *164*

19. Imaging in Labor 167
Girija Wagh, Rohan Wagh, Mahima Arya

- Imaging in Morbidly Adherent Placenta and Placental Abruption *167*
- Assessment of Fetal Well-being *168*
- Assessment of the Progress of Labor *170*
- Case Scenario *173*

20. Role of MRI in Pregnancy 175
Neeta Singh, Mandakini Pradhan

- Indications of MRI *175*
- Safety of MRI in Pregnancy *176*
- Advantages *176*

21. Genetic Markers in Aneuploidies 177
Ashok Khurana

- Sonographic Markers for Down Syndrome (Trisomy 21) *178*
- Sensitivity of Marker Detection *179*
- Significance of Individual Markers *179*
- Trisomy 18 (Edwards' Syndrome) *180*
- Trisomy 13 (Patau Syndrome) *180*
- Turner Syndrome (Xo) *180*
- Triploidy *180*
- Genetic Sonography after First Trimester Screening *181*

22. Fetal Medicine Beyond Ultrasound 184
Pramod Vasantrao Patil
- Role of Fetal Medicine Specialist *184*

23. Pre-conception and Pre-natal Diagnostic Techniques: How to Comply with the Law? 186
Hitesh J Bhatt
- Do's in Pre-conception and Pre-natal Diagnostic Techniques Act *186*
- Don'ts in Pre-conception and Pre-natal Diagnostic Techniques Act *187*

24. Writing an Ultrasound Report 189
Chinmay Umarji
- Aids to the Report Writing *189*
- Attributes of the Report Writing *189*
- Clinical Content of Report Writing *190*
- Report Storage *191*

25. Training in Ultrasound in Obstetrics and Gynecology 193
S Suresh, Indrani Suresh
- Certification *194*
- Logbook *195*
- Training for Rural India *195*
- Training of Practitioners *195*

Index 197

2

Stepwise Standardized Approach to Ultrasound Examination of Female Pelvis

Sonal Panchal, Chaitanya Nagori

INTRODUCTION

Sonography is one of the most useful and indispensable investigations for the assessment of the female pelvis.

Pelvic organs can be scanned by:

- Transabdominal route
- Transvaginal route
- Transrectal route

The scan for pelvic organs must start as abdominal scan. Assessment of the kidneys is especially important in cases with Müllerian duct abnormalities. Moreover, an abdominal approach to the pelvic organs gives an overall idea about the pelvic organs and surrounding anatomy before the detailed study of uterus and ovaries individually. Though in those patients in whom transvaginal approach is not possible, transabdominal route may be the first option. This scan is done on full bladder.

Low ultrasound frequencies are preferred, 3–5 MHz probe, to allow visualization of the uterus and ovaries from the acoustic window of full bladder (Figs. 1 and 2). Patient is placed in supine position and is asked to relax and not to blow up her abdomen. At times, pressure with the probe may be required and probe may have to be angulated toward the pelvic cavity.

Sonography of the pelvic organs—uterus, ovaries, and adnexa is preferred by transvaginal route for better visibility and accuracy of diagnosis. This advantage is because of close placement of the probe. Because of less distance that the sound waves have to travel, these probes are high frequency (6–12 MHz) and so give better resolution. Transvaginal route cannot be used in virgins or in cases of local vaginal problems where transabdominal sonography with full bladder may be done. This route has a disadvantage of poor resolution because of the

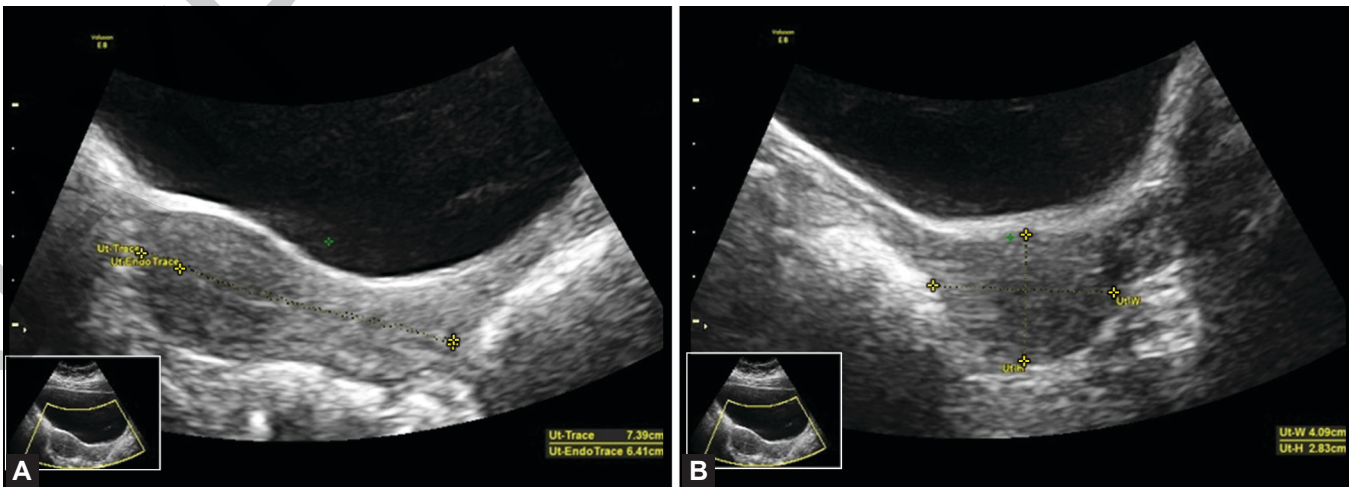

Figs. 1A and B: Uterus on longitudinal and transverse section on transabdominal scan.

JAYPEE BROTHERS

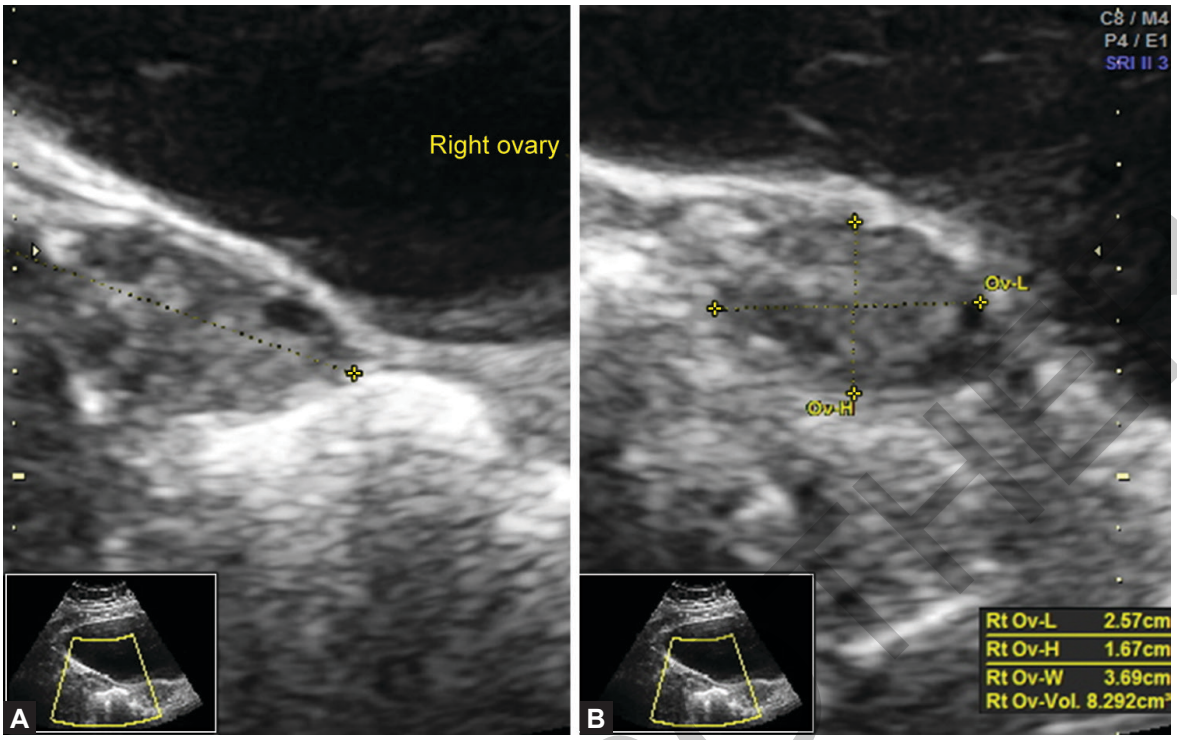

Figs. 2A and B: Right ovary in longitudinal and transverse section on transabdominal scan.

distance of the pelvic organs from the probe, maternal fat, maternal bowel loops, and the low frequency (3–5 MHz) probe which has evidently lower resolution than the high resolution, high frequency transvaginal probe.

Approximately 42% of ovarian details are missed by transabdominal scan.[1] But transrectal sonography in such cases is more preferable and informative as compared to transabdominal approach. The probe used is transvaginal probe so resolution is very similar to that of a transvaginal examination, but rectal placement is much more painful than transvaginal placement. Therefore, the approach of choice is transvaginal.

METHOD

Patient is first asked to empty the bladder. Patient is placed in lithotomy position on the gyne couch in the same way as for per speculum or per vaginal examination. Ultrasound jelly is put on the head of the transvaginal probe and then the probe is covered with the condom, not to allow any air between the probe and the condom. A small amount of jelly is then placed over the condom on the probe head and the probe is gently slided into the patient's vagina. In case of difficulty in introduction or patient's resistance to introduction, she is advised to take deep long breaths with open mouth, i.e., deep inspirations and long complete expirations. Counseling the patient before examination and explaining the whole procedure and adequate privacy

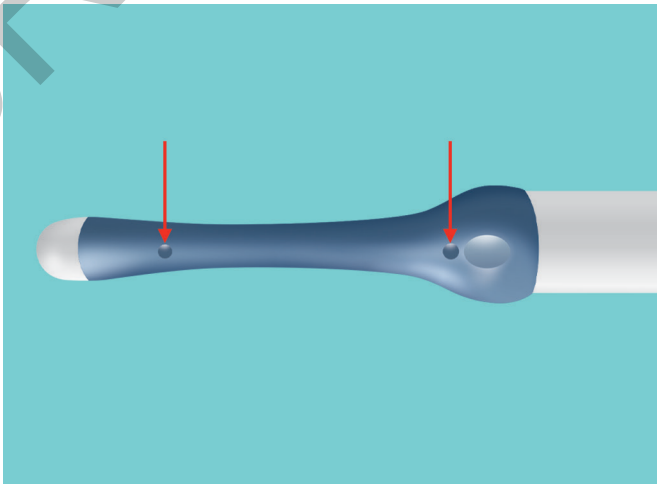

Fig. 3: The arrows showing the markers on the transvaginal probe.

help eliminate the anxiety and resistance. In spite of that if introduction of probe needs any force, the pressure should be exerted posteriorly toward the rectum which will make introduction of the probe into the vagina easier. Probe is held in the position, so that the markers on the probe face the roof of the examination room and it is introduced into patient's vagina in the same position (Fig. 3).

This indicator of the probe also matches the logo on the screen. This means that if the indicator on the screen is on the left side of the screen, the structures anteriorly placed are on the left side of the screen.

JAYPEE BROTHERS

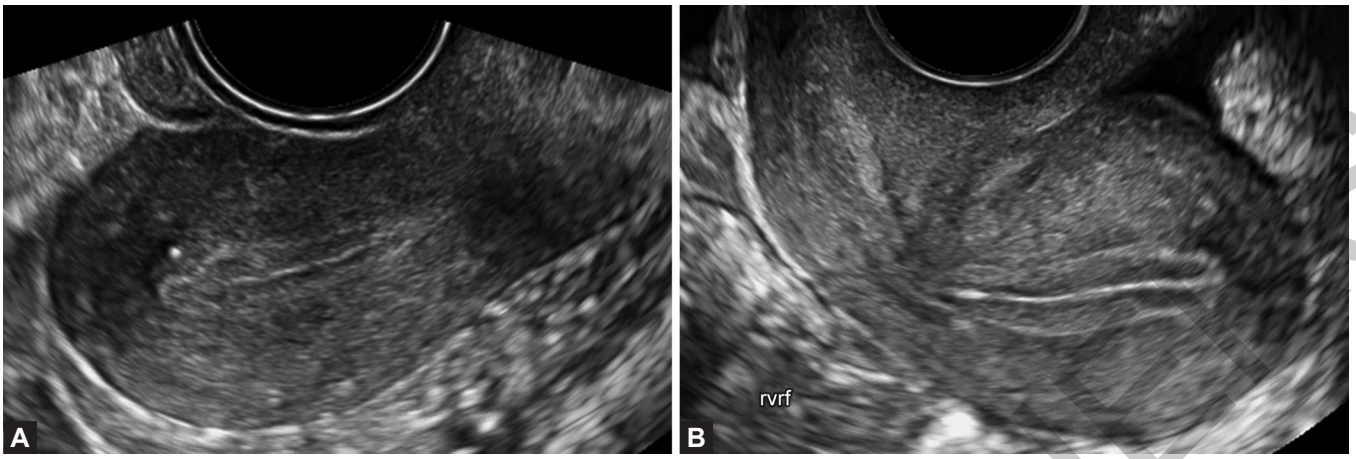

Figs. 4A and B: (A) Anteverted anteflexed uterus on B-mode ultrasound; and (B) Retroverted retroflexed (rvrf) uterus on B-mode ultrasound.



Figs. 5A to C: (A) Thin endometrium of early proliferative phase; (B) Multilayered endometrium of midcycle; and (C) Hyperechoic endometrium of secretory phase.

This longitudinal axis of the patient normally corresponds to the long axis of the uterus. That means the uterus must be seen in the long axis in this view. It may be anteverted or retroverted. When anteverted, the uterine fundus will be directed toward the indicator on the screen and urinary bladder is also seen on the same side of the screen, when retroverted fundus will be on the opposite side of the indicator and the urinary bladder (Figs. 4A and B).

If the uterus is not seen in this view, it means that the uterus is deviated toward one side. When it is deviated, it would indicate that either it is pulled on the side of the pathology like adhesions or is pushed away by the pathology which is on the opposite side say a mass. The second possibility is an abnormality of the uterus itself, most likely Müllerian duct abnormalities, such as hemiuterus or bicorporeal uterus.

Having located the uterus in the midline and decided whether it is anteverted or retroverted, its structure is evaluated as:

- *Endometrium*:
  - Corresponding with the phase of the cycle
  - Symmetry of the endometrium
  - Intraendometrial lesions such as polyp, adhesions, etc.
  - Endometrio-myometrial junction

Depending on the phase of the cycle, endometrium is expected to be thin linear in early follicular phase, triple line in preovulatory phase, and thick and echogenic in secretory phase (Figs. 5A to C). It is broadest at the fundus and narrows down smoothly toward cervix. In all the phases, there is a thin hypoechoic zone seen surrounding the echogenic outline of endometrium, which is known as endometrio-myometrial junction or junctional zone (Fig. 6). Breach in this zone is suggestive of a pathological endometrium, either infection or neoplasm. Any echogenic solid lesion in between the lines of endometrium is suggestive of pathologies such as polyps, synechiae, etc.

- *Myometrium*:
  - Homogenicity of the myometrium
  - Mass lesions
  - Scar tissues

  Myometrium is homogeneously echogenic normally (Fig. 6). Any generalized heterogenicity or localized hypo-/hyperechogenicity is suggestive of pathology.
- *Serosa*:
  - Continuity
  - Smoothness of contour
  - Maintenance of tissue interface

JAYPEE BROTHERS

Outer layer of uterus is covered by peritoneum and the serosal layer (Fig. 6). It defines the margins of uterus and therefore its integrity confirms that the uterus is normal. Any mass lesion in the uterus changes the contour of the uterus and therefore the smooth pear shape is distorted.

- *Cervix*:
  - *Length, mucous*: The cervical length is assessed by identifying the internal os. Internal os can be identified by two landmarks: (1) The entry of uterine vessels on transverse section, and (2) Cervical glands surrounding the cervical canal in midsagittal section (Fig. 7). Thickness of endometrio-myometrial junction is narrowest at the internal os and beyond that toward cervix, thick hypo-/hyperechoic band is seen because of cervical glands.
  - Cervical lesions, polyp, etc.
  - Serosal integrity as for the body of the uterus is also essential for the cervix.

Physiological uterocervical length also is measured in this view. It can be measured as a continuous tracing from the fundal endometrial tip to the external os, or it can be a summation of three measurements (Figs. 8A and B): (1) Fundus serosa to endometrium (myometrial length), (2) Endometrium to internal os (endometrial length), and (3) Internal os to external os (cervical length). This is uterocervical length that must be used for intrauterine insemination (IUI) and embryo transfer. The actual anatomical uterocervical length can be measured from the fundal serosa to the external os.

Now rotate the probe 90° anticlockwise. This maneuver will give transverse view of the uterus with the right side of the patient on right side of the screen (Fig. 9). In this transverse position also, the whole uterus is evaluated from the fundus to the cervix by sliding the probe up and down in the vagina. This survey should give a complete idea about the anatomy of the uterus and the exact location of any fibroids, etc.

Now deviate the probe toward right side and in transverse position at the level of uterine cornu, gradually look at the adnexal soft tissue band and follow it to the ovary. Extend the movement up to the lateral pelvic wall if ovary is not located. If the ovary is not located, the probe is moved up and down and is simultaneously moved from lateral pelvic wall to medially, to find the ovary.

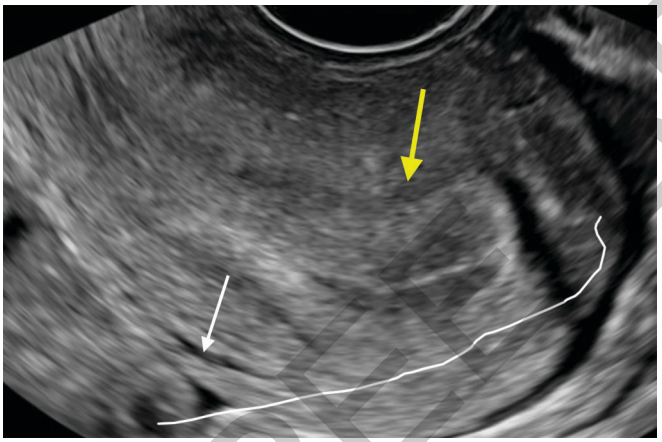

Fig. 6: Thin hypoechoic line around the endometrium is the endometrio-myometrial junctional zone (white arrow) and yellow arrow showing myometrium and the white curved line outlines the serosa.



Fig. 7: Cervical glands seen on the sides of the cervical canal.

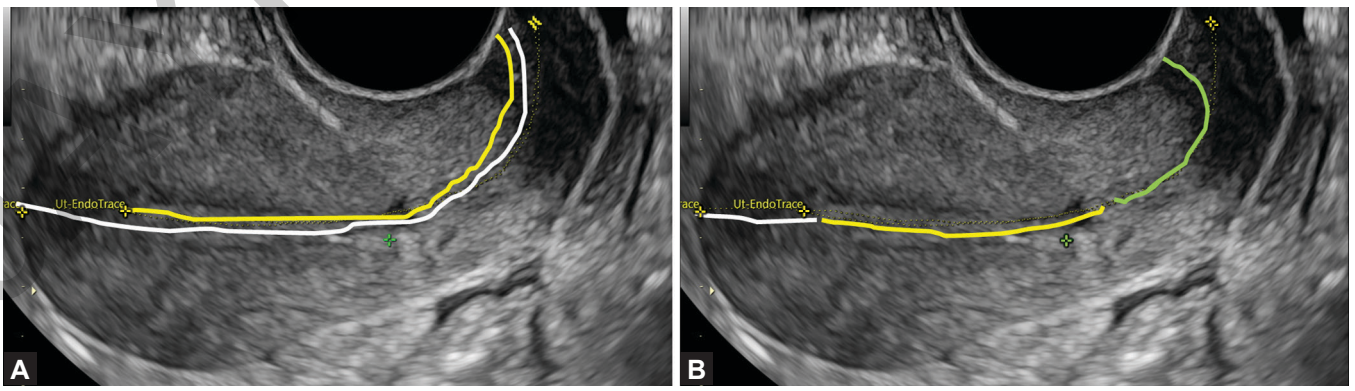

Figs. 8A and B: (A) B-mode image of the uterus, white line showing the measurement of anatomical uterocervical gland and yellow line is the physiological uterocervical length; and (B) B-mode image of the uterus, white line showing the measurement of myometrial length, yellow line is the endometrial length, and green line is the cervical length.

JAYPEE BROTHERS

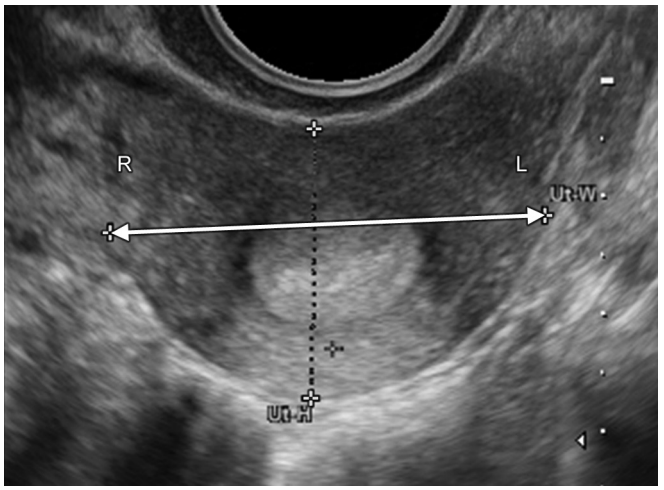

Fig. 9: Transverse section of the uterus, showing transverse diameter measurement of the uterus.

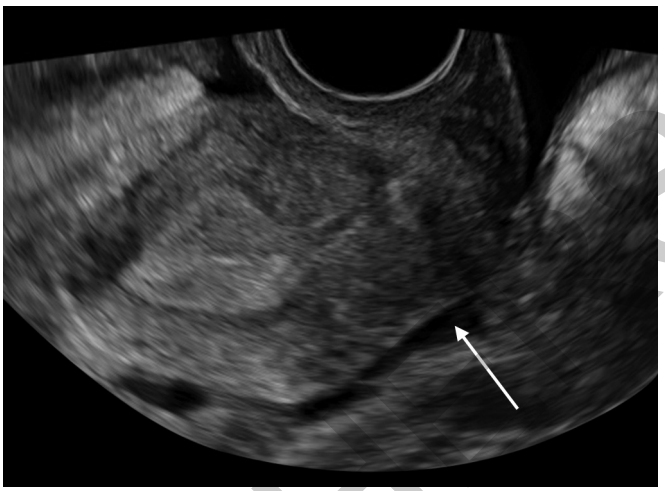

Fig. 10: B-mode image showing pouch of Douglas by white arrow.

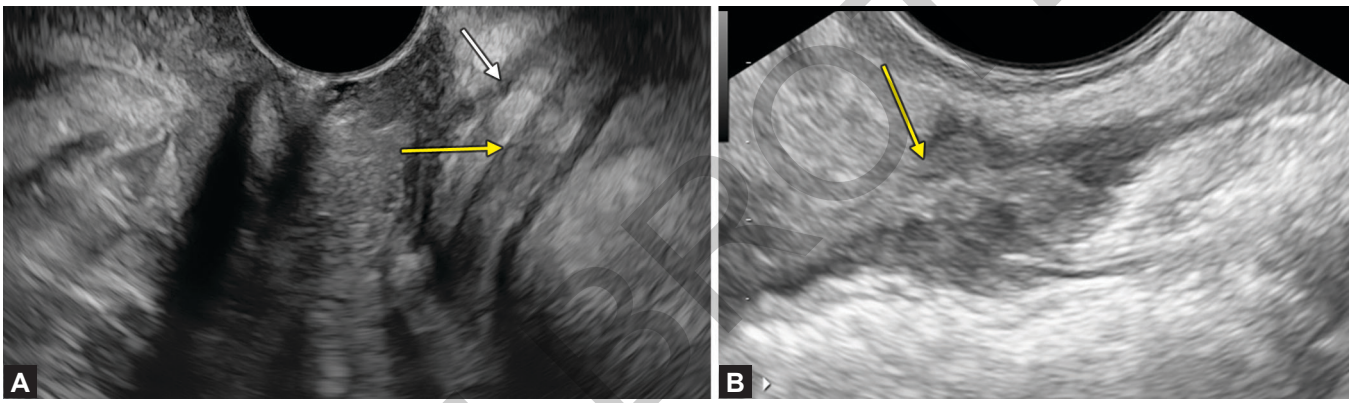

Figs. 11A and B: (A) B-mode image with probe at introitus (white arrow showing bowel muscularis and yellow arrow showing bowel lumen); and (B) Yellow arrow shows endometriotic patch in the bowel.

ADNEXA

- Look for mass lesion
- Localized fluid collection
- Thickening of the adnexa

Locate the ovary rotate probe to get a true long axis of the ovary. Scroll across on the long axis of the ovary and find the longest section and measure the longest diameter. The longest diameter perpendicular to this diameter is the anteroposterior diameter. A 90° rotation of the probe from this plane is the true transverse section and the largest side-to-side diameter is the transverse diameter (Fig. 9). These three diameters can be used to calculate the volume of the ovary. Then, move the probe to come back to the midline and follow the same procedure for the opposite adnexa.

Come back to the midline and angulate the probe head posteriorly and look for fluid in pouch of Douglas (Fig. 10).

Now before removing the probe, it is essential to check for the adhesions. Fix the probe against the uterine fundus and press over the abdomen with the hand. See if the bowel loops move against the uterine fundus. The same procedure is repeated for both the ovaries also. This is known as Timor-Tritsch test and confirms lack of adhesions. Instead of pressing on the abdomen, in and out movement of the probe can also be done to confirm the mobility of uterus and ovaries.

While removing the probe gently, have a close look at the cervical canal.

In cases where deep endometriosis is suspected, the probe is angulated slightly posteriorly toward the anal canal. This will show the bowel lumen and muscularis with interface between the vagina and the bowel (Fig. 11A). The probe is gently slided up toward the sigmoid colon. Any irregularity of the muscularis due to not very well-defined hypoechoic area suggests deep endometriosis (Fig. 11B).

This completes the two-dimensional routine transvaginal examination.

Color, pulse, or power Doppler can be added as and when required. For color Doppler of the uterine artery, the probe is brought back in the midline in longitudinal plane and then moving it laterally, serpiginous tubular structure

JAYPEE BROTHERS

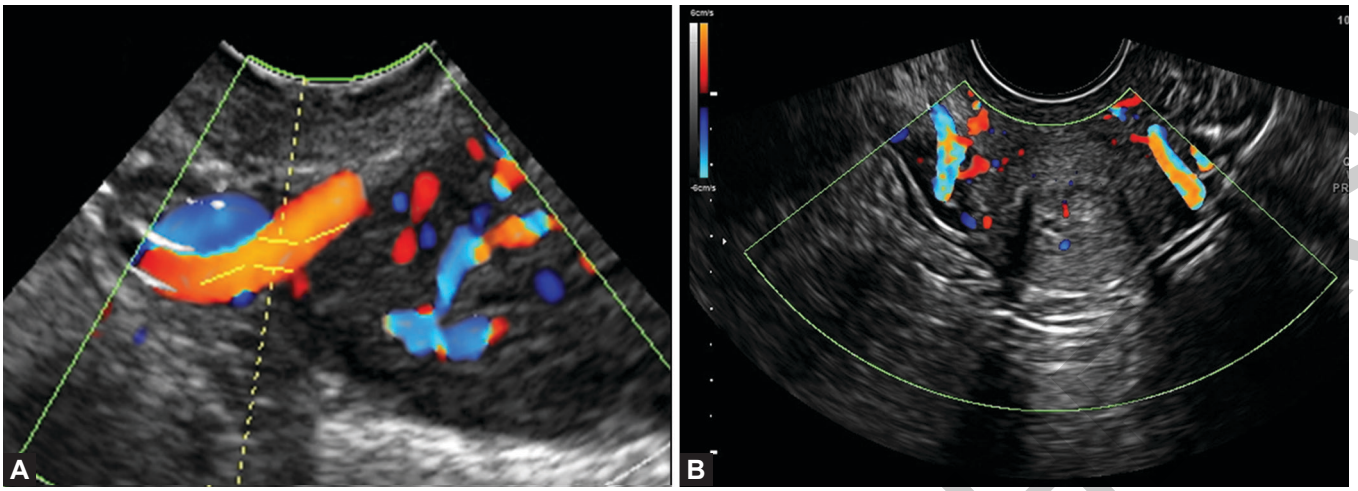

Figs. 12A and B: (A) Uterine artery seen on the sagittal section on color Doppler; and (B) Uterine arteries seen on both the sides of the internal os on color Doppler.

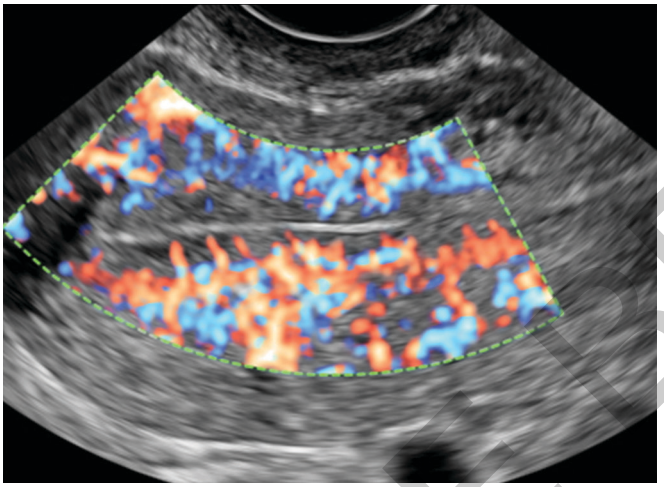

Fig. 13: Endometrial flow as seen on high-definition (HD) flow Doppler.

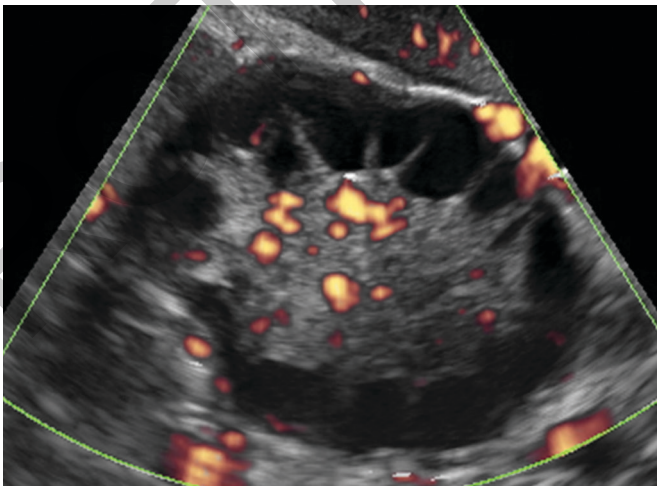

Fig. 14: Power Doppler image showing ovarian stromal flow.

is seen at the level of internal os, which is the uterine artery (Fig. 12A). It can also be traced in transverse axis of the uterus, moving the probe to the level of internal os, when arteries will be seen on both the sides (Fig. 12B).

Doppler is also used to evaluate the endometrial flow (Fig. 13). The blood vessels entering the endometrium are branches of spiral artery and are seen as vessels perpendicular to the endometrium. To document flow in the endometrial vessels, it is essential to hold the probe steadily in position on the endometrium for a few seconds to pick up this low-velocity flow. The ovarian stromal vessels are studied for baseline scan. The vessels that are seen in the ovarian stroma, not close to the follicles, are ovarian stromal vessels (Fig. 14). The main ovarian artery seen in the ovary is not the ovarian stromal vessel. Perifollicular flow is assessed in the vessels that overlap the follicular wall (Fig. 15).

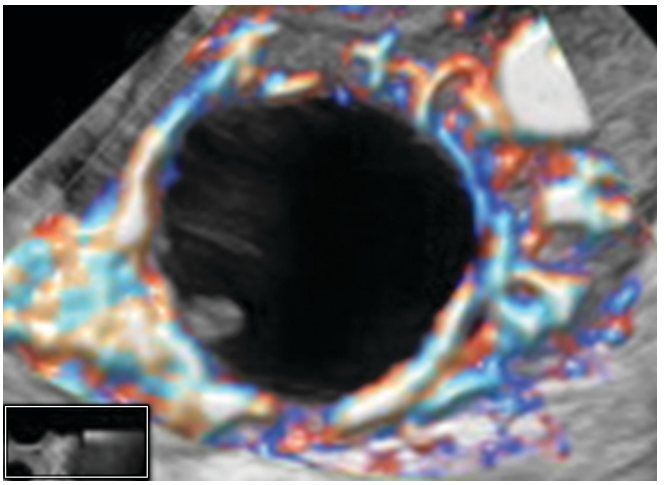

Fig. 15: High-definition (HD) flow image showing perifollicular flow.

REFERENCE

1. Hull MGR. Polycystic ovarian disease: clinical aspects and prevalence. Res Clin Forums. 1989;11:21-34.

JAYPEE BROTHERS

For detailed information on obstetrics & gynecology books, visit our website www.jaypeebrothers.com

FOGSI Focus
Imaging in OBSTETRICS & GYNECOLOGY

Salient Features

- With this book, the Imaging Science Committee, under the able guidance of FOGSI's Past President, Dr Nandita Palshetkar, has continued the tradition of academic exchange of knowledge at all platforms
- This book, with outstanding contribution from all its authors, aims to be at every FOGSIAN's table complying with the advocacy that every gynecologist and obstetrician should have the comprehensive knowledge, skill, and understanding of imaging
- All the chapters give very clear understanding with illustrative images and elaborate insight into the respective topics again stressing the fact that ultrasound is noninvasive, highly advanced and has an infinite potential
- I hope this book finds a place on your table and in your heart.

Nandita Palshetkar MD FCPS FICOG FRCOG (UK) is a Professor of Obstetrics and Gynecology, Dr DY Patil Medical College, Hospital and Research Centre, Navi Mumbai, Maharashtra, India. She is the Past President (2019) of the Federation of Obstetric and Gynaecological Societies of India (FOGSI) and has been the Past President of the Mumbai Obstetrics and Gynecological Society (MOGS), Indian Association of Gynaecological Endoscopists (IAGE), and Maharashtra Chapter of ISAR (MSR). She is the President Elect for the all Association of Maharashtra Obstetrics and Gynaecological Societies (AMOGS) and heads the IVF Unit at Lilavati Hospital and Research Centre, Mumbai; Bhatia Hospital, Mumbai; Dr DY Patil Medical College, Hospital and Research Centre, Navi Mumbai; and Fortis Hospitals, New Delhi, Gurugram and Chandigarh. Widely considered as a pioneer in assisted reproductive technology (ART) and responsible for offering the latest laboratory advances in the field to Indian patients, her passion for medicine in general and assisted reproduction in particular is well known. She has written over 100 textbook chapters, edited several books and has been the recipient of 18 National and International awards including the Bharat Gaurav Award at the House of Commons in the UK. Most recently, She has been conferred the Fellowship of the Royal College of Obstetricians and Gynaecologists (UK) ad eundem.

Meenu Agarwal MD is an eminent Endoscopic Surgeon and an Infertility Specialist from Pune, Maharashtra, India. As an alumnus of Armed Forces Medical College, Pune, she has been further trained in Germany for Endoscopy and Assisted Reproductive Technology (ART). She has been conferred with "Bachelor in Endoscopy" certified by the European Board. She is the Chairperson for Imaging Science Committee, FOGSI and an Elected Board Member of the International Society for Gynecologic Endoscopy (ISGE). She is the Director for the training courses in Endoscopy and ART conducted by the University Medical Center Schleswig Holstein (UKSH), Germany. She is a university guide for the postgraduate students at Ruby Hall Clinic, Pune and her center is a FOGSI recognized center for training in ART and Endoscopy. She is the National Director for Clinical Board, Morpheus IVF and her mission in life is to impart training and to bring best skills and knowledge for the benefit of her patients. She is an inspiration for her juniors and colleagues.

Rohan Palshetkar MS (Obs & Gyn) FRM is an ART Consultant and Endoscopic Surgeon. He is an Associate Professor, Dr DY Patil Medical College, Hospital and Research Centre, Navi Mumbai, Maharashtra, India. He is also the Unit Head, DY Patil Bloom IVF, Navi Mumbai. He is currently the Joint Treasurer of Maharashtra Chapter of IAGE; the Managing Committee Member of Maharashtra Chapter of ISAR; and also an Active Member of the Youth Council of Mumbai Obstetric and Gynaecological Society (MOGS). He has delivered the YUVA ISAR Oration and has been selected for the FOGSI Kamini Rao Yuva Oration for the year 2020. Besides this he has delivered several talks and contributed towards several publications for FOGSI and MOGS. He has won the AOFOG Young Gynaecologist Award, the FOGSI Corion Award, and FOGSI Kumud Tamaskar Award. In addition, he has won the MOGS DK Tank and LM Shah Prize for his paper presentations.

Chinmay Umarji MBBS DGO MRCOG (London UK) MRCP (Ireland) Research Fellowship in Fetal Med is a Consultant, Obstetrician, Gynecologist and Fetal Medicine Specialist in Sahyadri Hospital and Deccan Umarji Hospital, Pune, Maharashtra, India. He is also the Visiting Expert, Sassoon General Hospital, Pune. He is a Member, Antenatal Screening Committee, Government of Maharashtra and the National Coordinator for Imaging Sciences Committee, FOGSI.

Available at all medical bookstores
or buy online at www.jaypeebrothers.com



JAYPEE BROTHERS
Medical Publishers (P) Ltd.
www.jaypeebrothers.com

Join us on facebook.com/JaypeeMedicalPublishers

Shelving Recommendation
OBSTETRICS & GYNECOLOGY

