rothers.com, for detailed information on obstetrics & gynecology books, visit our website www.jaypeebrothers.com, for detailed information on obstetrics & gynecology books

FEDERATION OF OBSTETRIC AND GYNAECOLOGICAL SOCIETIES OF INDIA™
FOGSI

WE FOR स्त्री
Safer • Stronger • Smarter

Celebrating 50 YEARS
Passion, Quality and Innovation in Healthcare Publishing

FOGSI Focus

Adolescent Intervention For Future Reproductive Health

Editor-in-Chief
Nandita Palshetkar

Editor
Girish Mane

Co-editors
Rohan Palshetkar
Alok Sharma

JAYPEE

Contents

1. **Thieves of Sexual Health, Future Fertility and Reproductive Outcomes in Adolescents** 1
   Roza Olayi, Rajorhia Anita
2. **Adolescent PCOS: The Hunter for Dolls** 7
   S Sampathkumari
3. **Primary Amenorrhea** 11
   Alok Sharma, Geetika Gupta Syal, Aanya Sharma
4. **Congenital Anomalies: Future Fertility!** 16
   Shyjus Puliyathinkal
5. **Fertility Preservation in Ovarian Tumors in Adolescents** 22
   Tripti Sharan, Keerti Khetan
6. **Uterine Fibroids in Adolescents** 28
   Priyanka Dilip Kumar
7. **Endometriosis in Adolescents** 31
   Sheela Mane
8. **Menstrual Abnormalities in Adolescents** 36
   Jitendra Mane, Parag Biniwale
9. **Teenage Pregnancies and Abortions: Today's Scenario** 42
   Munjal Jayeshkumar Pandya, Janki Pandya
10. **Anemia in Adolescents** 48
    Shilpa Singh, Bindiya Gupta
11. **Sexually Transmitted Infection in Adolescents** 53
    Suchitra N Pandit, Swati Bhargava
12. **Contraception in Adolescents** 60
    Girish Mane, Santosh Maid
13. **Sexual Reproductive and Health Rights in Adolescents** 64
    Rohan Palshetkar, Jiteeka Thakkar
14. **The Protection of Children from Sexual Offences Act, 2012 (POCSO): What Every OB-GYN Specialist should Know?** 66
    MC Patel, Manish Machave
15. **Premarital Sex and Unprotected Sexual Activity in Adolescents** 69
    Sneha Bhuyar
16. **Adolescent-friendly Health Clinics** 74
    Vaishali Chavan, Varsha Lahade

Index *77*

CHAPTER

2 Adolescent PCOS: The Hunter for Dolls

S Sampathkumari

INTRODUCTION

Polycystic ovary syndrome (PCOS) affects women from menarche to menopause causing multiple problems. This condition affects their petite stature leading to obesity, hirsutism, acanthosis, thereby disfiguring their doll like appearance. PCOS thus hunts women throughout their life resulting in infertility, stress over appearance, anxiety. It is important for us to intervene and hunt the hunter before it can cause permanent damage to the future of these women. Adolescence is the apt time to attend to this problem without further aggravating the issue in her other stages of life.

Adolescence is the period from onset of prepubertal changes, attaining puberty, and adapting to pubertal changes. Polycystic ovary in adolescence presents with complaints of hirsutism, menstrual irregularity and/or obesity. This is a common condition and leading cause of infertility in later days.

ETIOPATHOGENESIS

Polycystic ovary syndrome involves ovulatory dysfunction and increased androgen synthesis. Defects in ovarian steroidogenesis form the pathophysiology of PCOS **(Fig. 1)**. It has genetic basis too and is inherited as autosomal dominant with variable penetrance.[1] Anovulation leads to irregular menstrual cycles with cycle length varying from 19 to 90 days. Inappropriate gonadotropin secretion, with changes in follicle stimulating hormone (FSH) and luteinizing hormone (LH), lead on to ovulatory dysfunction. This forms a cycle due to loss of negative feedback. Also, impaired ovarian steroidogenesis leads to increased androgen production from ovarian stroma and theca call hyperplasia. Occurrence of insulin resistance leads to hyperinsulinemia. Decreased sex hormone binding globulin by action of liver in turn causes increasing of free androgen levels. Insulin resistance also alters the lipid and glucose metabolism.

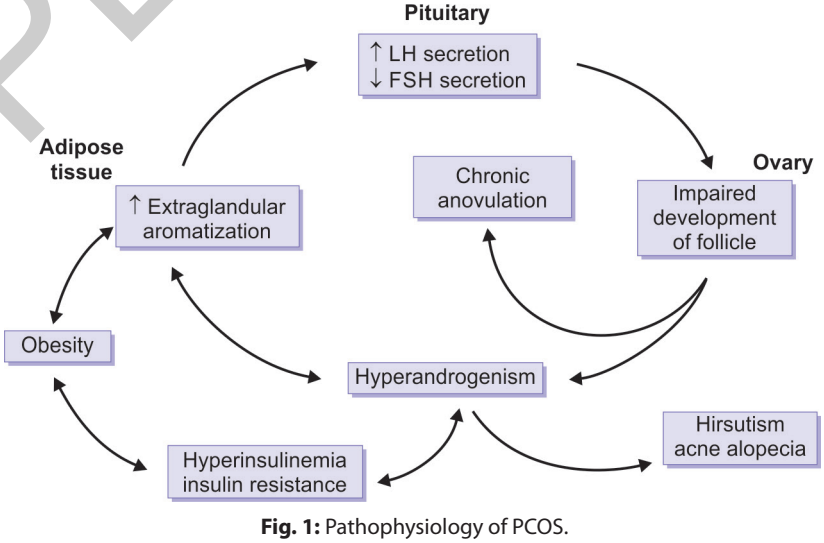

Fig. 1: Pathophysiology of PCOS.
(FSH: follicle stimulating hormone; LH: luteinizing hormone; PCOS: polycystic ovary syndrome)

JAYPEE BROTHERS

CLINICAL FEATURES

- Irregular menstrual cycles
- Obesity
- Insulin resistance
- Hirsutism
- Acne

Adolescents tend to have anovulatory cycles initially due to immaturity of hypothalamo pituitary axis. However, in the presence of hyperandrogenism, persistent anovulation for >2 years, the likelihood of having PCOS is >80%.[2] In the absence of any endocrine disorder, persistent anovulatory cycles >1 year presenting as irregular menstrual cycles is 50% likely due to PCOS in adolescent.

Sexual hair growth is graded by Ferriman-Gallwey scoring system **(Fig. 2)**. Scores 8–15 indicate mild hirsutism and 16–24 indicate moderate hirsutism.[3] This scoring system assesses hair growth in 9 areas and scores 0 (no hair) to 4 (abundant virile hair) in each area. This is difficult for an adolescent because they have not attained sexual maturity and sexual hair growth is in process of development.

Acne is a common manifestation of puberty. This is mostly comedonal acne. Moderate to severe inflammatory acne is not a common manifestation and it indicates PCOS. This kind of persistent acne that is unresponsive to topical treatments need to be evaluated for hyperandrogenism before starting on oral contraceptive pills (OCPs), because OCPs can mask features of PCOS. Comedonal acne refers to blackheads or whiteheads >1 mm diameter. Inflammatory acne present as pustules, papules <5 mm, nodules >5 mm, with scarring. Examination of face, chest, back, and shoulders for acne is advised.

Normal upper limits for total testosterone are 55 ng/mL and free testosterone is 9 pg/mL. Free testosterone is a more reliable indicator of hyperandrogenism than total hormone. However, elevated levels in asymptomatic girls have no significance. Only when this increased levels present with persistent anovulation, it is diagnostic of PCOS.

Ultrasonographic picture of ≥12 small antral follicles (2–9 mm diameter) per ovary with ovarian volume >10 mL per ovary characterizes appearance of polycystic ovaries. There is ovarian enlargement, thecal hyperplasia, capsular thickening, and luteinization. However, it is difficult to count antral follicle count with abdominal scan in adolescents and also 50–75% adolescents generally meet the adult criteria as

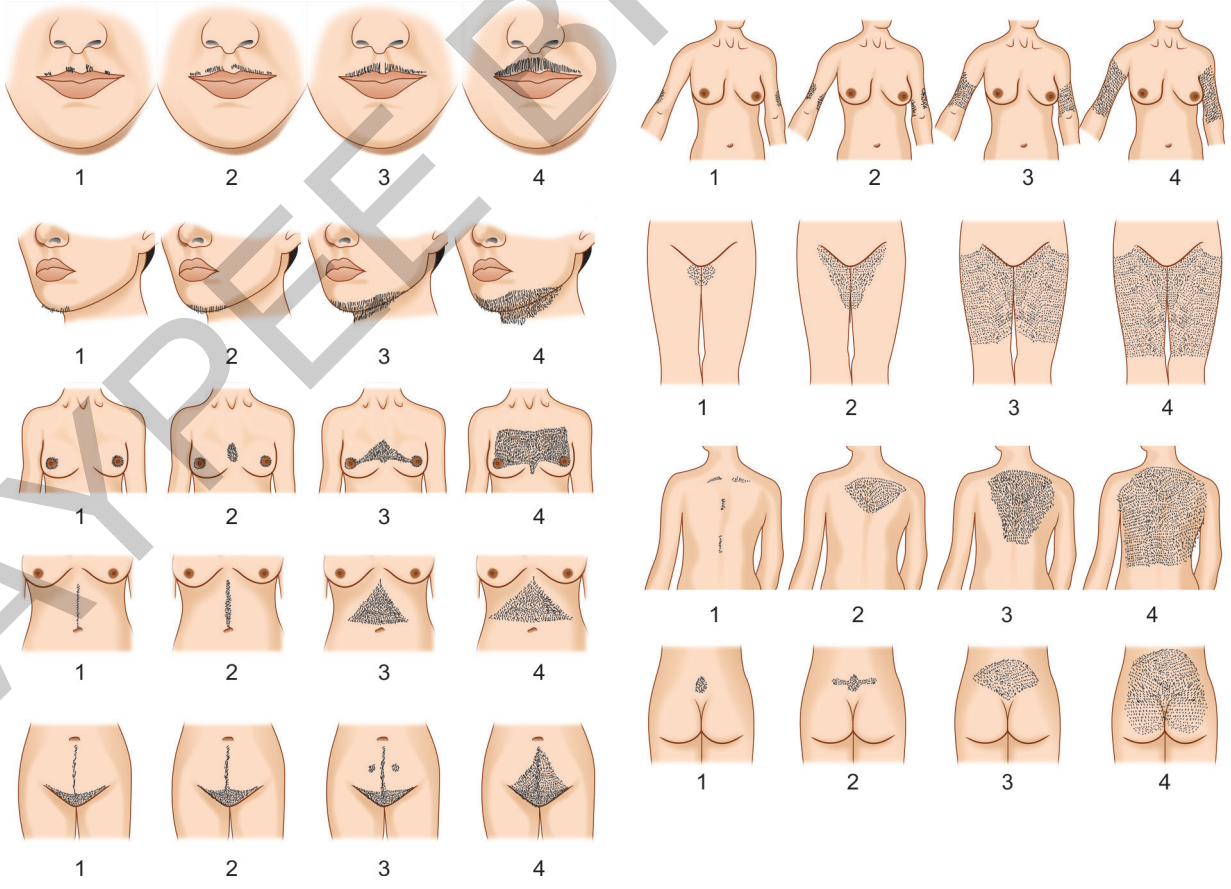

Fig. 2: Ferriman–Gallwey score.

JAYPEE BROTHERS

normal variant.[4] So, mean ovarian volume >12 cc or single ovary >15 cc is considered enlarged for adolescent.[5]

Insulin resistance can be present in both obese and nonobese PCOS. Obesity is present in about 50% PCOS patients.[6] Insulin resistance results in increased abdominal fat deposits irrespective of body mass index status. It can manifest as acanthosis nigricans. But PCOS can present without insulin resistance or obesity also.

COMPLICATIONS

- Infertility
- Metabolic syndrome
- Type 2 diabetes mellitus
- Cardiovascular disease risk
- Endometrial cancer

Metabolic syndrome which is a group of conditions ranging from central obesity, glucose abnormality, hypertension, dyslipidemia occurs in 25% PCOS individuals.[5] This leads to type 2 diabetes mellitus, cardiovascular risk, and sleep apnea disturbances as they progress to adulthood.

DIAGNOSIS

The Rotterdam criteria for PCOS in adult are unexplained hyperandrogenism, anovulation, and ultrasound picture of polycystic ovaries. However, using these criteria to diagnose PCOS in adolescent is difficult as anovulation and acne are common in adolescents. So, the Pediatric Endocrine Society has come up with following criteria for diagnosing PCOS in adolescent.

Combination of unexplained abnormal uterine bleeding (AUB) and hyperandrogenism[7] can lead to persistent AUB for 1 or 2 years. Hyperandrogenism can be diagnosed clinically as moderate to severe hirsutism, moderate to severe acne vulgaris refractory to treatment, androgenic alopecia, and laboratory values of serum testosterone elevated above normal limits for adults.

Measurement of FSH and LH can be done to rule out other causes of anovulation.[8] High FSH indicates primary ovarian failure, low LH indicates hypogonadism, and high LH/FSH ratio is suggestive of PCOS. 17 hydroxyprogesterone levels rule out adrenal hyperplasia, values >200 ng/dL are suggestive of and >1,000 ng/dL are confirmatory of adrenal etiology. Ultrasound is necessary to identify polycystic ovaries and rule out other virilizing tumors that can cause anovulation and hyperandrogenism. Fasting lipid profile, glucose tolerance test are needed to rule out metabolic syndrome and diabetes mellitus. Thyroid profile, prolactin can be done to complete hormonal evaluation of anovulation.

TREATMENT

Symptomatic management aims at addressing menstrual irregularity, clinical hyperandrogenism, and complications of metabolic syndrome. Management of obesity and related comorbidities is by lifestyle modification, diet, and exercise.[9] Weight reduction can improve 50% symptoms of PCOS and normalize hormone levels. Exercise improves sensitivity to insulin and prevents onset of diabetes mellitus.

Metformin can be used as insulin sensitizer in cases of glucose intolerance. Otherwise, it has no role in weight reduction and hence, is no longer used in first-line management of PCOS.

Cyclic hormonal administration in the form of combined oral contraceptive (COC) pills forms first-line management. This COC ensures withdrawal bleeding; thereby, preventing endometrial carcinoma and also inhibits ovarian function and steroidogenesis. These COCs can be withdrawn after 3 months to check for persistent hyperandrogenic anovulation. COC also helps in treating acne and hirsutism in some women. COCs containing cyproterone acetate (Yasmin) help in treating hirsutism with their antiandrogenic action.

In refractory cases, antiandrogens like spironolactone 50–100 mg bd may be used to counter hyperandrogenism. Depilatory creams, waxing, and shaving are also used to remove excess hair. Long-term removal of unwanted hair by laser, electrolysis is more expensive.

Surgical management like ovarian wedge resection, ovarian drilling under laparoscopy have fallen out of favor as treatment options as they compromise the ovarian function. They are used as last resort in some refractory cases to counter stromal hyperplasia and hyperandrogenism. They carry risk of adhesions and decreased ovarian reserve.

Apart from these physical symptoms, PCOS also affects emotional status of the adolescent as they are more prone to body image issues, low self-esteem at this age. This can lead on to depression. Identification, reassurance, and counseling along with medical management improve their quality of life.

CONCLUSION

Polycystic ovary syndrome is a very common condition with severe morbidity affecting quality of life. Early diagnosis and treatment of this condition can prevent the metabolic complications due to this condition.

JAYPEE BROTHERS

REFERENCES

1. Vink JM, Sardazeh S, Lambalk CB. Heritability of polycystic ovary syndrome in a Dutch twin family study. J Clin Endocrin Metab. 2006;91(6):2100-4.
2. van Hooff MH, Voorhorst FJ, Kaptein MB, Hirasing RA, Koppenaal C, Schoemaker J. Predictive value of menstrual cycle pattern, body mass index, hormone levels and polycystic ovaries at age 15 years for oligo-amenorrhea at age 18 years. Hum Reprod. 2004;19(2):383-92.
3. Martin KA, Anderson RR, Chang RJ, Ehrmann DA, Lobo RA, Murad MH, et al. Evaluation and treatment of hirsutism in premenopausal women: an endocrine society clinical practice guideline. J Clin Endocrinol Metab. 2018;103(4): 1233-57.
4. Kenigsberg LE, Agarwal C, Sin S, Shifteh K, Isasi CR, Crespi R, et al. Clinical utility of magnetic resonance imaging and ultrasonography for diagnosis of polycystic ovary syndrome in adolescent girls. Fertil Steril. 2015;104(5):1302-9.
5. Hart R, Doherty DA. The potential implications of a PCOS diagnosis on a women's long-term health using data linkage. J Clin Endocrinol Metab. 2015;100(3):911-9.
6. Ehrmann DA. Polycystic ovary syndrome. N Eng J Med. 2005;352(12):1223-36.
7. Witchel SF, Oberfield S, Rosenfield RL, Codner E, Bonny A, Ibáñez L, et al. The diagnosis of polycystic ovary syndrome during adolescence. Horm Res Pediatr. 2015;83(6):376-89.
8. Rosenfield RL. Clinical review: adolescent anovulation: maturational mechanisms and implications. J Clin Endocrinol Metab. 2013;98(9):3572-83.
9. Naderpoor N, Shorakae S, de Courten B, Misso ML, Moran LJ, Teede HJ. Metformin and lifestyle modification in polycystic ovary syndrome: systematic review and meta-analysis. Hum Reprod Update. 2015;21(5):560-74.

JAYPEE BROTHERS

or detailed information on obstetrics & gynecology books, visit our website www.jaypeebrothers.com, for detailed information on obstetrics & gynecology books, visit our webs

Adolescent Intervention For Future Reproductive Health

The word Adolescence is derived from the Latin word Adolescere. It means to grow or to mature. There are very conspicuous physical and mental changes at this age in the boys and girls. These normal physical and mental changes sometimes get abnormal or subnormal diversions, which may need help of parents or health worker to get through. Such subnormal changes are experienced in girls often frequently than boys. The common health issues faced by the girls are menstrual disorders, anemia, polycystic ovarian disease (PCOD), psychosocial problems, sexual problems and many more.

Also there are many conditions or diseases in the girls which can affect the future fertility of a girl in various forms, if not taken care at right time. She may face infertility, abortions, premature deliveries, intrauterine growth restriction (IUGR), intrauterine death (IUD) or other complications in pregnancy.

This book is all about the diseases or disorders which can affect the future fertility of an adolescent girl.

Nandita Palshetkar MD FCPS FICOG FRCOG (UK) is a Professor of Obstetrics and Gynecology, Dr DY Patil Medical College, Hospital and Research Centre, Navi Mumbai, Maharashtra, India. She is the Past President (2019) of the Federation of Obstetric and Gynaecological Societies of India (FOGSI), and has been the Past President of the Mumbai Obstetrics and Gynecological Society (MOGS), Indian Association of Gynaecological Endoscopists (IAGE), and Maharashtra Chapter of ISAR (MSR). She is the President of the Association of Maharashtra Obstetrics and Gynaecological Societies (AMOGS) and heads the IVF unit at Lilavati Hospital and Research Centre, Mumbai; Bhatia Hospital, Mumbai; Dr DY Patil Medical College, Hospital and Research Centre, Navi Mumbai; and Fortis Hospitals, New Delhi, Gurugram and Chandigarh. She is the Vice President of Indian Association of Assisted Reproduction. She is the Founder and Medical Director of Bloom IVF heading 10 IVF Centres all over India. Widely considered as a pioneer in assisted reproductive technology (ART) and responsible for offering the latest laboratory advances in the field to Indian patients, her passion for medicine in general and assisted reproduction in particular is well known. She has written over 100 textbook chapters, edited several books and has been the recipient of 18 National and International awards including the Bharat Gaurav Award at the House of Commons in the UK. Most recently, She has been conferred the Fellowship of the Royal College of Obstetricians and Gynaecologists (UK) adeundem.

Girish Mane MBBS DGO FICOG is Senior Obstetrician and Gynecologist from Yavatmal, Maharashtra, India. He was an Assistant Lecturer in Department of Obstetrics and Gynecology, Shri Vasantrao Naik Government Medical College, Yavatmal for 5 years. He is the Director, Mane Hospital, Yavatmal, Maharashtra, India. Gynecological surgery is his area of interest in Obstetrics and Gynecological practice. He is Past President of Yavatmal Obstetrics and Gynecological Society (2016–17) and Chairperson of Adolescent Gynecology Committee of Association of Maharashtra Obstetrics and Gynaecological Societies (AMOGS) (2018–20). He received best Chairperson Award of AMOGS in 2020. Currently, he is Chairperson of Adolescent Health Committee, FOGSI (2019–21) and is doing excellent work for adolescents of India. He is recipient of FOGSI Smriti Mylan Save Baby Girl Runner up Award, Dr Duru Shah Youth Trophy and Dr Sadhana Desai Award (2017). He is First Winner of FOGSI Got Talent Singing Contest held in AICOG Conference, Bhubaneshwar, Odisha. He has contributed 5 chapters in various FOGSI Focus. He is an Editor of AMOGS, FOCUS—Adolescent Health Care and FOGSI's FAQ: Adolescent Health. He has presented many papers in national and state conferences.

Rohan Palshetkar MS (Obs & Gyn) FRM is an ART Consultant and Endoscopic Surgeon. He is an Associate Professor, Dr DY Patil Medical College, Hospital and Research Centre, Navi Mumbai, Maharashtra, India. He is also the Unit Head, DY Patil Bloom IVF, Navi Mumbai. He is currently the Joint Treasurer of Maharashtra Chapter of IAGE; the Managing Committee Member of Maharashtra Chapter of ISAR; and also an Active Member of the Youth Council of Mumbai Obstetric and Gynaecological Society (MOGS). He has delivered the YUVA ISAR Oration and has been selected for the FOGSI Kamini Rao Yuva Oration for the year 2020. Besides this he has delivered several talks and contributed towards several publications for FOGSI and MOGS. He has won the prestigious FOGSI Corion, Shanti Yadav Award, Kumud Tamaskar and Praveen Mehta Awards for his research papers. He has also won the best Youth Council Member Award for MOGS twice. In addition, he has won the MOGS DK Tank and LM Shah Prize for his paper presentations.

Alok Sharma MD DHA MICOG is an Assistant Professor, Department of Obstetrics and Gynecology, Dr Rajendra Prasad Government Medical College, Kangra, Himachal Pradesh, India. He is Founder Secretary, Indian Menopause Society, Shimla Chapter and Indian Fertility Society, Himachal Pradesh Chapter. Presently, he is North Zone Co-ordinator of Hello Tomorrow CMEs and an Advisor to Sexual Medicine Committee, FOGSI. He is active Member of Public Awareness Committee FOGSI and Adolescent Health Committee, FOGSI.

Available at all medical bookstores
or buy online at www.jaypeebrothers.com

JAYPEE BROTHERS
Medical Publishers (P) Ltd.
www.jaypeebrothers.com

Join us on facebook.com/JaypeeMedicalPublishers

Shelving Recommendation
OBSTETRICS & GYNECOLOGY

ISBN 978-93-89776-49-2