urgery books, visit our website www.jaypeebrothers.com, for detailed information on surgery books, visit our website www.jaypeebrothers.com, for detailed information on surgery books

Celebrating 50 YEARS
Passion, Quality and Innovation in Healthcare Publishing

Free Radial Artery Forearm Flap for Head and Neck Reconstruction

A Color Atlas

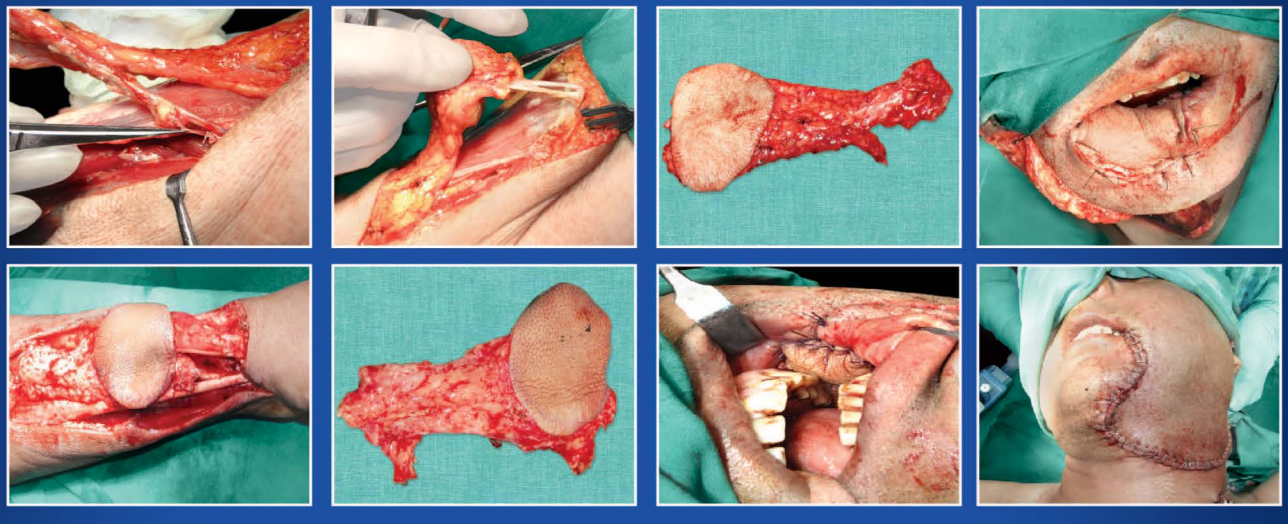

Girish N Amlani
Dipen D Patel

Foreword
Santosh Raibagkar

JAYPEE

Contents

1. Introduction **1**

2. Historical Perspective **2**

3. Advantages and Disadvantages **3**

4. Anatomy **4**

5. Preoperative Preparation **6**

6. Operative Steps of Free Radial Artery Forearm Flap **7**

7. Postoperative Care **38**

8. Case Studies **39**

9. Complications **85**

Suggested Reading *86*

Index *87*

CHAPTER

4 Anatomy

SURGICAL ANATOMY

Anatomy of Radial Artery in Forearm[1] (Fig. 1)

The radial artery is smaller than the ulnar artery and appears a more direct continuation of the brachial artery. Radial artery[2] starts 1 cm distal to the flexion crease of the elbow. Radial artery descends along the lateral side of the forearm from the medial side of the neck of the radius to the wrist. Radial artery is accompanied by paired venae comitantes. The radial artery lies on tendon of biceps, supinator, the distal attachment of pronator teres, the radial head of flexor digitorum superficialis, flexor pollicis longus, pronator quadratus and the lower end of the radius. Brachioradialis is lateral to the radial artery throughout its length. Pronator teres is medial to the radial artery proximally and flexor carpi radialis lies medially in distal portion.

The radial artery[3] has septocutaneous perforators in lateral intermuscular septum to overlying forearm skin. The perforators form arcade of vessels superficial to the deep fascia. The radial artery is accompanied by two venae comitantes draining into the medial cubital vein. The cephalic vein drains the flap through superficial subcutaneous veins. Either or both systems can be used for venous drainage of the radial artery forearm flap.

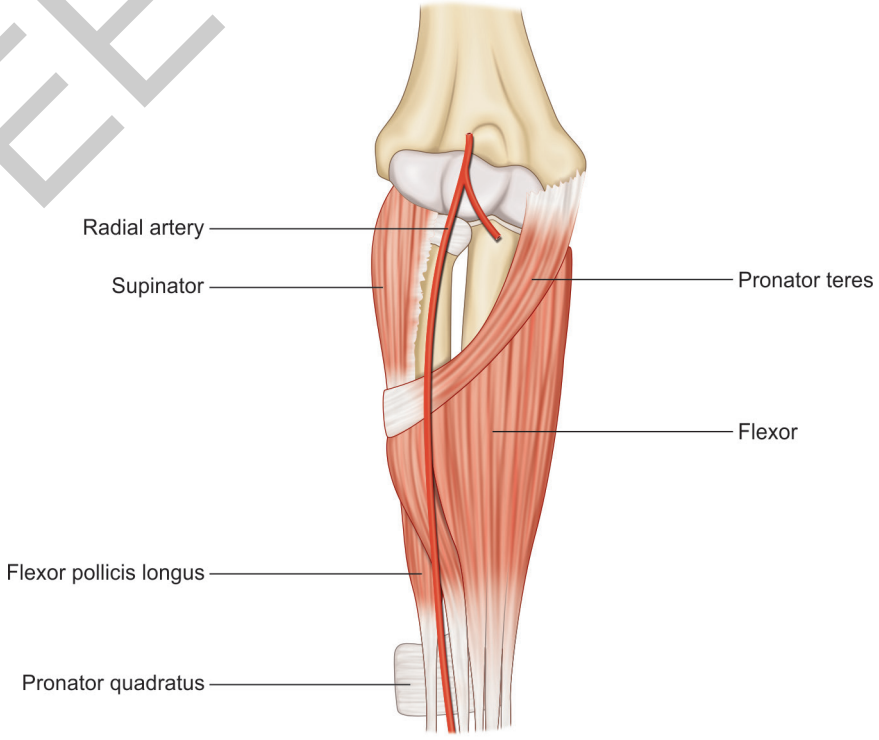

Fig. 1: Anatomy of radial artery in forearm.

JAYPEE BROTHERS

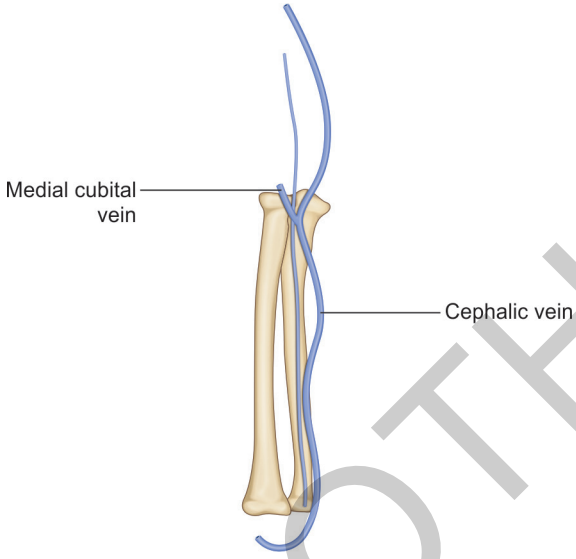

Fig. 2: Anatomy of cephalic vein.

Anatomy of Cephalic Vein[1] (Fig. 2)

The cephalic vein forms over the anatomical snuff box from the radial end of the dorsal venous plexus. Cephalic vein curves proximally around the radial side of the forearm to gain its ventral aspect. It receives veins from the both aspects of the forearm. The medial cubital vein, a branch distal to the elbow diverges proximomedially to reach the basilic vein. The medial cubital vein is joined by a branch from deep veins.

REFERENCES

1. Gray's Anatomy: Fortieth Edition. pp. 852-3.
2. Cormack GC, Lamberty BGH 1994. The Arterial Anatomy of Skin Flap Edinburgh: Churchill Livingstone.
3. Salmon M 1994 Anatomic Studies. In: Taylor GI, Razaboni RM (Eds), Book 1: Arteries of the Muscles of the Extremities and the Trunk. Book 2: Arterial Anastomotic Pathways of the Extremities. St Louis MO: Quality Medical Publishing.

JAYPEE BROTHERS

for detailed information on surgery books, visit our website www.jaypeebrothers.com, for detailed information on surgery books, visit our website www.jaypeebrothers.com, for detailed in

Free Radial Artery Forearm Flap for Head and Neck Reconstruction

A Color Atlas

Salient Features

- Provides information for those who work in the field of head and neck reconstruction
- Describes the general principles and technique in clear language
- Contains most of the basic principles and facts about free radial artery forearm flap
- Depicts numerous color photographs explaining various designs of free radial artery forearm flap for head and neck reconstruction.

Girish N Amlani MS (General Surgery) MCh (Plastic Surgery) is the Honorary Head and Neck Reconstructive Surgeon at Shri NM Virani Wockhardt Hospital, Rajkot, Gujarat, India. His area of expertise is head and neck reconstruction. Dr Amlani has experience of more than 5000 head and neck reconstruction and more than 2000 microsurgical procedures.

Dipen D Patel MS (General Surgery) MCh (Surgical Oncology) is full time Consultant Surgical Oncologist and Head, Department of Surgical Oncology at Shri NM Virani Wockhardt Hospital, Rajkot. He has done his MCh from Gujarat Cancer and Research Institute, Ahmedabad, Gujarat, India. He has successfully performed more than 1500 head and neck cancer operations. Dr Patel is ex-observer at head and neck oncology department at Memorial Sloan Kettering Cancer Center, New York, USA, under guidance of Jatin P Shah.

Available at all medical bookstores
or buy online at www.jaypeebrothers.com



JAYPEE BROTHERS
Medical Publishers (P) Ltd.
www.jaypeebrothers.com

Join us on facebook.com/JaypeeMedicalPublishers

Shelving Recommendation
SURGERY

