m, for detailed information on neurology books, visit our website www.jaypeebrothers.com, for detailed information on neurology books, visit our website www.jaypeebrothers.com, for detailed information on neurology books

Get Full Access
with added Features
and Videos at
emedicine360.com

Celebrating 50
Passion, Quality and Innovation in Healthcare Publishing



MIMICS of Epileptic Seizures

Ambar Chakravarty

Foreword
Professor David Bates

JAYPEE

Contents

1. **Sir William Richard Gowers (1845–1915) and the Borderland of Epilepsy: A Tribute** 1
   Ambar Chakravarty

2. **Seizure Diagnosis and the Mimics: An Introduction** 17
   Ambar Chakravarty

   2A: Commentary: Seizure Diagnosis and Evaluation in the Era of Coronavirus Disease 2019 28
   Amit Halder, Ambar Chakravarty

   2B: Commentary: A Note on Carotid Sinus Syncope 36
   Ambar Chakravarty

   2C: Commentary: Geriatric Seizure Mimics: A Problem Oriented Approach 39
   Ambar Chakravarty

3. **Syncope and Reflex Anoxic Seizure: Neurological Perspectives and Evaluation** 43
   Ambar Chakravarty

   3A: Commentary: Why are Elderly People More Susceptible to Syncopal Attacks? Key Issues Which Need Addressing 53
   Ambar Chakravarty

4. **Unusual Seizures: Which May Not Look Like Seizures** 57
   Nitika Mahajan, Gagandeep Singh

   4A: Commentary: A Note on Ecstatic and Orgasmic Seizures 66
   Ambar Chakravarty

   4B: Commentary: Self-induced Seizures and Seizure Look Alikes 75
   Ambar Chakravarty

5. **Mimics of Nonconvulsive Status Epilepticus** 82
   Ambar Chakravarty

6. Cerebrovascular Mimics of Epileptic Seizures **89**
Subhas Kaul, P Suresh Babu

6A: Commentary: The Three Musketeers: Great Mimickers of Epileptic Seizures 96
Ambar Chakravarty

7. Migraine and Epilepsy **107**
Ambar Chakravarty

8. Sleep Disorders Mimics of Epilepsy **126**
Sudhansu Chokroverty, Sushanth Bhat

8A: Commentary: Utility of Sleep in Seizure Diagnosis 158
Ambar Chakravarty

9. Movement Disorder Mimics of Epileptic Seizures **163**
Asha Kishore, Roopa Rajan

9A: Commentary: Epilepsy and Movement Disorders: The Other Side of the Coin and Beyond 169
Ambar Chakravarty

9B: Commentary: Psychogenic Non-epileptic Seizures and Psychogenic Movement Disorders – Are They Really Different? 176
Ambar Chakravarty

10. Endocrine and Metabolic Mimics of Epileptic Seizures **180**
Ajitesh Roy, Sudip Chatterjee

10A: Commentary: Hyperosmolar Hyperglycemic State for the Neurologist 191
Ambar Chakravarty

10B: Commentary: Hashimoto's Encephalopathy: A Diagnosis Not to be Missed 195
Angshuman Mukherjee, Ambar Chakravarty

11. Psychogenic Nonepileptic Seizures **200**
Arparajita Chatterjee, Sanjib Sinha

11A: Commentary: A Note on the Psychopathology of Psychogenic Nonepileptic Seizures 217
Ambar Chakravarty

11B: Commentary: Psychogenic Seizures: Why Women? 221
Ambar Chakravarty

11C: Commentary: Spell Induction: Pros and Cons 223
Ambar Chakravarty

11D: Commentary: The Problem of Coexisting Epileptic and Nonepileptic Seizures 227
Ambar Chakravarty

12. Hysteria—Changing Concepts on the Nature of the Beast: Through Centuries 234
Ambar Chakravarty

13. Psychiatric Mimics of Epileptic Seizures: Part 1—Episodic Dyscontrol Syndrome: The Concept 246
Ambar Chakravarty

14. Psychiatric Mimics of Epileptic Seizures: Part 2—Epilepsy, Rage, Tantrums, and Violence 251
Ambar Chakravarty

15. Mimics of Epileptic Seizures in Pediatric Practice 256
Neelu Desai, Vrajesh Udani

15A: Commentary: Pitfalls in Diagnosis of Epilepsy: Focus on Epilepsies in Children 269
Deb K Pal, Ambar Chakravarty

15B: Commentary: Benign Childhood Focal Epilepsies: Mimics and Chameleons 277
Ambar Chakravarty

15C: Commentary: Head Drops in the Young—Epileptic or Non-epileptic? 286
Ambar Chakravarty

16. Falls and Drop Attacks in the Elderly 292
Angshuman Mukherjee

16A: Commentary: My Falls: An Introspection 300
Ambar Chakravarty

16B: Commentary: Drop Attacks in the Young: Focus on Orthostasis 304
Ambar Chakravarty

17. Hyperventilation Syndrome 309
Ambar Chakravarty

18. Panic Disorders and Epilepsy **318**
Debasis Roy

18A: Commentary: Postural Tachycardia Syndrome and Panic: How are they Related and Mimic Epileptic Seizure?—A Brief Note 322
Ambar Chakravarty

18B: Commentary: A Note on Ictal Fear (Panic) 323
Ambar Chakravarty

19. Epilepsy and Vertigo **327**
Ambar Chakravarty

20. Visual Illusions and Hallucinations of Central Origin and Their Differentials **335**
Ambar Chakravarty

21. Seizures and Seizure Look Alikes in Multiple Sclerosis **347**
Ambar Chakravarty

22. Utility and Pitfalls of Video-electroencephalography in Diagnosis of Difficult and Unusual Epileptic Seizures **354**
Ashalatha Radhakrishnan

Index **363**

CHAPTER

2

Seizure Diagnosis and the Mimics: An Introduction

Ambar Chakravarty

JAYPEE BROTHERS

INTRODUCTION

The diagnosis of an epileptic seizure depends on an accurate history given by the patient and the eyewitnesses and is essentially a clinical exercise. There are a number of conditions which mimic epileptic seizures affecting the brain primarily or secondarily and these are called imitators of epilepsy. Loss of postural tone in atonic seizures and the clinical phenomenology in cataplexy may be very similar. About 20–30% of nonepileptic events are diagnosed as epileptic seizures.[1,2] It is only after second or third event that the diagnosis becomes possible. Syncope is a common clinical condition which is misdiagnosed as epilepsy with catastrophic consequences and sometimes may even lead to premature death. Several professional societies strongly recommend that a patient with a suspected diagnosis of epilepsy should be examined by a neurologist or an epileptologist[3] (Scottish Intercollegiate Guidelines Network). Sometimes, it may be difficult to gather all relevant information in an emergency situation but it is of utmost importance for further management. It is important to know if the attack was provoked by factors such as sleep deprivation, alcohol withdrawal, flickering lights, or drug abuse.

The tonic-clonic (TC) phase of a generalized seizure is usually thought to be the beginning of the event to most eyewitnesses. Detailed questioning about preceding events like facial automatisms, limb movements, abnormal behavior, etc., may point toward a focal onset. Factors that are strongly suggestive of a TC seizure include expiratory groan or cry, tonic movement of the extremities, falling down stiffly with traumatic impact, rhythmic followed by irregular slow jerking of limbs, facial contraction with clenched teeth, cyanosis and frothing from the mouth, and incontinence. The duration of the event is extremely important as the TC phase usually lasts <2 minutes.[4] Sometimes, it may be useful for an observer to actually imitate the event as the clonic movements of a seizure as opposed to hypermotor movements can be better appreciated. The behavioral pattern during the actual event is extremely important as forced eye closure indicates a dissociative event with a sensitivity of 96% and a specificity of 98%.[5] The patient is usually unconscious in the postictal state with noisy labored breathing due to a hypotonic upper airway and often with blood and

saliva in the mouth. The patient is usually stuporous, prefers to be left alone, often finds a suitable position to sleep, remains confused for several minutes on regaining consciousness, and slowly reverts back to normal. The postictal confusion is a strong indicator of an actual organic event.[6]

PHYSICAL AND NEUROLOGICAL STATUS

Head injuries, shoulder dislocation, and tongue bite involving the lateral aspect of the tongue are strongly suggestive of epileptic seizures.[7] Bilateral extensor plantar responses are common in the postictal stuporous state.

ELECTROENCEPHALOGRAPHY

It is an important diagnostic tool as paroxysmal changes are seen in 34% of cases after a first seizure and as much as 50–70% of cases if performed within 24 hours.[8,9] A sleep-deprived electroencephalography (EEG) can reveal additional spike discharges in additional 13–31% of cases. EEG has got a low sensitivity and should be used as a test to exclude epilepsy, but it is very useful in the classification of different types of seizures and epilepsy syndromes. Minor EEG findings should not be overinterpreted as 2.8% children and 0.4% adults may display minor paroxysmal changes in absence of epilepsy.[10] The request for EEG should come from a specialist as a survey in a district hospital has revealed that as many as 56% of EEG done were unnecessary.[11]

BRAIN IMAGING

The CT scan of the brain is widely available but in absence of focal neurological signs, its yield is relatively low (4–6%).[12,13] MRI scan of the brain with appropriate sequences is the investigation of choice, but it should be ordered only by specialists in the field. In a case series of 166 patients with first unprovoked seizures, MRI was positive in 47% cases.[14]

LABORATORY TESTS

Routine blood tests like blood glucose, electrolytes, calcium, and blood counts are of clinical significance in only a small proportion of cases.[15,16] In patients with generalized tonic-clonic seizure (GTCS), serum lactate levels were higher than in patients with syncope and psychogenic nonepileptic seizures (PNES). Serum lactate levels in male patients with GTCS were higher than females. It has been suggested that a cutoff value of 2.43 mol/L may be considered appropriate to distinguish GTCS from nonepileptic events. This cutoff value was less sensitive for female patients. If the serum lactate value is determined within 2 hours from ictus, then this cutoff value can be useful in differentiating GTCS from other nonepileptic events like syncope and psychogenic nonepileptic events in male patients.[17] In addition to astute clinical observation, imaging, and EEG, serum lactate can also be a helpful diagnostic tool in assessing patients with impaired consciousness. However, this needs to be tested in larger population of patients before its routine clinical use.

SERUM PROLACTIN IN SEIZURE DIAGNOSIS

Ever since the original report by Trimble in 1978 about the role of prolactin in seizure diagnosis, it still remains unsettled. In a series of 200 patients undergoing video

JAYPEE BROTHERS

electroencephalography (VEEG) monitoring in an epilepsy clinic, serum prolactin was measured within 20 minutes of the seizure or seizure-like event. Abubakr and Wambacq found serum prolactin to be elevated in all 22 patients with GTCS, in 27 out of 32 patients with complex partial seizures (CPS) but in only 42 out of 146 patients with psychogenic seizures.[18] Sensitivity was 100% for TC seizures and 84.6% for CPS. Serum prolactin was elevated in 84.4% of cases with epileptic events, but only in 28.8% of patients with nonepileptic events. The American Academy of Neurology Technology Assessment Subcommittee reviewed 10 studies and found a sensitivity of 52.6% and specificity of 92.8% for all types of epileptic seizures. The criteria for establishing an elevated prolactin level was unclear as some studies took doubling of baseline serum prolactin values whereas others considered an absolute value of 16–45 ng/mL. The absolute value is important as doubling of value from 1 to 2 ng/mL is unlikely to be of any significance. So, ideally the serum prolactin level must double and also reach a minimum value of 15 ng/mL to be of clinical significance. Clinical conditions that interfere with prolactin levels like pregnancy and lactation and intake of neuroleptic and dopaminergic drugs should be carefully taken into account. Serum prolactin levels really do not actually provide any significant additional information and it is often the case of the glass being half full or half empty. They do not really help in distinguishing psychogenic nonepileptic events from organic ones. The serum prolactin estimation does not help in coming to a diagnosis in an epilepsy monitoring unit as the issue is usually solved with the integration of the clinical and electrophysiologic data. In some settings, the serum prolactin estimation can be of value where epilepsy is strongly considered. A negative prolactin level can be useful in an outpatient setting with suspected TC seizures. Therefore, serum prolactin estimation plays only a minor role in the diagnosis of epileptic seizures whereas an astute clinical observation and history play a far more important role. All laboratory tests with the exception of VEEG play only a minor supplementary role with false positives and false negatives and do not substitute a clinical observation which is still considered a gold standard in the diagnosis of epilepsy.

EXCLUSION OF OTHER PAROXYSMAL EVENTS MIMICKING EPILEPTIC SEIZURE

Anoxic/Hypoxic Paroxysmal Event (Syncope)

Syncope is almost 10 times more common than epilepsy.[19] This is particularly relevant in the elderly and in patients above 70 years, they have a 23% chance of having a syncope in the next 10 years.[20] A standard 12-lead electrocardiogram (ECG) is the initial investigation for the evaluation of syncope. Echocardiography is positive only in patients with a suggestive cardiac history and with abnormalities in their ECG.[21] The tilt table test can only be recommended in patients with an atypical history of loss of consciousness according to the guidelines of the European Society of Cardiology.[22] When syncope is accompanied by jerking movements, it may be confused with epilepsy. This was frequently seen in a group of 56 medical students with self-induced syncope.[23] Syncope generally has a prodromal phase of lightheadedness, gradual fading of the visual and auditory surroundings, blurred vision, and generalized weakness. The patient is usually pale with epigastric discomfort with a lot of sweating. There is no cyanosis or a rising feeling in the epigastric region as seen in seizures. There is loss of postural tone with a fall usually without injuries and a brief loss of consciousness. There may be a tonic phase and a few clonic jerks, but only after a

JAYPEE BROTHERS

BOX 2.1 Classification of syncope.

- Insufficient pumping action of the heart:
  - Arrhythmia [atrioventricular (AV) block, paroxysmal supraventricular and ventricular tachycardia, and long QT syndrome]
  - Structural cardiac disease (valvular disease, congenital heart disease, obstructive cardiomyopathy, cardiac tamponade, pulmonary embolism, and global myocardial ischemia)
- Insufficient vascular tone, leading to orthostatic hypotension:
  - Autonomic failure:
    - Primary (multiple system atrophy, pure autonomic failure)
    - Secondary (diabetic and other neuropathies)
    - Drugs (antidepressants, beta-blockers)
- Insufficient circulatory volume:
  - Hypovolemia (Addison's disease, diuretics, and hemorrhage)
- Inappropriate neural control over the circulation
  - Reflex syncope (vasovagal syncope, carotid sinus syndrome, and visceral syncope: Micturition, deglutition, glossopharyngeal, cough, Valsalva, and sneeze)

few seconds and never accompanying the fall. There may be some vocalizations and automatisms, but they are usually very brief. If there is prolonged cerebral hypoxia, there may be decorticate posturing and opisthotonos. Urinary incontinence may occur. According to Lempert's study on intentionally provoked syncope, clonic jerks are multifocal, arrhythmic, and are probably less frequent than those observed in "spontaneous" syncope. Jerking movements[24,25] range from 12 to 46% among blood donors who faint. Recovery is usually rapid and eye contact is very quickly established, but occasionally recovery may be delayed and some degree of postictal confusion may occur which may mimic a seizure. Eyes are usually open during the episode as also occurs during a seizure. However, eyes usually roll upward during a syncope whereas eyes usually turn laterally to either side during a seizure depending on the side of location of the epileptic focus. The patient may still feel very weak after recovery, look pale, and have a lot of diaphoresis. A large number of patients have precipitating factors like emotional stress, prolonged standing in a hot crowded place, carotid sinus stimulation, low salt intake or dehydration, or raised intrathoracic pressure like during coughing. The common causes of syncope are listed in **Box 2.1** and may include benign causes like vasovagal attacks or malignant life-threatening causes like dangerous cardiac arrhythmias. If the syncope occurs few moments after exercise, it may indicate reflex syncope but an attack during exercise indicates a more sinister cause like cardiomyopathy or a conduction defect. Neurally-mediated vasovagal syncope generally occurs in the upright position, but venipuncture-induced syncope can occur in supine position as well. Abdominal pain, that may be confused with epigastric aura of temporal lobe seizures, may occur at onset. Auras comprising epigastric, vertiginous, visual, or somatosensory experiences that may occur in both vasovagal and cardiogenic syncope.

Transient Ischemic Attack

A transient ischemic attack (TIA) involving the vertebrobasilar territory can involve the ascending reticular activating system and cause transient loss of consciousness. Such events are accompanied by other brainstem features like dysarthria, diplopia,

JAYPEE BROTHERS

vertigo, ataxia, or hemiparesis and be easy to distinguish. More than 75% of TIAs last longer than 5 minutes and this is longer than either a seizure or a syncope.[26]

Carotid Sinus Syncope

Carotid sinus hypersensitivity is a common cause of unexplained falls in elderly people generally above the age of 60 years. Testing for such hypersensitivity should be part of routine workup of elderly subjects with falls and transient loss of consciousness (LOC) of very brief duration. Such testing should always be done with ECG and blood pressure (BP) monitoring in a hospital setting. Some subjects with carotid sinus hypersensitivity may have falls without definite LOC where sinus pressure may occur from head turning or tight collars. Carotid sinus hypersensitivity causes peripheral vasodilatation causing hypotension as well as slowing of heart rate. Both these features need to be looked for during a carotid massage test (**Fig. 2.1**). However, such tests carry the risks prolonged asystole, transient or permanent neurological deficits, stroke, and sudden death; hence, the justification of the aforementioned warning (*see Commentary 2B*).

Long QT Syndrome

This form of cardiogenic syncope needs special mentioning as it may be associated with convulsive syncopes that cause unexplained sudden death in a young person and may closely mimic a GTCS. The condition is often familial with autosomal dominant inheritance resulting from a mutation affecting sodium or potassium channels. Syncope results from ventricular tachyarrhythmia, generally torsades de pointes triggered by fear, fright, emotionally charged exercises, and sleep. ECG is diagnostic.

Brugada syndrome is characterized by three types of ST segment anomalies and is another type of genetic ion channel disorder caused usually by SCN5A mutation; this may imitate an epileptic attack and may cause sudden death.

Such conditions highlight the need for a proper ECG recording in every subject presenting with a history suggestive of a convulsion for the first time. A recent report highlights the need for searching for occult cardiac arrhythmias (asystole/complete heart block) in some subjects presenting with intractable "epileptic seizures" with implantable loop recorder (ILR) on a long-term basis.[27]

Anoxic Epileptic Seizures

At times, not very commonly though, true epileptic seizures can be triggered by nonepileptic syncope and hence the name. This is not synonymous with reflex anoxic seizure, which is a syncope. Neurally-mediated syncope may trigger a prolonged clonic seizure with myoclonic jerks and Valsalva maneuver-induced syncope can trigger a vibratory tonic epileptic seizure in children. On the other hand, epileptic seizures may manifest with syncope-like attacks in Panayiotopoulos syndrome (epileptic seizure imitating syncope).

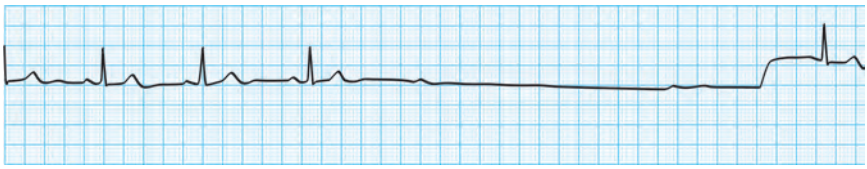

FIG. 2.1: Sinus arrest induced by carotid massage.

JAYPEE BROTHERS

Psychogenic Paroxysmal Event

Psychogenic pseudosyncope and dissociative seizures remain diagnostic challenges to general practitioners and specialists. They constitute about 30% of cases in syncope clinics and about 25% of cases who are referred for refractory epilepsy in tertiary epilepsy centers.[28-30] These events start by external or internal triggers like unpleasant people or surroundings and flashback of traumatic internal events. The prodromal phase is characterized by symptoms like tachycardia, epigastric discomfort, and difficulty in breathing with tachypnea. Such patients may have neurological symptoms like tremor, weakness, headache, or sensory changes. They may also present with pure psychogenic features like visual and auditory hallucinations, intense fright, depersonalization, dream-like states, or feeling of impending death. The patient may stare blankly, have bizarre movements, and may fall down very slowly without any injury. Unresponsiveness may be very prolonged and lasts for >10 minutes. Some patients may have pseudostatus epilepticus. Movements are asynchronous and demonstrative and usually out of phase with intermittent vocalizations. Pelvic thrusting, side-to-side head movements, and forcible eye closure are commonly seen. *La grande courbure* of Charcot or intense opisthotonos like body arching is not commonly seen nowadays. There may be quick return of consciousness after the ictus and patient may only be partially amnestic about it. Total amnesia is rare.[31] The "eye sign" is important. Convulsive movements with closed eyes are highly suggestive of PNES. Eyes are generally open during GTCS and syncope and if closed before would open during the event. The resistance offered to passive opening of eyes is also an important feature to note in psychogenic cases.

These events have been named differently, but the accepted terminology is PNES as decided by epilepsy experts. The American Psychiatric Association name them as conversion disorders [Diagnostic and Statistical Manual of Mental Disorders-IV (DSM-IV)—somatoform section].[32] The most suitable term could be dissociative convulsion. The International Classification of Diseases-10 (ICD-10) states that the common theme shared by dissociative disorders is a partial or complete loss of the normal integration between memories of the past, awareness of identity and immediate sensation, and control of body movements (World Health Organization, 1992).[33] Dissociative convulsions may begin in early life and usually begin in a specific situation caused by external (place, time, and witness) or internal triggers (flashbacks, emotions). Bowman and Markand's[34] study of 45 cases revealed that dissociative convulsions begin in the young adulthood (20–30 years of age) and are mostly seen in women (78%). Past history of a traumatic event is mentioned by 84% of patients (sexual abuse 67%, physical abuse 67%, and other trauma 73%). Psychiatric comorbidity is common. These includes somatoform disorders (89%), dissociative disorders (91%), affective disorders (64%), personality disorders (62%), posttraumatic stress disorders (49%), and other anxiety disorders (47%).[34]

Suggestive features of PNES are given in **Box 2.2**.

PAROXYSMAL EVENTS OCCURRING DURING SLEEP

Electric shock-like movements called hypnic/hypnagogic jerks/myoclonus can occur at the onset of sleep. Body rocking, head banging, or rolling can occur at the sleep-wake transition.[35] In adults above 50 years, rapid eye movement (REM) sleep

JAYPEE BROTHERS

BOX 2.2 Psychogenic nonepileptic seizures (PNES): Suggestive features.

- Atypical auras
- Preictal behavior changes
- Gradual onset
- "Pseudosleep" at onset
- Eye closure during unresponsiveness
- Eye fluttering
- Discontinuous seizure activity
- Gradual cessation
- Absence of postictal state
- High seizure frequency
- Excessive variation in seizure manifestations
- Funny vocalization
- Resistance to eye opening
- Prolonged duration
- Occurrence during clinic visits
- Suggestibility
- Precipitation of typical attack by suggestion
- Attacks only in the presence of others
- Vocalizations consisting of gagging, retching, gasping, screaming, crying, or moaning
- Emotional display during events
- Emotional triggers
- Retained consciousness and recollection of events with bilateral jerking activity

behavior disorders are seen. These conditions often resemble frontal lobe seizures and are difficult to differentiate. In the pediatric age group, sleepwalking, sleep talking, nocturnal terrors, and different types of nonrapid eye movement (NREM) parasomnias can be seen. Some motor phenomenon of different types of nocturnal seizures can mimic these various parasomnias. This could be due to cortical release of subcortical motor learned patterns during such episodes.[36] Night terrors happen in the first 3 hours of sleep, when the child suddenly wakes up from sleep, screams, and is terrified. This may last up to 10 minutes. Sleepwalking is found in children of 5–10 years of age and in the first half of sleep. The child walks about in a trance-like state with eyes often open and may wander out of the room but usually returns to bed. Several other clinical conditions may resemble epileptic events and will be discussed later on in the appropriate context. Distinctive features of sleep parasomnias and nocturnal frontal lobe epilepsy are depicted in **Table 2.1**.

CONCLUDING REMARKS

The art of listening has to be mastered in differentiating seizures from close mimics. This is time-consuming and can be acquired with practice. If a dissociative disorder is suspected, then suggestible questions like depersonalization and derealization can be helpful. Sense of panic and dissociation are common in the prodromal phase, but not often volunteered by patients.[37] Patients with a first seizure should ideally be seen by an epileptologist with experience in that field. This gives a diagnostic yield of about 96%.[38] Patient should not be treated in case of diagnostic uncertainty; it is better to adopt a policy of "wait and see". VEEG is very useful in diagnosis, particularly in dissociative seizures and a 48-hour recording may clinch the diagnosis in the majority of cases.[39] There indeed are pitfalls with this technique as well (discussed later in this volume). In difficult to diagnose cases, a combined tilt table test and carotid massaging done under EEG control may be helpful.[40,41] Provocation of a seizure by an experienced clinician under protected environment with proper counseling is accepted ethically.

JAYPEE BROTHERS

TABLE 2.1 **Sleep parasomnias and nocturnal frontal lobe epilepsy.**

Features	NREM parasomnias (somnambulism; night terrors)	Nocturnal frontal lobe epilepsy
Onset of age	<10 years	Variable: Generally childhood or adolescence
Positive family history	60–90%	<40%
Number of attacks/day	1–2	>3
Attacks/month	<1–4	20–40
Clinical course	Disappear by adolescence	Frequency generally stable
Duration of disorder	Around 7 years	Around 20 years
Duration of episodes	Seconds to 30 min	Seconds to 2–3 min
Semiology	Variable complexity	Very stereotyped on VEEG
Triggering factors	Sleep deprivation, fever, and stress	Usually none
Associated conditions	Obstructive sleep apnea	Usually none
Ictal EEG	Slow waves; no epileptiform features	Usually normal; often obscured by muscle artifacts; epileptiform features in <10%
Timing of sleep	First half of night: Generally after first 30 min	Anytime
PSG stage	Stages III–IV	Generally stage II; may be later

(EEG: electroencephalography; PSG: polysomnography; NREM: nonrapid eye movement; VEEG: video electroencephalography)

REFERENCES

1. Scheepers B, Clough P, Pickles C. The misdiagnosis of epilepsy: findings of a population study. Seizure. 1998;7:403-6.
2. Chadwick D, Smith D. The misdiagnosis of epilepsy. BMJ. 2002;324:495-6.
3. Scottish Intercollegiate Guidelines Network (SIGN). (2018). Diagnosis and management of epilepsy in adults: A national clinical guideline. [online] Available from https://www.sign.ac.uk/assets/sign143_2018.pdf. [Last accessed June, 2020].
4. Theodore WH, Porter RJ, Albert P, Kelly K, Bromfield E, Devinsky O, et al. The secondarily generalized tonic-clonic seizure: a videotape analysis. Neurology. 1994;44:1403-7.
5. Chung SS, Gerber P, Kirlin KA. Ictal eye closure is a reliable indicator for psychogenic nonepileptic seizures. Neurology. 2006;66:1730-1.
6. Hoefnagels WA, Padberg GW, Overweg J, van der Velde EA, Roos RA. Transient loss of consciousness: the value of the history for distinguishing seizure from syncope. J Neurol. 1991;238:39-43.
7. Manford M. Assessment and investigation of possible epileptic seizures. J Neurol Neurosurg Psychiatry. 2001;70:3-8.
8. King MA, Newton MR, Jackson GD, Fitt GJ, Mitchell LA, Silvapulle MJ, et al. Epileptology of the first-seizure presentation: clinical, electroencephalographic, and magnetic resonance imaging study of 300 consecutive patients. Lancet. 1998;352:1007-11.
9. Schreiner A, Pohlmann-Eden B. Value of the early electroencephalogram after a first unprovoked seizure. Clin Electroencephalogr. 2003;34:140-6.
10. Walczak TS, Jayakar P. Interictal EEG. In: Engel J, Pedley TA (Eds). Epilepsy: A Comprehensive Textbook. Philadelphia: Lippincott-Raven; 1997. pp. 831-48.
11. Smith D, Bartolo R, Pickles RM, Tedman BM. Requests for electroencephalography in a district general hospital: retrospective and prospective audit. BMJ. 2001;322:954-7.
12. Ramirez-Lassepas M, Cipolle RJ, Morillo LR, Gumnit RJ. Value of computed tomographic scan in the evaluation of adult patients after their first seizure. Ann Neurol. 1984;15:536-43.
13. Breen DP, Dunn MJG, Davenport RJ, Gray AJ. Epidemiology, clinical characteristics, and management of adults referred to a teaching hospital first seizure clinic. Postgrad Med. 2005;81:715-8.
14. Pohlmann-Eden B, Schreiner A. Epileptology of the first seizure presentation. Lancet. 1998;352:1855-6.

JAYPEE BROTHERS

15. Turnbull TL, Vanden Hoek TL, Howes DS, Eisner RF. Utility of laboratory studies in the emergency department patient with a new-onset seizure. Ann Emerg Med. 1990;19:373-7.
16. Dunn MJ, Breen DP, Davenport RJ, Gray AL. Early management of adults with an uncomplicated first generalized seizure. Emerg Med J. 2005;22:237-42.
17. Doğan EA, Ünal A, Ünal A, Erdoğan C. Clinical utility of serum lactate levels for differential diagnosis of generalized tonic-clonic seizures from psychogenic nonepileptic seizure and syncope. Epilepsy Behav. 2017;75:13-7.
18. Abubakr A, Wambacq I. Diagnostic value of serum prolactin levels in PNES in the epilepsy monitoring unit. Neurol Clin Pract. 2016;6:116-9.
19. Soteriades ES, Evans JC, Larson MG, Chen MH, Chen L, Benjamin J, et al. Incidence and prognosis of syncope. N Engl J Med. 2002;347:878-85.
20. Sararin FP, Louis-Simonet M, Carballo D, Slama S, Rajeswaran A, Metzger JT, et al. Prospective evaluation of patients with syncope: a population-based study. Am J Med. 2001;111:177-84.
21. Sarasin FP, Junod AF, Carballo D, Slama S, Unger PF, Louis-Simonet M. Role of echocardiography in the evaluation of syncope: a prospective study. Heart. 2002;88:363-7.
22. Brignole M, Alboni P, Benditt DG, Bergfeldt L, Blanc JJ, Thomsen PE, et al. Guidelines on management (diagnosis and treatment) of syncope–update 2004. Executive Summary. Eur Heart J. 2004;25:2054-72.
23. Lempert T, Bauer M, Schmidt D. Syncope: a videometric analysis of 56 episodes of transient cerebral hypoxia. Ann Neurol. 1994;36:233-7.
24. Lin JT, Ziegler DK, Lai CW, Bayer W. Convulsive syncope in blood donors. Ann Neurol. 1982;11:525-8.
25. Newman BH, Graves S. A study of 178 consecutive vasovagal syncopal reactions from perspective of safety. Transfusion. 1982;41:1475-9.
26. Warlow CP, Dennis M, van Gijn J, Hankey G, Bamford J, Sandercock P, et al. Stroke: A Practical Guide to Management, 2nd edition. Malden: Blackwell Publishing Science; 2001. pp. 28-105.
27. Kanjwal K, Karabin B, Kanjwal Y, Grubb BP. Differentiation of convulsive syncope from epilepsy with an implantable loop recorder. Int J Med Sci. 2009;6:296-300.
28. Mattson RH. Value of intensive monitoring. In: Wada HA, Penry JK (Eds). Advances in Epileptology. New York: Raven Press; 1980. pp. 43-51.
29. Gates JR, Ramani V, Whalen S, Loewenson R. Ictal characteristics of psychogenic seizures. Arch Neurol. 1985:42:1183-7.
30. Benbadis SR, O'Neill E, Tatum WO, Heriaud L. Outcome of prolonged video-EEG monitoring at a typical referral epilepsy center. Epilepsia. 2004;45:1150-3.
31. Bowman ES. Why conversion seizures should be classified as a dissociative disorder. Psychiatr Clin North Am. 2006;29:185-211.
32. American Psychiatric Association (APA). Diagnostic and Statistical Manual of Mental Disorders, 4th edition. Washington: American Psychiatric Association; 1994. p. 477.
33. World Health Organization (WHO). (1992). The ICD-10 Classification of Mental and Behavioural Disorders: Clinical Description and Diagnostic Guidelines. [online] Available from https://apps.who.int/iris/bitstream/handle/10665/37958/9241544228_eng.pdf?sequence=8&isAllowed=y. [Last accessed June, 2020].
34. Bowman ES, Markand ON. Psychodynamics and psychiatric diagnoses of pseudoseizures subjects. Am J Psychiatry. 1996;153:57-63.
35. American Academy of Sleep Medicine. The International Classification of Sleep Disorders (Revised). Chicago: American Sleep Disorders Association; 2001.
36. Tassinari CA, Rubboli G, Gardella E, Cantalupo G, Calandra-Buonaura G, Vedovello M, et al. Central pattern generators for a common semiology in fronto-limbic seizures and parasomnias. A neuroethologic approach. Neurol Sci. 2005;26:225-32.
37. Stone J, Carson A, Sharpe M. Functional symptoms and signs in neurology: assessment and diagnosis. J Neurol Neurosurg Psychiatry. 2005;76:2-12.
38. Deacon C, Wiebe S, Blume WT, McLachlan RS, Young GB, Matijevic S. Seizure identification by clinical description in temporal lobe epilepsy: how accurate are we? Neurology. 2003;61:1686-9.
39. Lobello K, Morgenlander JC, Radtke RA, Bushnell CD. Video-EEG monitoring in the evaluation of paroxysmal behaviour events: duration, effectiveness and limitations. Epilepsy Behav. 2006;8:261-6.
40. Zaidi A, Clough P, Cooper P, Scheepers B, Fitzpatrick AP. Misdiagnosis of epilepsy: many seizure-like attacks have a cardiovascular cause. J Am Coll Cardiol. 2000;36:181-4.
41. Grubb BP, Gerard G, Roush K, Temesy-Armos P, Elliott L, Hahn H, et al. Differentiation of convulsive syncope and epilepsy with head-up tilt testing. Ann Intern Med. 1991;15:871-6.

JAYPEE BROTHERS

APPENDIX 1: EPILEPSY IMITATORS

There are a range of conditions associated with recurrent paroxysmal events that may imitate and be misdiagnosed as epilepsies. It is important that these disorders are considered in the evaluation of paroxysmal events as misdiagnosis rates in epilepsy are high throughout the world. History remains the key to a correct diagnosis with video recordings that are very helpful. There are some conditions in which epileptic and nonepileptic events can coexist. The following is a list of conditions whose clinical manifestations may closely mimic those of epileptic seizures and these conditions may be designated as epilepsy imitators by the International League Against Epilepsy (ILAE) in 2017.

- *Syncope and anoxic seizures*:
  - Vasovagal syncope
  - Reflex anoxic seizures
  - Breath-holding attacks
  - Hyperventilation syncope
  - Compulsive Valsalva
  - Neurological syncope
  - Imposed upper airways obstruction
  - Orthostatic intolerance
  - Long QT and cardiac syncope
  - Hypercyanotic spells
- *Behavioral, psychological, and psychiatric disorders*:
  - Daydreaming/inattention
  - Self-gratification
  - Eidetic imagery
  - Tantrums and rage reactions
  - Out-of-body experiences
  - Panic attacks
  - Dissociative states
  - Nonepileptic seizures
  - Hallucinations in psychiatric disorders
  - Fabricated/factitious illness
- *Sleep-related conditions*:
  - Sleep-related rhythmic movement disorders
  - Hypnagogic jerks
  - Parasomnias
  - Rapid eye movement sleep disorders
  - Benign neonatal sleep myoclonus
  - Periodic leg movements
  - Narcolepsy-cataplexy
- *Paroxysmal movement disorders*:
  - Tics
  - Stereotypies
  - Paroxysmal kinesigenic dyskinesia
  - Paroxysmal nonkinesigenic dyskinesia
  - Paroxysmal exercise-induced dyskinesia

JAYPEE BROTHERS

- Benign paroxysmal tonic upgaze
- Episodic ataxias
- Alternating hemiplegia
- Hyperekplexia
- Opsoclonus-myoclonus syndrome.

- *Migraine-associated disorders*:
  - Migraine with visual aura
  - Familial hemiplegic migraine
  - Benign paroxysmal torticollis
  - Benign paroxysmal vertigo
  - Cyclical vomiting
- *Miscellaneous events*:
  - Benign myoclonus of infancy and shuddering attacks
  - Jitteriness
  - Sandifer syndrome
  - Nonepileptic head drops
  - Spasmus nutans
  - Raised intracranial pressure
  - Paroxysmal extreme pain disorder
  - Spinal myoclonus

JAYPEE BROTHERS

2A: COMMENTARY

Seizure Diagnosis and Evaluation in the Era of Coronavirus Disease 2019

Amit Halder, Ambar Chakravarty

INTRODUCTION

Coronavirus disease 2019 (COVID-19) started from the Wuhan city of China in the winter of 2019 and spreads rapidly to all the continents wrecking havoc in the form of a global pandemic. It typically presented as a severe acute respiratory syndrome or illness (SARS or SARI). The illness is caused by a highly transmissible novel zoonotic coronavirus that is phylogenetically related to the SARS-like bat virus. The virus was named SARS-CoV-2, a ribonucleic acid (RNA) virus and bat was suggested to be the primary reservoir of the virus.

The intermediate source of origin and how it got transferred to humans are yet not known. However, the virus has spread rapidly from human to human via close contact mainly through coughing, sneezing, respiratory droplets, or aerosols.[1] No effective treatment for this disease is still to emerge and vaccine development seems to be a far-fetched one. No very effective vaccine has yet been developed against any human disease caused by a RNA virus.

The classic symptoms of COVID-19 include fever, dry cough, breathlessness, and sore throat. One State Government has recently issued a notification listing 21 symptoms for which people need to seek medical advice for exclusion of COVID-19 infection. These include: "*headache, muscle pain, cold, nausea and anxiety, cough with sputum, shivers, reduction in the ability to taste and smell, cramping in hands and feet, swelling in hands and feet, swelling in thigh muscles, localized pain, issues in walking, chest pain, redness and blackening of the skin, bluishness and blackening of the skin, shoulder pain, and weakness in hands and feet*".

Coronavirus disease 2019 has also raised many interesting scientifically unanswered issues. SARS-CoV-2 is known to enter the brain, where it can bind to the enzyme, angiotensin-converting enzyme 2 (ACE2) receptor. This can cause neuronal death in the absence of encephalitis. ACE2 expression is widespread in the brain, including not only cardiorespiratory centers in the medulla, but also in the striatum.[2] There is also another receptor called TMPRSS2 to which the viral RNA can bind. The big question remains about how the virus gains access to the brain crossing the blood–brain barrier. Hematogenous or lymphatic spread seems unlikely. The most likely route seems to be transsynaptic following the course of various cranial nerves. The first one is certainly through the olfactory bulb and the tract. Passing through the lateral root of the olfactory tract, the virus may reach the temporo-hippocampal region and following the medial root, it may reach the diencephalic region. Passage to brain is also facilitated through the vagus nerve twigs innervating the lungs, with subsequent localization of viral particles in nucleus ambiguus, dorsal motor nucleus of vagus, and the neighboring cardiorespiratory center. It has been proposed that respiratory failure and cardiac arrhythmias, thus, may have a neural origin.[3] Furthermore, it has also been suggested that even at an early stage of the disease, the sensitivity of the respiratory center to falling partial pressure

JAYPEE BROTHERS

detailed information on neurology books, visit our website www.jaypeebrothers.com, for detailed information on neurology books, visit our website www.jaypeebrothers.com, for detailed information on neurology books, visit

MIMICS of Epileptic Seizures

Salient Features

- A comprehensive text addressing almost all conditions mentioned by the International League Against Epilepsy as Imitators of Epilepsy in 2017.
- A total of 22 chapters and 23 commentaries along with several illustrative case studies included.
- Practical aspects of differentiating epileptic seizures from their imitators are highlighted in problem-oriented manner.
- The commentaries provide an analytical discourse to selected issues raised by the authors in the chapters preceding them.
- Contributors include renowned neuroscientists from India and abroad.
- Suitable for general neurologists, epileptologists, physicians, pediatricians, psychiatrists, and trainees in "medicine, neurology, pediatrics, and psychiatry".
- Several interesting videos of unusual seizures and seizure lookalike have been incorporated.

Ambar Chakravarty is presently working as an Honorary Professor of Neurology and Emeritus Consultant at the Vivekananda Institute of Medical Science, Kolkata, West Bengal, India. He is a recipient of several awards and prizes including the Dr B C Roy National Award Fellowship of the Medical Council of India and awards from the Migraine Trust of London. He is a Fellow of The Royal Colleges of Physicians of London and Edinburgh, Royal College of Physicians and Surgeons of Canada, and the Indian Academy of Neurology. In addition to extensive training in Clinical Neurology in India and UK, he worked as a Research Fellow at Sunneybrook Hospital, Toronto, Canada (1984), and obtained the Sanofi Travelling Fellowship in Pediatric Neurology to work at Newcastle General Hospital, Newcastle upon Tyne, UK (1989). He had published extensively in national and international peer-reviewed journals, had been the Editor-in-Chief of Frontiers in Neurology (2012–2016), written nine monographs on Neurological Topics, and had delivered around 20 Orations so far. A recipient of Lifetime Achievement Awards from various organizations including the Madras Neuro Trust and his alma mater Medical College, Kolkata, Dr Chakravarty's research interests lie in Headaches, Epilepsy, Ataxias, Neuro-ophthalmology, Vestibular disorders, Neuroscience, and Art. He is the former President of the Indian Academy of Neurology (2005–2006). He is an avid art lover, a collector, and an art critic.

Available at all medical bookstores
or buy online at www.jaypeebrothers.com



JAYPEE BROTHERS
Medical Publishers (P) Ltd.
www.jaypeebrothers.com

Join us on facebook.com/JaypeeMedicalPublishers

Shelving Recommendation
NEUROLOGY

