ion on surgery books, visit our website www.jaypeebrothers.com, for detailed information on surgery books, visit our website www.jaypeebrothers.com

Indian Association of Endocrine Surgeons

IAES

Textbook of Endocrine Surgery

Editor-in-Chief
Amit Agarwal

Editors
Roma Pradhan
Dhalapathy Sadacharan
Anand Kumar Mishra
Deepak Abraham





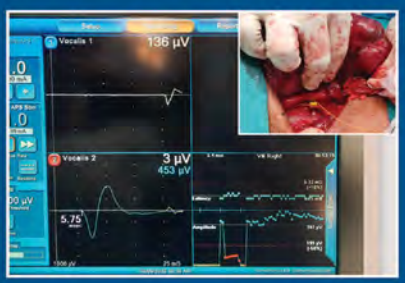



Forewords
Gerard M Doherty
Sivapatham Vittal

JAYPEE

Contents

1. **Applied Embryology and Surgical Anatomy of the Endocrine Glands** 1
   Chakravarthy Marx Sadacharan
2. **Endocrine System Physiology** 17
   Sabaretnam M, Poongkodi K, Uma Devi, Prateek Mehrotra
3. **Thyroid Function Tests and their Interpretation** 33
   Sushil Gupta, Rekha Singh
4. **History Taking and Clinical Examination of Goiter** 37
   Anand Kumar Mishra, Kul Ranjan Singh, Loreno E Enny, Surabhi Garg
5. **Solitary Thyroid Nodule** 44
   Ranil Fernando
6. **Euthyroid Multinodular Goiter** 50
   Muthukumar S, Mohamed Salmon M, Ravikumar
7. **Retrosternal Goiter** 55
   Han Boon Oh, Rajeev Parameswaran
8. **Thyroiditis** 63
   Pradeep PV
9. **Toxic Goiter-Toxic Multinodular Goiter and Toxic Adenoma** 66
   Ravikumar, Muthukumar S
10. **Graves' Disease** 70
    Supriya Sen, Deepak Abraham, Maruthu Pandian, Kamaludeen, S Babu
11. **Thyroglossal Duct Cyst and Fistula** 76
    Mohanty Biswa N, Kailash C Mohapatra, Mohanty Arun K
12. **Differentiated Thyroid Cancer** 81
    Roma Pradhan, Amit Agarwal
13. **Follicular Neoplasm of the Thyroid Gland** 113
    Natarajan Dorairajan, Poongkodi K
14. **Hürthle Cell Neoplasm and Carcinoma** 122
    R Dayananda Babu, Deepak Paul
15. **Medullary Thyroid Carcinoma** 127
    Radan Dzodic, Nada Santrac
16. **Poorly Differentiated Thyroid Carcinoma** 148
    Manohar H Martis, Elanthenral Sigamani, Deepak Abraham
17. **Anaplastic Thyroid Carcinoma** 154
    Dhalapathy Sadacharan, Sabaretnam M, Siddhartha Chakravarthy N
18. **Thyroidectomy** 159
    Anand Kumar Mishra, Kushagra Gaurav

19. Surgery in Locally Advanced Thyroid Cancer 169
Gouri Pantvaidya, Karthik Rao, Anil D'Cruz

20. Newer Technology in Thyroid Surgery 178
Roma Pradhan, Amit Agarwal

21. Neck Dissection in Differentiated Thyroid Cancer 189
Neeti Kapre, Madan Kapre

22. Principles of Neck Dissection in Medullary Thyroid Cancer 194
Aarathi Vijayashanker, Kushagra Gaurav, Akshay Anand, Abhinav Arun Sonkar

23. Complications of Thyroidectomy 201
Gyan Chand, Sudhi Agarwal

24. Voice Changes Following Thyroidectomy 209
Alok Thakar, R Chandra Shekar Reddy, Harsha Yadav CT

25. Genetic Landscape and Molecular Mechanisms in Thyroid Cancer 216
Nelson George, Amit Agarwal

26. Primary Hyperparathyroidism 225
Julie A Miller, Edwina C Moore

27. Parathyroid Surgery 238
Roma Pradhan

28. Secondary and Tertiary Hyperparathyroidism: An Endocrine and Renal Perspective 247
Manju Chandran, Jiunn Wong

29. Parathyroid Carcinoma 257
Sai Krishna Vittal, Sai Vishnupriya Vittal, V Sucharitha, Sivapatham Vittal

30. Adrenal Incidentaloma 262
Jnaneshwari Jayaram, Chitresh Kumar

31. Primary Hyperaldosteronism 274
Farheen Khan, Dileep Ramesh Hoysal, Sushohbhan Pradhan, Yuvraj Devgan, Sarah Idrees, Arjun Raja A, Amit Agarwal

32. Adrenal Surgery and Cushing's Syndrome 285
MJ Paul, Aravindan Nair

33. Pheochromocytoma 292
Deependra Narayan Singh, Amit Agarwal

34. Adrenocortical Carcinoma 305
Sendhil Rajan, Dhalapathy Sadacharan, Aromal Chekavar S

35. Techniques of Adrenalectomy and Approaches 313
Siddhartha Chakravarthy N, Anukriti Sood

36. Pediatric Endocrine Tumors 321
Himagirish K Rao, Sapana Bothra Jain

37. Insulinoma 351
Anish JC, MJ Paul

38. Familial Endocrine Syndromes 364
Mallika Dhanda, Suneel Mattoo, Amit Agarwal

39. Laboratory Evaluation of Endocrine Tumors 378
Pooja Ramakant, Manish Gutch, Chanchal Rana, Shreyamsa M, Sasi Mouli

40. Endocrine Radiology 405
Archana Gupta, Pankaj Sharma

41. Pathology of Diseases of Endocrine Organs 421
Suvradeep Mitra, Niraj Kumari, Munita Menon Bal, Santosh Menon, Narendra Krishnani

42. Role of Nuclear Medicine in Endocrine Surgery 449
CS Bal, Saurabh Arora

43. Anesthesia for Endocrine Surgery 470
Shilpi Misra, Deepak Malviya

44. Role of Radiotherapy in Endocrine Tumors 485
Punita Lal, Shagun Misra, Sidharth Pant, Shaleen Kumar

45. Thymectomy for Myasthenia Gravis 494
Surendra Kumar Agarwal

Index 503

CHAPTER 4

History Taking and Clinical Examination of Goiter

Anand Kumar Mishra, Kul Ranjan Singh, Loreno E Enny, Surabhi Garg

INTRODUCTION

Pathologies of the thyroid are associated with many symptoms and signs, some of which are quite specific. A thorough elucidation of history and examination of patient is of prime importance in guiding the further management of presenting patients. History comprises presenting symptoms, details of development of symptoms, and significant personal or family history.[1]

AGE

Age of the patient has a significant effect on reaching the probable diagnosis. Dyshormogenetic goiters and thyroglossal cyst are usually evident in the first decade of life. Physiological goiters occur in pubertal age group and childbearing age. Multinodular goiters, solitary nodule, or colloid goiters can occur at any age but are common in second and third decades. The probability of nodule harboring a malignancy is higher in children and older adults. Anaplastic cancers are usually diagnosed in older individuals. Graves' disease is more common in younger individuals. Hashimoto's thyroiditis is commonly encountered in middle-aged women.

SEX

Majority of endocrine disorders occur in women and so do thyroid disorders. Thyroid nodules in males are more likely to be malignant but overall thyroid cancers are more common amongst women.

OCCUPATION

Radiation exposure, stressful jobs, mining industry, and those exposed to perchlorates are amongst the more common occupational hazards associated with thyroid disorders and should be enquired for.[2]

RESIDENCE

Gangetic plains, mountainous regions, and coastal regions of our country have a higher incidence of goiter. This has been attributed to low iodine in the food chain due to deficiency of iodine in soil and water of the region. Higher radiation from thorium-containing sands of Kerala has been told to be responsible for increasing incidence of thyroid cancer in the region but no causative role has been proven till date.[3] Increased autoimmunity to thyroid antigens resulting in thyroiditis has occasionally attributed to increasing iodine in the diet.

Symptoms of thyroid hormone excess or deficiency: A detailed history regarding presence of symptoms of hypo- or hyperthyroidism should be elicited. Each individual symptom has varying incidence, sensitivity, and specificity for suspecting altered thyroid function. Many of them are very subjective and presence of more than one discriminatory symptom of thyroid hormone deficiency/excess are likely to clinch the diagnosis. History of urticaria, pruritis, vitiligo, eczema, and connective tissue disorders may be seen in autoimmune thyroid diseases.

LOCAL SYMPTOMS AND SIGNS

Swelling

Onset, duration, pattern of progress, associated pain and cervical lymph nodes, and swelling elsewhere in the body should be probed in detail as they provide important clues to the diagnosis. Onset of diffuse thyroid swelling with symptoms of thyrotoxicosis points toward Graves' disease or thyroiditis. Concomitant appearance of eye signs would help clinch the diagnosis of Graves' disease. The rate of progress in size of thyroid nodule is usually misleading. A malignant nodule increases in size more rapidly, but a significant proportion are notorious for gradual increase in size and often remain static in size for variable periods. Poorly differentiated thyroid carcinoma (PDTC) and anaplastic thyroid carcinoma (ATC) are usually characterized by extremely rapid progress.

Association with Pain

Thyroid swellings are usually painless; however, a painful diffuse swelling is likely to be because of thyroiditis. A rapidly progressing painful thyroid swelling may be because of bleed into a thyroid nodule, a de novo ATC or transformation into anaplastic variant of thyroid carcinoma. Thyroid abscess though extremely rare presents with swelling, pain, and fever.

Compressive Features

Compression on the trachea, esophagus, and recurrent laryngeal nerves (RLNs) may occur during the course of

JAYPEE BROTHER

thyroid pathology. The compressive features may not correlate with the size of the thyroid mass. A large mass that is located anteriorly may be totally asymptomatic whereas a small nodule that is located posteriorly may cause symptomatic compression on the RLN and esophagus. A malignant mass is more likely to have compressive features.

- *Recurrent laryngeal nerve*: Voice changes are not uncommon in thyroidal illnesses and are important clinical pointers. A recent change in voice quality should raise the suspicion of malignant etiology or transformation. Benign nodules/goiters because of their location or sheer size may cause voice changes.

  Voice changes may occur because of alterations in functional status of thyroid. Hoarseness with or without loss of range of voice is an important feature of hypothyroidism. Thyroid hormone excess may result in hoarseness due to abnormal movements of vocal cords.[4]
- *Esophagus*: Globus pharyngeus and progressive difficulty in swallowing may be encountered in many patients. This is said to be more common in left-sided pathology. Often the patient may not appreciate the symptoms distinctly as the changes occur gradually and are subtle.
- *Tracheal compression*: A greater than two-thirds luminal compromise of the trachea is required to have significant respiratory complaints or stridor. Many describe it as a choking sensation. Presence of a retrosternal component is likely making the patient more symptomatic and very often the symptoms have a positional variation.

RISK FACTORS

The location of thyroid gland predisposes to it increased ill effects of radiation exposure. Increased radiation exposure from the environment or diagnostic procedures has been linked to increased incidence of thyroid cancer albeit in a small number.[2] The effect is more pronounced if the exposure occurred at a young age.

Level of iodine intake affects thyroid function. Deficiency of iodine association is an established cause of goiter. A few epidemiological studies have shown temporal association with iodine excess and thyroid carcinoma and autoimmune thyroid disorders.[5] More follicular carcinomas are seen in iodine deficient areas and papillary subtypes in iodine-rich areas.

Prospective cohort studies and observational studies have shown association between obesity, diabetes, and thyroid cancer. Women account for almost three-fourths of all thyroid cancer patients; however, there is no evidence that links thyroid cancer to estrogen.

Hashimoto's thyroiditis has been associated with increased incidence of thyroid cancers (PTC and lymphomas); however, a causal relationship has not been proven. An association of thyroid cancer and hepatitis C virus (HCV) and hepatitis B virus (HBV) has been seen of late.

Past History

Eliciting relevant past history gives relevant information about the course of the disease and its response to treatment received till date. Certain drugs have been classified as goitrogens. Information on previous hospitalizations/surgery/response to anesthesia, and presence of chronic conditions such as asthma, hypertension, ischemic heart disease, tuberculosis, etc., give us important information on perioperative risk assessment and help plan better.

Family History[6]

Differentiated thyroid carcinomas (DTCs) account for >85–90% and <5% are familial but medullary thyroid carcinomas (MTC) account for <5% of all thyroid cancers but 25% are familial. There is a 2–10-fold higher risk of sporadic DTC in presence of family history of thyroid cancer. MTCs are associated with MEN 2a/MEN 2b and familial MTC. Familial adenomatous polyposis (FAP), PTEN hamartoma tumor syndrome, Cowden's syndrome, Carneys complex, Pendred's syndrome, and Werner syndrome have predominance of no thyroidal syndromes with minimal increase in incidence of thyroid lesions. Familial syndromes characterized by predominance of papillary thyroid carcinoma (PTC) also occur such as pure familial PTC (fPTC), fPTC associated with papillary renal cell carcinoma, and fPTC with multinodular goiter. Hashimoto's thyroiditis, Graves' disease, and benign goiters also have shown familial association and same should be enquired for.

Personal History

Information regarding presence of alcohol, tobacco, and smoking should be sought in all patients.[7] No causal associations have been proven till date. Alcohol causes direct cellular toxicity in thyroid gland and also affects the neuroendocrine axis bringing about complex poorly understood changes. Moderate alcohol consumption has been associated with reduce in incidence of autoimmune thyroid diseases, goiter, and thyroid carcinoma.

Smoking increases the serum concentration of thiocyanates and has shown to increase the thyroid volume. Thiocyanates have a T1/2 of >5 days and inhibits iodine uptake by the thyroid, interferes with organification process, and increases iodine excretion by the kidney. However, it has not shown to affect the rate of progression of thyroid nodule growth. The adverse effects of smoking in thyroid has been more pronounced in iodine deficient population. Smoking has surprisingly shown association with reduced incidence of DTC.

Dietary History[8]

Many food items have been said to act as goitrogens if it forms a staple part of the diet. Hence, a detailed dietary history may give information about the probable etiology. Cassava (tapioca), lima beans (sem), sorghum, flax seeds, and sweet

JAYPEE BROTHER

potato (shakarkand) are popular foods in our country which have cyanogenic glucosides which interferes with iodine uptake. Glucosinolates found in cruciferous vegetables like cabbage, cauliflower, broccoli, turnips, and rapeseeds also interfere with iodine uptake by the thyroid. Peroxidase activity is compromised by soy products and millets. Deficiency of iron, vitamin A, selenium, and increased dietary nitrates also predisposes to goiter formation by various mechanisms, if severe.

EXAMINATION[9]

Examination of the patient starts with inspection followed by palpation. A normal thyroid gland is often difficult to see or palpate. A swelling in the region of thyroid that moves with deglutition is likely to be a thyroid or arising from the thyroid barring a few exceptions like central compartment lymph node, etc.

The entire gland is palpated from the front and standing behind the patient. Palpation from behind is useful in those with a heavy neck. Turning the patients head to the side of palpation relaxes the sternocleidomastoid and increases the accuracy of palpatory findings. The act of swallowing during palpation elevates the gland upward against the fingers and small nodules become more evident and helps define the lower border and rule out retrosternal extension.

Inspection

With the patient seated upright and the neck in slight extension, the anterior and lateral aspect of neck is observed. A normal thyroid is butterfly shaped and is normally not visualized or palpated unless the individual is of very thin built. A normal-sized thyroid but high lying in a thin individual with long neck is often perceived as a goiter. Other causes of pseudogoiter include lipomas and pharyngeal diverticula. Rarely, a normal thyroid in an individual with increased lordosis of cervical spine may be visible or palpable. This has been termed Modigliani syndrome.

- *Size, shape, and location*: The thyroid swelling is described as diffuse/localized, uninodular/multinodular. Uninodular or solitary and multinodular swellings can be unilateral/bilateral. The sternocleidomastoids are used as lateral landmarks and hyoid prominence and suprasternal notch as superior and inferior landmarks, respectively to describe the extent of mass. A note should be made on the presence of swelling on the lateral side of the neck which are likely to be lymph nodes.
- *Surface*: The surface is typically smooth in a diffuse goiter (physiological goiter, Graves' disease, thyroiditis) or a uninodular goiter. A multinodular goiter is characterized by nodular/bosselated surface.
- *Border*: Benign swellings usually have well-defined borders whereas malignant lesions are often characterized by irregular/indistinct borders.
- *Skin over the neck*: Redness and edema of overlying skin may denote an inflammatory etiology. A scar may suggest a previous intervention. Sinuses in the anterior aspect of neck with history of swelling that burst open may suggest a thyroglossal cyst and sinus. Dilated veins over the swelling and in neck and anterior chest wall may suggest a malignant etiology. Ulceration and fungation of overlying skin may occur due to pressure necrosis in large benign masses or skin involvement in malignancy.
- *Movement with deglutition and protrusion of tongue*: A thyroid swelling or any node attached to it would move with swallowing at the thyroid gland is attached to the laryngeal framework by the ligament of berry which is a condensation of the pretracheal fascia and attaches to the cricoid and first tracheal ring. A note should be made to visualize the lower border of the thyroid on deglutition. The movement of the swelling with protrusion of tongue should be ascertained to rule out thyroglossal cyst/fistula because of its attachment with thyroglossal tract and base of the tongue.

Palpation

The inspectory findings are confirmed on palpation. Thyroid can be palpated from front and back but is best palpated from the back with the neck slightly flexed using the pulps of fingers **(Fig. 1)**. The neck can be tilted to the side of palpation to relax the ipsilateral sternocleidomastoid muscle. Occasionally, additional palpation of a nodule in an extended neck may be more informative. Temperature and tenderness are looked for followed by size, shape, extent of swelling, borders, surface, fixity of skin, mobility, and consistency. The thyroid surface appears smooth in physiological goiters and primary thyrotoxicosis. Surface is bosselated in multinodular goiter. Consistency of the nodule can be deceiving. Malignant nodules feel hard to touch but benign tense cystic nodules of long-standing calcified benign goiter may feel hard. Follicular carcinomas are usually not



Fig. 1: Palpation of thyroid gland.

JAYPEE BROTHER

hard on palpation. Restricted mobility of the thyroid mass is suggestive of infiltrative pathology due to malignancy or inflammation. Inability to palpate the lower border of thyroid suggests the possibility of retrosternal extension of the thyroid mass.

Cervical lymph nodes: A sequential spread of thyroid cancers like PTC/MTC occurs to various lymph node stations in the neck. Level 6 (central compartment) is the first lymph node basis followed by level 2/3/4 to be involved. Levels 1 and 5 are rarely involved. Lymph nodal spread in follicular thyroid carcinoma (FTC) is rare. The lymph node stations, number, size, margin, consistency, mobility, tenderness, and matting should be described. Additional lymph nodal basins like axillary and inguinal should be examined also. Delphian lymph node lies anterior to cricothyroid ligament. This node may be involved in thyroid cancer, thyroiditis, etc.

Examination of trachea: The lower part of cervical trachea is palpable in the suprasternal notch. This may be shifted to one side by unilateral swellings or may be central in bilateral involvement of the thyroid. This test is performed by standing in front of the patient with the index and ring fingers on the sternoclavicular joints and running down the trachea with the middle finger **(Fig. 2)**.

Additional maneuvers in inspection and palpation:

- *Pizzillo's method*: Thyroid can be made more prominent for inspection in obese and short-necked individuals by asking them to extend the neck against their hand placed behind the head **(Fig. 3)**.
- *Lahey's method*: This maneuver is performed from the front of the patient. To palpate the right lobe, the thyroid gland along with the laryngotracheal complex is pushed to the right with the left hand and simultaneously palpating the right lobe with left hand **(Fig. 4)**.
- *Crile's method*: Subtle enlargements of thyroid or smaller nodule/nodules can be appreciated by placing the thumb on the thyroid gland and asking the patient to swallow. The nodule moves against the thumb. The method is more useful for small nodules located in the tracheoesophageal groove. The examiner needs to sit in front of the patient and place both thumbs on either side of the airway and asked the patient to deglutition **(Figs. 5A and B)**.
- *Kocher's test*: This test is done by fixing the thyroid and laryngotracheal complex with one hand and compressing the thyroid lobe with the opposite hand on the other side. Development of stridor signifies presence of incipient critical tracheal narrowing because of the thyroid swelling. Scabbard trachea is the approximation of the lateral walls of the trachea due to compression and is a radiological sign. A positive Kocher's sign is not synonymous with tracheomalacia which is an intraoperative finding **(Fig. 6)**.



Fig. 2: Palpation of trachea.



Fig. 3: Pizzillo's method.



Fig. 4: Lahey's method.

- *Berry's sign*: Palpate for the carotid pulsation. It is normally felt in the anterior triangle against the transverse process of the cervical vertebrae one at a time. The common carotid artery usually divides at the level of upper border of the lamina of the thyroid cartilage (C4). This may be

JAYPEE BROTHER



Figs. 5A and B: Crile's method.

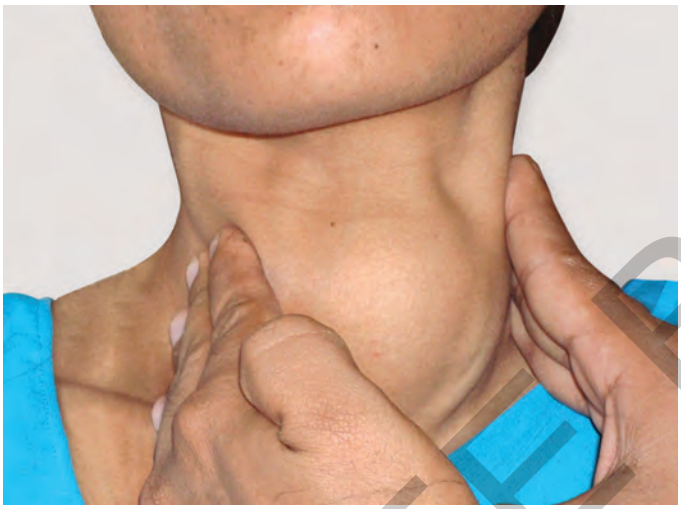

Fig. 6: Kocher's test.



Fig. 7: Berry's sign.

shifted laterally in large benign goiters or may be absent if engulfed/encased by a malignant lesion (Positive Berry's sign) **(Fig. 7)**.

- *Horner's syndrome*: Thyroid masses may compress or infiltrate the cervical sympathetic chain resulting in Horner's syndrome which is characterized by ipsilateral miosis, enophthalmos, ptosis, and anhidrosis (absence of sweating on the affected side of the face). These findings can be elicited as a part of history/inspection.

Percussion over Manubrium Sterni

Percussion over the manubrium sterni normally has a tympanic note. A dull note on percussion suggests retrosternal extension of the thyroid mass/lymph nodes. An individual in whom the lower extent of thyroid mass can be palpated but percussion over manubrium sterni is dull should raise the suspicion of possibility of coexisting detached thyroid nodule, coexistent mediastinal goiter, or enlarged superior mediastinal nodes **(Fig. 8)**.



Fig. 8: Percussion over manubrium sterni.

Thrill and Bruit

Thyroid is a very vascular organ and its vascularity is increased manifolds in toxicity and malignancy. The increased vascularity can be appreciated by a palpable thrill and an

JAYPEE BROTHER

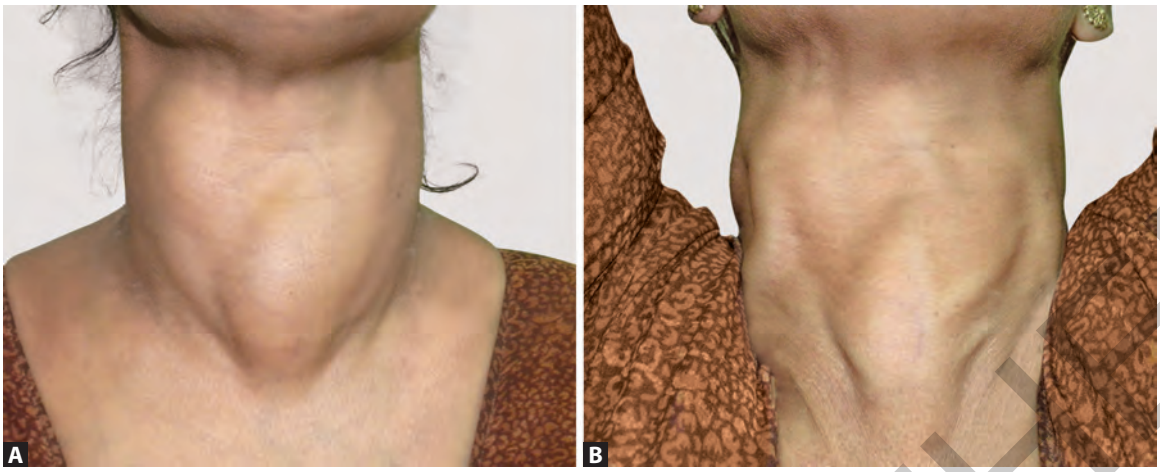

Figs. 9A and B: Pemberton's sign.

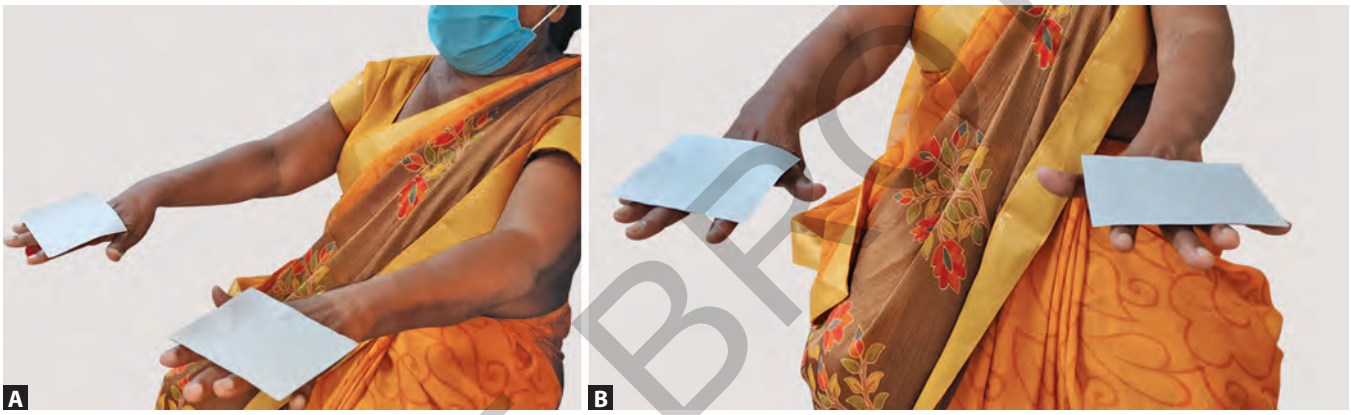

Figs. 10A and B: Examination for hand tremors.

auscultatory bruit in the region of superior pole of the thyroid gland.

Pemberton's Sign[10]

This sign is elicited in case of a goiters with retrosternal extension by asking the patient to raise both his arms overhead with at the arms touching the sides of head for a minute. A positive Pemberton's sign is characterized by the appearance of facial plethora, vascular engorgement, cyanosis, or distress. The vascular compression occurs has been shown to occur because of the medial and inferior movement of lateral (acromial) end of clavicle rather than cork effect brought about by the craniocaudal movement of the thyroid or upward movement of the thoracic inlet **(Figs. 9A and B)**.

GENERAL EXAMINATION

Thyroid Dermopathy[11]

Skin changes (dermopathy) can occur in those with Graves' disease with ophthalmopathy and rarely in chronic autoimmune thyroiditis. Classical pretibial myxedema is characterized by diffuse nonpitting pedal edema with orange peel appearance most commonly in the anterior aspect of shin but can occur elsewhere. Plaques and nodules can also occur.

Thyroid acropachy is a rare manifestation of autoimmune thyroid disorders and consists of clubbing and swelling of digits along with periosteal reaction of extremity bones.

Skin and hair changes commonly occur in both hypo- and hyperthyroidism and should be looked for.

Cardiovascular System

This is of great importance in toxic patients. Pulse rate and character should be examined. A collapsing pulse which may be of water hammer in character due to wide pulse pressure is seen. A sleeping pulse rate gives more accurate information. Hyperdynamic apex along with apical systolic murmur is often seen in toxic patients. Atrial fibrillation should be looked for.

Tremors

This is checked in outstretched hands with fingers widely spaced. A small sheet of paper may be placed on the hand to make it more obvious. The tremors in hyperthyroidism are typically low amplitude with a high frequency often described as fine tremors. This can also be elicited in the tongue **(Figs. 10A and B)**.

JAYPEE BROTHER

Table 1: Clinical signs of Graves' orbitopathy.

Sign	*Description*
Dalrymple's	Upper eyelid is at a higher than normal position (upper sclera visible)
Von Graffe's	Upper eyelid cannot keep pace with downward gaze
Joffroy's	Absence of forehead creases on upward gaze
Stellwag's	Incomplete and infrequent blinking
Moebius	Failure of convergence of eyeballs
Becker's	Abnormal intense pulsation of retinal arteries
Boston's	Jerky movements of upper eyelid on downward gaze
Cowen's	Extensive hippus of consensual pupillary reflex
Enroth's	Upper eyelid edema
Gifford's	Difficulty of upper eyelid eversion
Griffith's	Lower lid lag on upward gaze
Hertoghe's	Loss of lateral eye brows
Jellinek's	Hyperpigmentation of superior eyelid folds
Kocher's	Spasmatic retraction of upper eyelid on gaze fixation
Riesman's	Bruit over the eyelid
Suker's	Inability to maintain fixation on fixation in extreme lateral gaze

Ophthalmopathy

The symptoms of hypothyroidism are usually distinct from hyperthyroidism but occasionally patients of hyperthyroidism may present with weight gain due to excessive eating.

Older patients of hyperthyroidism may present with symptoms like apathy/depression, breathlessness, worsening angina, and congestive heart failure which are not very characteristics of hyperthyroidism. This has been often referred to apathetic hyperthyroidism.

Eye involvement is common in thyrotoxicosis. Presence of diffuse goiter with ophthalmopathy is pathognomonic of Graves' disease and this combination obviates the need of specialized tests for diagnosis. Certain signs like staring look and lid retraction which are caused by sympathetic overactivity can be seen in any case of thyrotoxicosis. However, orbitopathy is limited to cases of Graves' disease and this leads to irritation, excessive tearing, eye/retro-orbital discomfort, conjunctival injection, blurred vision, diplopia, proptosis, and loss of vision in neglected cases. Symptoms of orbitopathy are subjective whereas signs are often objective. These subjective symptoms and signs of Graves' ophthalmopathy can be graded as NO SPECS, Clinical Activity Score (CAS), VISA (vision, inflammation, strabismus, appearance), and EUGOGO (European Group of Graves' Orbitopathy) classifications.

The various clinical signs of Graves' orbitopathy are as shown in **Table 1**.

Trousseau's and Chvostek's sign: This should be elicited preoperatively in any patient likely to undergo total thyroidectomy as these important clinical signs of hypocalcemia may be present in some individuals in normocalcemia also.

CONCLUSION

The importance of elaborate history and detailed examination is of prime importance in management of patients with a thyroid pathology. It helps us to formulate an appropriate diagnostic and treatment algorithm for a patient.

REFERENCES

1. Das S. Examination of thyroid gland. A Manual on Clinical Surgery, 12th edition. Kolkata: S Dass Publishers; 2008.
2. Aschebrook-Kilfoy B, Ward MH, Della Valle CT, Friesen MC. Occupation and thyroid cancer. Occup Environ Med. 2014;71(5):366-80.
3. Aravindam KP. Papillary thyroid cancer: Why the increase and what can be done? Indian J Cancer. 2017;54(3):491-2.
4. Hari Kumar KV, Garg A, Ajai Chandra NS, Singh SP, Datta R. Voice and endocrinology. Indian J Endocrinol Metab. 2016;20(5):590-4.
5. Zimmermann MB, Galetti V. Iodine intake as a risk factor for thyroid cancer: a comprehensive review of animal and human studies. Thyroid Res. 2015;8:8.
6. Nosé V. Familial thyroid cancer: a review. Mod Pathol. 2011;24(2):S19-S33.
7. Liu Y, Su L, Xiao H. Review of factors related to the thyroid cancer epidemic. Int J Endocrinol. 2017;2017:5308635.
8. Choi WJ, Kim J. Dietary factors and the risk of thyroid cancer: a review. Clin Nutr Res. 2014;3(2):75-88.
9. Sreeharan V. Examination of the thyroid gland and thyroid status. J Clinical Exam. 2007;3:1-7.
10. De Filippis EA, Sabet A, Sun MR, Garber JR. Pemberton's sign: exlained nearly 70 years later. J Clin Endocrinol Metab. 2014;99(6):1949-54.
11. Singla M, Gupta A. Nodular thyroid dermopathy: not a hallmark of Graves' disease. Am J Med. 2019;132(3):e521-2.

JAYPEE BROTHER

detailed information on surgery books, visit our website www.jaypeebrothers.com, for detailed information on surgery books, visit our website www.jayp

IAES Textbook of Endocrine Surgery

Salient Features

- Comprehensive book with 45 chapters written by International and National experts of Endocrine Surgery
- Includes the chapters on Applied Endocrine Physiology and Anatomy
- Provides the chapters on important allied subjects such as Endocrine Pathology, Radiology, Radiotherapy, and Nuclear Medicine
- Comprises the detailed chapter on Modern Technology for Endocrine Surgery
- Well-illustrated chapters with photographs, radiographic images, flowcharts, and diagrams
- Each chapter ends with clinical pearls to guide the clinicians and allied specialists
- An ideal reference book for surgical postgraduates, MCh students of endocrine surgery, head and neck surgery and surgical oncology.

About the editors

Amit Agarwal is working as a Professor and Head, Department of Endocrine Surgery, Sanjay Gandhi Postgraduate Institute of Medical Sciences (SGPGIMS), Lucknow, Uttar Pradesh, India, a premier University Teaching Hospital of India. He completed his training in General Surgery from Ganesh Shankar Vidyarthi Memorial (GSVM) Medical College, Kanpur and then trained in Endocrine Surgery at SGPGIMS. He has visited various endocrine surgery centers in US, Europe and Japan. He has also served as a Commonwealth Fellow in Oxford, UK and is the recipient of the prestigious International Guest Scholarship of American College of Surgeons. Currently, he runs an academic program in Endocrine Surgery with 4 positions of MCh fellows who undergo rigorous 3 years training in Endocrine Surgery. Till date, he has trained and guided more than 44 trainees who are now themselves leading endocrine surgeons in different parts of the country. He has provided leadership to many prestigious societies in the capacity of the President of ISOPES, Indian Association of Endocrine Surgeons (IAES) and Indian Thyroid Society (ITS) as well as Council Co-ordinator of International Association of Endocrine Surgeons and Asian Association of Endocrine Surgeons. He is practicing and teaching Endocrine Surgery for the last 25 years and is one of the senior-most dedicated endocrine surgeons in the country. He is the pioneer of Robotic Surgery in the state of UP. He has also mastered and popularized various new techniques such as the use of ICG for identification of parathyroids and use of neuro-monitoring for safe thyroid surgery. He is currently performing state-of-the-art endocrine surgical procedures including robotic thyroidectomy, thymectomy and adrenalectomy. He has published more than 200 peer-reviewed papers and has authored and edited many books and book chapters. He is the founding Editor-in-Chief of World Journal of Endocrine Surgery, the only dedicated endocrine surgery journal worldwide.

Roma Pradhan, is a formally trained Endocrine and Breast Surgeon having received MCh degree in Endocrine Surgery from SGPGIMS, and is presently working as an Associate Professor and Head, Department of Endocrine Surgery, Ram Manohar Lohia Institute of Medical Sciences (RMLIMS), Lucknow, Uttar Pradesh, India, one of the only 5 academic centers of Endocrine Surgery in the country. She has been actively contributing to the specialty of endocrine surgery by way of numerous peer-reviewed articles, awareness lectures, talks and presentations in various international and national meetings of important societies. She has been invited to write numerous book chapters for widely read books of endocrine surgery. She received the best Indian Journal of Endocrinology and Metabolism (IJEM) Award 2019 for Best Review Article. She has been able to establish a full service and academic department of endocrine surgery at RMLIMS. She is a pioneer in using continuous neuro-monitoring for safe thyroid surgery especially in large goiters.

Dhalapathy Sadacharan after receiving his MCh degree from SGPGIMS, is working as Professor and Head, Department of Endocrine Surgery, King George's Medical University, Lucknow, Uttar Pradesh, India. He guides and trains 2 students of MCh every year. He is also associated as Senior Consultant in Apollo Hospitals, Vijaya Hospital and Kauvery Hospitals, Meenakshi Hospital, and Sooriya Hospitals, Chennai, Tamil Nadu. He has been a Speaker and Faculty in various national and international forums of Endocrine Surgery (100 Conferences) and performed live surgical demonstrations at various general surgical forums. He has won numerous awards and has many peer-reviewed articles to his credit.

Anand Kumar Mishra, is an illustrious alumnus of SGPGIMS, being the first MCh in Endocrine Surgery of the country. He is Professor and Head, Department of Endocrine Surgery, King George's Medical University, Lucknow, Uttar Pradesh, India and supervises 2 MCh candidates in Endocrine Surgery every year. He has published extensively and has edited a book on endocrine surgery. He has delivered numerous lectures in international and national forums and has held important positions in Association of Surgeons of India, Indian Association of Endocrine Surgeons and Association of Breast Surgeons of India.

Deepak Abraham currently serves as the Professor, Department of Endocrine Surgery, Christian Medical College, Vellore, Tamil Nadu, India, after completing a term as the Head, Department of Endocrine Surgery in 2020. After completing his surgical training, he did his Endocrine Oncology Fellowship at the University of Sydney Endocrine Surgery Unit at Royal North Shore Hospital from 2008 to 2010. He also was awarded his PhD from the University of Sydney for his work on "Identification of Gene and Gene Regulators in Sporadic Medullary Thyroid Cancer". His areas of interest include thyroid cancers, neuroendocrine tumors, parathyroid disorders, and adrenal tumors with emphasis on translational research. He has published extensively and is sought after to deliver lectures in international and national forums.

Printed in India

Available at all medical bookstores or buy online at www.jaypeebrothers.com

JAYPEE BROTHERS
Medical Publishers (P) Ltd.
EMCA House, 23/23-B, Ansari Road,
Daryaganj, New Delhi - 110 002, INDIA
www.jaypeebrothers.com

Join us on facebook.com/JaypeeMedicalPublishers

Shelving Recommendation
SURGERY

ISBN 978-93-90595-05-1