tion on pediatric books, visit our website www.jaypeebrothers.com, for detailed information on pediatric books, visit our website www.jaypeebrothers.com

Look Inside the Book

INDIAN ACADEMY OF PEDIATRICS

IAP Specialty Series On

PEDIATRIC CARDIOLOGY











R Krishna Kumar
Shakuntala S Prabhu
Shreepal Jain
Sumitra Venkatesh
M Zulfikar Ahamed

THIRD EDITION

Foreword
Nitin K Shah

JAYPEE

Contents

PART 1

PEDIATRIC CARDIOLOGY FOUNDATIONS

SECTION 1 INTRODUCTION TO THE SPECIALTY OF PEDIATRIC CARDIOLOGY

1. **Epidemiology and Burden of Pediatric Heart Disease in India** 3
   Anita Saxena, Sakshi Sachdeva

SECTION 2 FUNDAMENTALS OF PEDIATRIC CARDIOLOGY

2. **Anatomy of the Heart: An Overview** 11
   Sanjeev H Naganur, Balaji Srimurugan, Saurabh Kumar Gupta
3. **Embryology** 18
   Sanjeev H Naganur, Balaji Srimurugan, Saurabh Kumar Gupta
4. **Physiology: Essential Hemodynamics and Basic Electrophysiology** 24
   Raghavan Subramanyan

SECTION 3 DIAGNOSTIC TOOLS

5. **Cardiovascular System: History and Physical Examination** 33
   M Zulfikar Ahamed, R Krishna Kumar
6. **Screening for Congenital Heart Disease** 54
   Navaneetha Sasikumar
7. **The Electrocardiogram, Ambulatory ECG and Exercise Testing** 60
   Mani Ram Krishna
8. **The Chest X-ray** 78
   Munesh Tomar
9. **Echocardiography: What Pediatricians Should Know?** 93
   Praveen Kumar K, Sunita Maheshwari, Sejal Shah
10. **Advanced Cardiac Imaging: Computed Tomography and Magnetic Resonance Imaging** 117
    Mahesh Kappanayil
11. **Diagnostic Cardiac Catheterization and Angiography** 123
    Arun Gopalakrishnan

SECTION 4 THERAPEUTIC TOOLS

12. **Essential Cardiovascular Pharmacology: Common Drugs in Pediatric Cardiac Practice** 135
    Balaganesh Karmegaraj, Alice Neetha, R Krishna Kumar

JAYPEE BROTHERS

13. Pediatric Cardiac Intensive Care 165
Vishal Singh

14. Catheter-based Interventions 190
Shreepal Jain

15. Principles of Pediatric Cardiac Surgery 207
Biswa Panda, Balaji Srimurugan

16. Counseling Families of Children with Heart Disease 226
Sangeetha Viswanathan

PART 2

PEDIATRIC CARDIOVASCULAR DISEASE

SECTION 5 MEDICAL ISSUES

17. Heart Failure in Children 235
Sumitra Venkatesh, R Krishna Kumar

18. Pulmonary Hypertension in Children 252
Shine Kumar KH

19. Syncope 262
Mani Ram Krishna

SECTION 6 CONGENITAL HEART DEFECTS

20. Congenital Heart Disease 267
R Krishna Kumar, Anil Kumar Singhi

21. Atrial Septal Defect 280
Sudeep Verma, Vejendla Gouthami

22. Ventricular Septal Defect 291
Nageswara Rao Koneti

23. Patent Ductus Arteriosus 305
Anand Subramanian, M Jayranganath

24. Aortopulmonary Window and Other Aortic Shunts 313
MK Usha, M Jayranganath

25. Atrioventricular Septal Defect 320
Navaneetha Sasikumar

26. Pulmonary and Systemic Venous Anomalies 328
Arun Gopalakrishnan, Harikrishnan KN

27. Coronary Artery Abnormalities 344
Jayashree Mishra

28. Left Heart Outflow Obstruction 353
Nikhil Thatte

JAYPEE BROTHERS

29. Aortic Arch Obstruction: Coarctation and Aortic Arch Interruption 361
Sangeetha Viswanathan

30. Vascular Rings and Slings 371
Shweta Bakhru

31. Right Ventricular Outflow Obstruction 387
Edwin Francis, Annu Jose

32. Pulmonary Atresia with Intact Ventricular Septum 394
Preeti Ramachandran, Vasu Gooty

33. Ebstein Anomaly of Tricuspid Valve 398
Renu P Kurup

34. Tetralogy of Fallot 410
Sushil Azad

35. Persistent Truncus Arteriosus 418
Saileela Rajan

36. Transposition of Great Arteries 426
R Suresh Kumar, John Valliattu

37. Double Outlet Right Ventricle 438
KS Remadevi

38. Corrected Transposition 446
Nitin Rao, Suman Vyas

39. Univentricular Hearts 457
K Sivakumar

40. Isomerism (Aka Heterotaxy): What Does it Mean and What Does it Do? 468
Rohit S Loomba, Diane E Spicer, Robert Anderson

SECTION 7 ACQUIRED HEART DISEASE

41. Infective Endocarditis 481
Ritchie Sharon Solomon

42. Rheumatic Fever and Rheumatic Heart Disease 494
M Zulfikar Ahamed

43. Myocarditis 518
Navaneetha Sasikumar

44. Kawasaki Disease 528
Saji Philip, M Zulfikar Ahamed, Priyankar Pal, Surjit Singh, R Krishna Kumar

45. Cardiomyopathy 542
Mani Ram Krishna

46. Pericardial Diseases in Children 557
Sakshi Sachdeva, Saurabh Kumar Gupta

JAYPEE BROTHERS

SECTION 8 OTHERS

47. Fetal Cardiology 566
Balu Vaidyanathan, Balaganesh Karmegaraj

48. Neonatal Cardiology 575
Sushil Azad

49. Systemic Hypertension in Children 591
Alpana Ohri, Shakuntala S Prabhu

50. Lifestyle Diseases and Related Conditions: Childhood Obesity, Dyslipidemias, and Cardiovascular Risk Reduction during Childhood and Adolescence 601
Manu Raj

51. Stroke in the Young 618
Shilpa Kulkarni, Bharat Dalvi, Sonam Kothari

52. Rhythm Disorders in Children 623
Mani Ram Krishna

SECTION 9 MISCELLANEOUS

53. Common Problems in Office Practice 645
Snehal Kulkarni, Tanuja Karande, Prashant Bobhate

SECTION 10 CARDIOVASCULAR INVOLVEMENT IN OTHER SYSTEM DISORDERS

54. Genetic Disorders Associated with Congenital Heart Disease 657
Dhanya Yesodharan, Sheela Nampoothiri

55. Cardiac Manifestations in Systemic Conditions 666
Sumitra Venkatesh, Swati Garekar, Shakuntala S Prabhu

Index 685

JAYPEE BROTHERS

39
CHAPTER

Univentricular Hearts

K Sivakumar

INTRODUCTION: WHAT IS A UNIVENTRICULAR HEART?

Univentricular heart refers to a group of cardiac anomalies characterized by a *single functional ventricle* (**Box 1**). Heart chambers are characterized by clear-cut anatomical boundaries between the atrial and ventricular myocardial masses by the anatomical atrioventricular (AV) junction. The ventriculoarterial junction provides similar demarcation between the ventricular mass and fibrous wall of the arterial roots. These anatomical boundaries divide the heart into segments. Each ventricle is tripartite with inlet, apical, and outlet components. When one or the other ventricle is insufficient in size to support either the systemic or pulmonary circulation, there is a functionally univentricular arrangement. Univentricular AV connection refers to connection of both atria to one ventricle either through two AV valve orifices (double-inlet), single AV valve orifice (one valve is atretic), and common orifice (common AV valve). Such hearts with *univentricular AV connections* are called as univentricular hearts.

Such hearts referred as "single ventricle" by Van Praagh or "univentricular AV connection" by Robert Anderson were uniformly associated with very poor survival.[1] These lesions along with tricuspid atresia and mitral atresia share similar hemodynamics. They remained anatomical and imaging curiosities till 50 years earlier, when Fontan surgery was introduced as a palliation for streamlining their circulation. This surgery allows children with a potentially lethal defect to survive to adulthood leading to a new cohort of adult congenital heart disease-palliated population. These patients are significantly different from people with two

BOX 1: Different types of univentricular hearts.

- Univentricular AV connections:
  - Single ventricle:
    - Single ventricle of LV morphology
    - Single ventricle of RV morphology
    - Single ventricle of mixed LV and RV morphology
    - Single ventricle of indeterminate morphology:
      - Double-inlet AV connection
      - Single-inlet (atresia of one valve)
      - Common-inlet (common AV valve)
  - Tricuspid atresia:
    - Associated with normally related great arteries:
      - With pulmonary atresia
      - With pulmonary stenosis
      - Without pulmonary stenosis
    - Associated with d-transposed great arteries:
      - With pulmonary atresia
      - With pulmonary stenosis
      - Without pulmonary stenosis
    - Associated with L-malposed great arteries
- Biventricular AV connections with hypoplastic or ineffective ventricles:
  - Hypoplastic ventricle:
    - Hypoplastic left heart:
      - Mitral atresia
      - Mitral hypoplasia
      - Aortic atresia
      - Aortic hypoplasia
    - Hypoplastic right heart:
      - PA-IVS
      - Small TV/RV
  - Ineffective ventricle:
    - Severe Ebstein anomaly of tricuspid valve
    - Uhl's anomaly of right ventricle
- Biventricular AV connection with well-formed ventricles:
  - Difficult surgical subset:
    - Tetralogy of Fallot with hypoplastic LV
    - TGA with hypoplastic LV
    - DORV with nonroutable VSD:
      - Inlet VSD
      - Remote trabecular VSD
      - Multiple Swiss cheese VSD

Contd...

Contd...

- Superoinferior ventricles:
- Criss-cross AV connections
- Complex anatomy:
  - Right isomerism—heterotaxy
  - Left isomerism—heterotaxy
- High-risk surgery:
  - AV discordance, VSD with PS
  - Straddling AV valve
  - Unbalanced AV canal defect

(AV: atrioventricular; DORV: double-outlet right ventricle; IVS: intact ventricular septum; LV: left ventricle; PA: pulmonary atresia; PS: pulmonary stenosis; RV: right ventricle; TGA: transposition of the great arteries; TV: tricuspid valve, VSD: ventricular septal defect)

JAYPEE BROTHERS

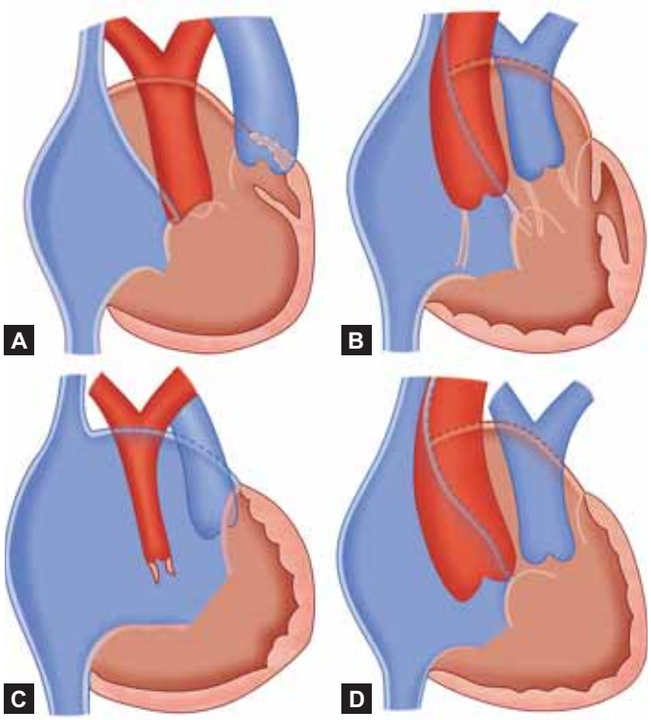

Figs. 1A to D: Univentricular atrioventricular (AV) connection-single ventricle. Single ventricles are grouped according to their morphology into left ventricular morphology (the most common type), right ventricular morphology (next common type), mixed morphology, and indeterminate morphology (both are rare). There can be two separate AV valves or valves.

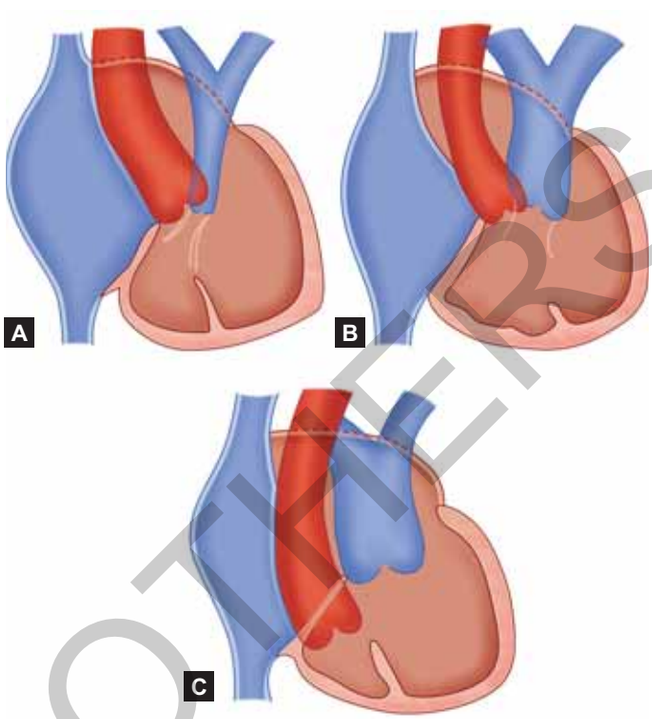

Figs. 2A to C: Univentricular atrioventricular (AV) connection-tricuspid atresia. Tricuspid atresia is grouped as type I with normal related great arteries and type II with transposed great arteries. They are further subgrouped as (A) Pulmonary atresia; (B) Pulmonary stenosis; (C) Unobstructed pulmonary outflow.

ventricles with unique clinical complications and natural history. Single ventricle (**Figs. 1A to D**) and tricuspid atresia (**Figs. 2A to C**) are the two common forms of univentricular hearts.

A second group of heart defects where there is a *biventricular AV connection but one of the ventricles is incapable* of supporting the systemic or pulmonary circulation also were palliated with this Fontan approach. A classic example is hypoplastic left heart syndrome with varying degrees of hypoplasia of inflow and outflow of the left ventricle. A similar situation arises in pulmonary atresia with intact ventricular septum with gross hypoplasia of tricuspid annulus and diminutive right ventricle that can no longer support pulmonary circulation. These hypoplastic right ventricles are often associated with extensive myocardial sinusoids that communicate to the epicardial coronaries, thereby preventing a biventricular surgical correction. Ineffective ventricles in such biventricular AV connections also include severe forms of Ebstein anomaly of tricuspid valve, Uhl's anomaly of the right ventricle with the absence of a contractile right ventricle.

A third group of heart defects with a *biventricular AV connection and reasonably well-formed two ventricles where repair is difficult* also are palliated in this univentricular approach. They include unbalanced AV canal defects where the septation of an asymmetric AV canal might lead to distorted ventricular inflow causing stenosis or regurgitation of the AV valve. Similarly, double-outlet right ventricles with ventricular septal defects (VSDs) that are not located in conotruncal septum are difficult for routing the left ventricle toward one of the great arteries and they are also often palliated in this method. The typical locations of VSD in such double-outlet right ventricles are inlet defects or multiple remote trabecular muscular defects.

The last category of lesions palliated by Fontan pathway includes complex *biventricular AV connections carrying high surgical risks* during a biventricular repair. They include various forms of heterotaxy syndromes that are associated with anomalies of systemic and pulmonary veins, AV connections, varying hypoplasia of one of the ventricles, and anomalies of the outflow tracts.

The other lesions in this category include patients with:

1. Atrioventricular septal defects in association with tetralogy of Fallot that carries risk of right ventricular failure and AV valve regurgitation after extensive surgery.
2. Atrioventricular discordance with VSD and pulmonary stenosis that needs combination of Senning and Rastelli surgery with risks of injury to conduction tissues.
3. Tetralogy of Fallot or transposition of great arteries with hypoplastic ventricles.

JAYPEE BROTHERS

4. Large inlet VSD with marked straddling of the AV valves, and other similar complex morphologies.

Even though these lesions individually are amenable for a biventricular connection, such complex repairs of a deformed heart with multiple anomalies carry more mortality in institutions that have low volume of surgeries of similar nature.

PATHOPHYSIOLOGY OF UNIVENTRICULAR HEARTS

Postnatal circulation in normal hearts consists of blood flow in series that passes from the left ventricle through the systemic circulation to return to the right ventricle and finally to pulmonary circulation. The key pathophysiological features in univentricular hearts are highlighted in italics (**Box 2**). All forms of univentricular hearts have some degree of *parallel circulation* and *admixture*, where there is recirculation of venous blood in systemic circulation and oxygenated blood in the pulmonary circulation. This leads to inefficiency of heart and *volume overload* of the ventricles. Unlike low pressures in normal right ventricle in a structurally normal heart, most univentricular forms of hearts described above cause *pressure overload* of ventricles leading to *ventricular hypertrophy* and resultant *diastolic dysfunction* and restricted filling.

Excessive pulmonary blood flow in patients without pulmonary stenosis leads to *heart failure* but negligible hypoxia. If there is significant pulmonary stenosis or atresia, *cyanosis* is profound. Some neonates with pulmonary atresia present with *duct dependency*. If systemic outflow is obstructed, neonates present in *circulatory shock*, dependent on ductal patency to maintain circulation. Noncritical systemic outflow obstruction results in *suprasystemic ventricular pressures*, undue ventricular hypertrophy, and predisposes to *ventricular failure*.

Right AV valve atresia, stenosis, or regurgitation may lead to *systemic venous hypertension*, unless a large atrial septal communication decompresses the atrium. A similar left-sided pathology leads to *pulmonary venous hypertension*. Fetal pulmonary venous hypertension may lead to *lymphangiectasia of lungs* and lead to severe *pulmonary arterial hypertension*. Anomalous pulmonary venous drainage seen in heterotaxy syndromes may also lead to similar effects.

Admixture of blood in majority of these lesions may give a *favorable or unfavorable streaming* of blood in the outflow tracts. When aortic oxygen saturation is higher than that of pulmonary artery, it is called favorable streaming leading to minimal cyanosis. On the contrary, a higher oxygenation in pulmonary artery is called unfavorable streaming and leads to intense cyanosis due to transposition like physiology.

Fetal blood flow patterns in some univentricular hearts predispose to distal obstructions. Tricuspid atresia and transposed great arteries with restrictive VSD lead to subaortic stenosis, which predisposes to *aortic arch obstruction and coarctation*. A similar situation is seen in single ventricle of left ventricular morphology and restrictive bulboventricular foramen or unbalanced AV canal with subaortic stenosis. Another influence of fetal blood flow is seen in hearts with left AV valve stenosis or atresia, which is caused by restricted flows through the foramen ovale. These patients uniformly display thickened muscular atrial septum with very *restrictive or absent interatrial communications*.

BOX 2: Pathophysiological effects in univentricular hearts.

- *Effects on pulmonary circulation*:
  - Minimal or no obstruction to outflow:
    - Overcirculation
    - Pulmonary hypertension
    - Heart failure
  - Severe obstruction and atresia:
    - Severe cyanosis
    - Duct dependency
- *Effects on systemic circulation*:
  - Obstructed aortic outflow:
    - Neonatal shock
    - Duct dependency
    - Suprasystemic ventricular pressures
  - Obstructed arch:
    - Reduced lower body perfusion
    - Systemic hypertension
    - Ventricular hypertrophy
- *Volume overload is caused by*:
  - Parallel circulation and admixture
  - Pulmonary overcirculation
  - AV valve regurgitation
- *Pressure overload* is caused by:
  - Outflow obstruction
  - Aortic arch obstruction
- *Systemic venous hypertension* is caused by:
  - AVV atresia, stenosis, leak
  - Systolic heart failure
  - Diastolic failure
  - Restrictive PFO
- *Pulmonary venous hypertension* is due to:
  - AVV atresia, stenosis, leak
  - Systolic heart failure
  - Diastolic failure
  - Restrictive PFO
  - Anomalous PV drainage
- *Admixture*:
  - Favorable streaming (Ao saturation > PA saturation)
  - Unfavorable streaming (PA saturation > Ao saturation)

(Ao: aorta; AV: atrioventricular; AVV: atrioventricular valve; PA: pulmonary atresia; PFO: patent foramen ovale; PV: pulmonary venous)

CLINICAL FEATURES OF UNIVENTRICULAR HEARTS

Table 1 summarizes the clinical features. Neonatal presentation is seen in very critical forms of univentricular hearts.[2] Severe obstruction or atresia of pulmonary outflow leads to severe cyanosis and duct dependency, manifesting in the first week of life that is refractory to oxygen supplementation and fails hyperoxia–hyperventilation test. They need prostaglandin

JAYPEE BROTHERS

TABLE 1: Clinical features of univentricular hearts.

Age	*Pathophysiology*	*Clinical syndrome*	*Symptoms*	*Clinical signs*	*Basic tests*
Newborn	Obstructed pulmonary flows	Duct-dependent hypoxia	Severe cyanosis in 1–7 days	No murmurs, single S2	Oligemic lungs in chest X-ray
	Obstructed systemic blood flows	Shock state; duct-dependent systemic flow	Pale, cold, "sepsis-like" features	Absent pulses, cold extremities	Acidosis on blood gases
	Excessive pulmonary flows	Congestive heart failure	Tachypnea, poor feeds, diaphoresis	Hyperkinetic precordium S3, apical diastolic murmur	Cardiomegaly plethora on chest X-ray
	Aortic arch obstruction	Duct-dependent systemic flow Oliguria, acidosis	Respiratory distress	Weak femoral pulse	Limb blood pressure
Infant and toddler	Excessive pulmonary flows	Congestive heart failure	Tachypnea, poor feeds, diaphoresis	Hyperkinetic precordium S3, apical diastolic murmur	Cardiomegaly plethora on chest X-ray
	Obstructed pulmonary flows	Hypoxic spells	Severe cyanosis	Faint outflow murmur	Oligemic lungs in chest X-ray
	Venous hypertension	Heart failure	Cyanosis, poor feeds	Large liver, distress	Ground-glass lungs in chest X-ray
Older child/adult	Optimal balance in circulation	Compensated heart failure	Fatigue, occult heart failure	Cyanosis, systolic or continuous murmurs	Cardiomegaly

E1 followed by aortopulmonary shunt or ductal stenting. Critical systemic outflow obstruction may lead to shock state with absent pulses, lactic acidosis, hypothermia, and hypoglycemia. Duct-dependent systemic circulation may improve with prostaglandin, inotropes, and permissive hypercapnia. Vigorous hyperventilation with high oxygen causes pulmonary vasodilatation and worsens heart failure and shock in hypoplastic left heart syndrome.

In the absence of pulmonary stenosis, postnatal fall in pulmonary vascular resistance leads to pulmonary overcirculation and heart failure in 2–6 weeks. They have hyperkinetic precordium, systolic outflow murmurs, flow diastolic apical murmurs, and third heart sounds. Presence of AV valve regurgitation or stenosis may worsen features of heart failure. Aortic arch obstruction may be missed if femoral pulses are not compared to arm pulses. A majority of these patients have malposed aorta leading to single aortic component of second sound and palpable aortic pulsations in left upper sternal border.

In the presence of pulmonary stenosis, cyanosis is progressive as duct closes and somatic growth of the child warrants higher oxygenation. Hypercyanotic spells may rarely occur, though not typical as in Fallot's tetralogy. Prominent jugular venous pulsations, cardiomegaly, left upper sternal border pulsations, abnormal right-sided precordial pulsations, and situs anomalies may be present in these patients and differentiate from tetralogy of Fallot.

The natural history is unfavorable in univentricular hearts and survival beyond infancy is limited to an extreme minority (<10%) of these patients. Clinical examination may show features of abnormal situs in heterotaxy, prominent atrial systolic pulsations on jugular veins, cardiomegaly, abnormal left parasternal pulsations, single second sound, outflow murmurs, and flow diastolic murmurs. Pulmonary vascular disease in advanced pulmonary hypertension may lead to severe cyanosis and disappearance of murmurs.

Rare anecdotal adult survivors owe their extended lifespan to a balanced circulation enabled by moderate levels of pulmonary stenosis without causing life-threatening hypoxia. The factors that help in this unusual adult survival include presence of aortopulmonary collaterals, persistent patency of arterial duct, compensatory ventricular hypertrophy, optimal levels of pulmonary stenosis, and combinations of anomalies that mutually nullify the effects of each other. An example of such a combination occurs in a complex heart in heterotaxy syndrome with transposition physiology where aortic saturation is lower than pulmonary circulation that is helped by an associated total anomalous pulmonary venous drainage that acts as a natural atrial switch to save the patient from hypoxia.

INVESTIGATING PATIENTS WITH UNIVENTRICULAR HEARTS

The key role of investigation in patients with univentricular hearts is to:

- Establish diagnosis—the morphological type according to the classification is done by echocardiography

JAYPEE BROTHERS

- Identify adequacy of pulmonary blood flows—that can be either antegrade through the pulmonary valve or through other sources such as arterial duct or aortopulmonary collaterals
- Identify adequacy of systemic blood flows—includes flows across the aortic valve and across the aortic isthmus
- Rule out systemic venous congestion—congested inferior caval veins and hepatic veins that show flow reversals
- Rule out pulmonary venous hypertension—poor interatrial septal communications and identification of anomalous pulmonary venous drainage
- Assess ventricular volume overload, ventricular systolic function by objective criteria such as ejection fraction or speckle strain, which is used for longitudinal follow-up of patients with advancing age
- Assess pressure overload, ventricular hypertrophy, and diastolic dysfunction
- Assess AV valve anatomy, function, mechanism of regurgitation to plan surgical repairs
- Identify factors that favor survival such as aortopulmonary collaterals and arterial duct
- Diagnose extracardiac anomalies in heterotaxy and other syndromes.

Most information is obtained from a detailed echocardiography (**Figs. 3 to 5**). Additional information can be obtained from electrocardiogram (situs identification, sick sinus, AV nodal disturbances, pre-excitations, specific pattern identification), peripheral smear of blood (asplenia syndrome), ultrasound abdomen and cranium to identify anomalies and adverse effects, computed tomography for aortopulmonary collaterals and anomalous pulmonary veins, magnetic resonance imaging for ventricular function and volumes, nuclear imaging for spleen, and genetic testing (*see* Chapter 40).

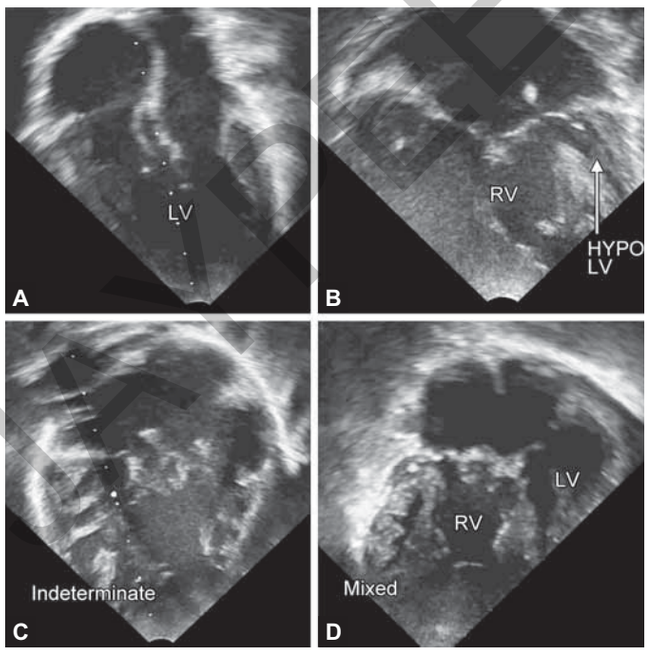

Figs. 3A to D: Echocardiographic view—single ventricle. (A) Left ventricular (LV) morphology; (B) Right ventricular (RV) morphology; (C) Indeterminate morphology; (D) Mixed morphology.

PRINCIPLES OF MANAGEMENT IN UNIVENTRICULAR HEARTS

Initial Management in Newborns and Young Infants

The management of patients depends on their pathophysiology mentioned earlier and is explained in **Figure 6**. The surgical management is carried out in three stages; the first stage is carried out in neonatal period or early infancy.

Pulmonary oligemia due to severe pulmonary stenosis or atresia is managed in neonatal period with prostaglandin E1 to maintain ductal patency followed by stenting of ductus arteriosus or aortopulmonary shunt (**Figs. 7A to C**). The former is increasingly utilized to avoid neonatal surgery and its associated morbidity. Despite improvement of hypoxia, there is volume loading of the univentricular heart after shunts. Contrary to the postshunt management in Fallot's tetralogy where final correction is postponed to 6–12 months of age, children with univentricular heart are planned for second-stage palliation earlier within 3–6 months. Interval morbidity between first and second stage caused by stent or shunt occlusion is avoided by low-dose aspirin therapy. Iron therapy to prevent relative anemia is imperative in these patients.

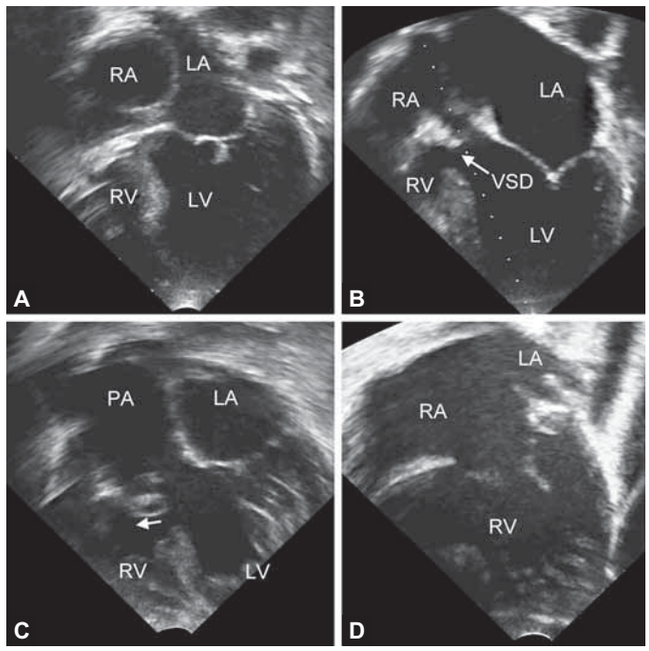

Figs. 4A to D: Echocardiographic view—tricuspid and mitral atresia. (A) Tricuspid atresia Kuhne Ia; (B) Tricuspid atresia Kuhne Ib; (C) Tricuspid atresia Kuhne IIc; (D) Mitral atresia.
(LA: left atrium; LV: left ventricle; PA: pulmonary artery; RA: right atrium; RV; right ventricle; VSD: ventricular septal defect)

JAYPEE BROTHERS

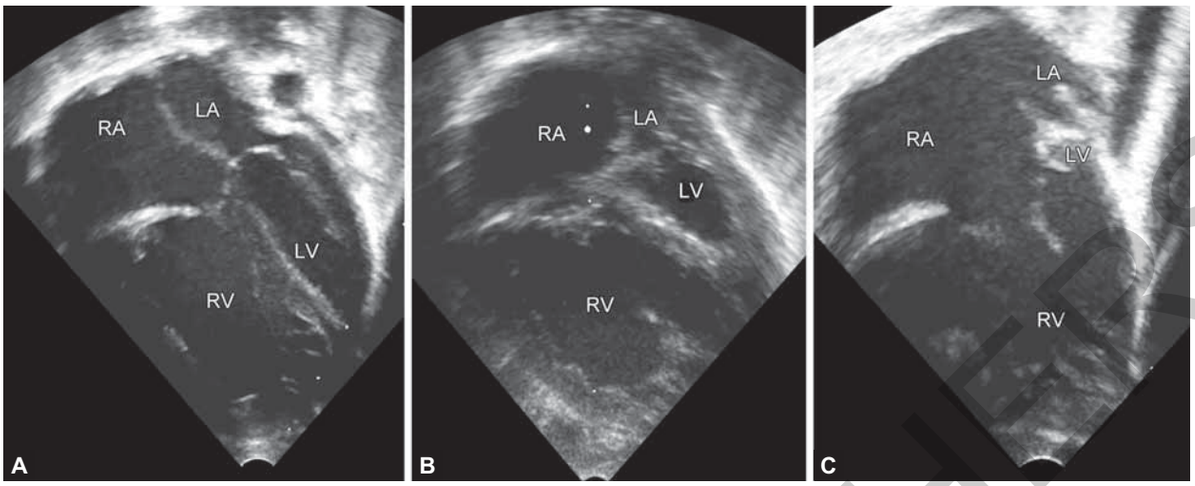

Figs. 5A to C: Echocardiographic view—hypoplastic left heart syndrome. (A) Mild hypoplasia; (B) Severe hypoplasia; (C) Very diminutive left ventricle (LV) with mitral atresia.

(LA: left atrium; LV: left ventricle; RA: right atrium; RV: right ventricle)

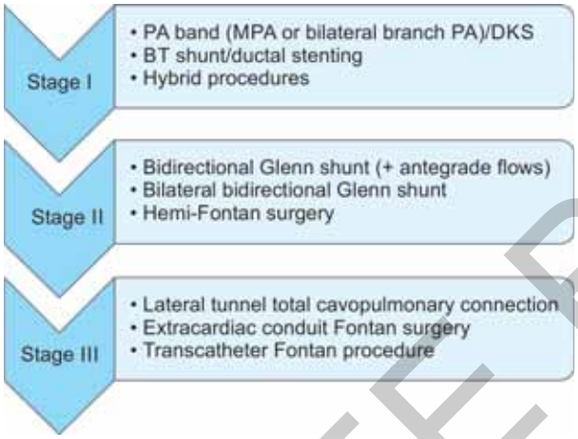

Fig. 6: Management plan in univentricular hearts. The surgical plan comprises an early neonatal first stage, followed by diversion of superior vena caval flows toward the pulmonary circulation in stage II that is performed at 3–12 months and then a final stage at 3–10 years where the inferior vena caval blood is also routed toward the pulmonary circulation.

(BT: Blalock–Taussig; DKS: Damus–Kaye–Stansel; MPA: main pulmonary artery; PA: pulmonary artery)

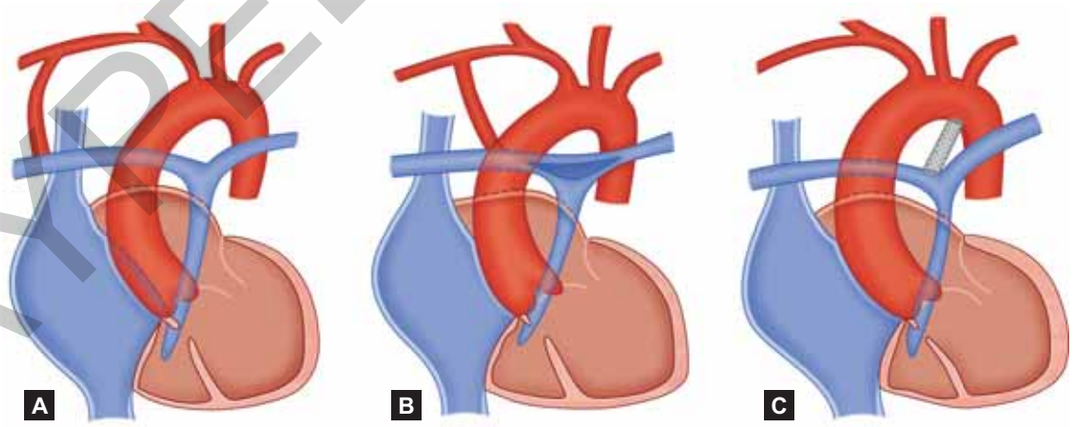

Figs. 7A to C: First stage palliation in oligemic lungs (A); Modified Blalock–Taussig shunt from subclavian artery to ipsilateral pulmonary artery through thoracotomy is largely replaced in recent times by central sternotomy (B); Another method of palliation is transcatheter stenting of the ductus arteriosus (C).

Banding the pulmonary arteries controls excessive pulmonary overflow (**Figs. 8A to C**). Ductal stents and aortopulmonary shunts improve pulmonary oligemia. Pulmonary venous hypertension is relieved by balloon atrial septostomy or surgical atrial septectomy. Heart failure is managed with diuretics. Ventricular systolic dysfunction

JAYPEE BROTHERS

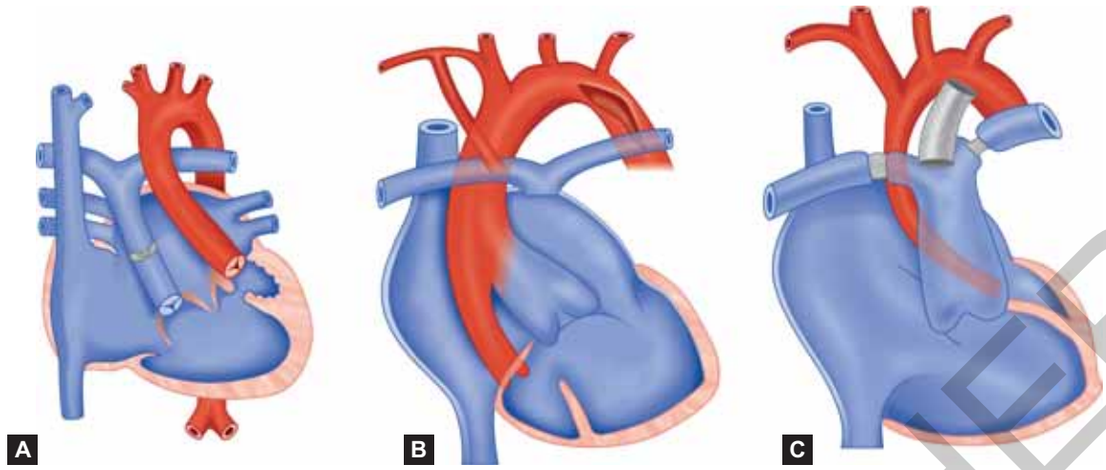

Figs. 8A to C: First-stage palliation in plethoric lungs. (A) Pulmonary artery banding is commonly performed within the first 6–8 weeks to prevent volume overload of the ventricles; (B) Patients at risk of subaortic stenosis or aortic arch obstruction are managed by Damus–Kaye–Stansel procedure where the main pulmonary artery is anastamosed to ascending aorta and pulmonary circulation is maintained through a modified Blalock–Taussig (BT) shunt; (C) A hybrid way of achieving a stage I palliation utilizes ductal stenting, balloon atrial septostomy, and bilateral pulmonary artery banding.

with or without AV valve regurgitation may need after load-reducing agents. Optimizing ventilation by allowing permissive hypercapnia is followed in hypoplastic left heart syndrome to avoid excessive pulmonary vasodilation. Associated hypothermia, sepsis, metabolic acidosis, and hypoglycemia will need routine neonatal intensive care. Antibiotic prophylaxis and special vaccines are warranted in asplenia. Inotropes are used in shock state.

Banding the main pulmonary artery controls pulmonary overcirculation. In patients with associated aortic arch obstruction and pulmonary venous hypertension due to restrictive foramen ovale, neonatal surgery addresses these additional problems too. Certain cardiac morphologies with substrate for subaortic narrowing (tricuspid atresia with transposition and restrictive VSD, unbalanced AV canal defect with subaortic narrowing, and single ventricle with restrictive bulboventricular foramen) may need more extensive surgery. Damus–Kaye–Stansel (DKS) procedure is performed in these patients, where main pulmonary artery is connected end-to-side to ascending aorta and the disconnected distal pulmonary artery is provided blood flow through an aortopulmonary shunt. Some patients with hypoplastic left heart may be palliated in first-stage by hybrid Norwood stage I procedure which comprises of bilateral branch pulmonary artery banding along with ductal stenting and balloon atrial septostomy. Unilateral banding may be needed if there is anomalous aortic origin of a disconnected pulmonary artery.

Stage II Palliation

The second stage comprises of interruption of aortopulmonary shunts, arterial duct, and aortopulmonary collaterals and performing a bidirectional cavopulmonary shunt—end-to-side from superior vena cava to pulmonary artery (**Figs. 9A and B**). This bidirectional Glenn shunt surgery will be performed bilaterally in patients with bilateral superior vena cava and combined with repair of the narrowed confluence at ductal insertion site in patients with stenosis in this area. Unidirectional shunt connecting superior vena cava end-to-end to pulmonary artery is currently not performed. Pulmonary artery is interrupted during this surgery in all patients including those palliated with pulmonary artery banding to reduce pulmonary artery pressures and permit the passive flow. Preservation of antegrade blood flow from the ventricle into the pulmonary artery provides pulsatile blood flow that increases pulmonary artery growth, increases pulmonary arterial capacitance, recruits pulmonary arterioles and reduces pulmonary vascular resistance, delays hypoxia, provides "hepatic factor X" to delay development of arteriovenous malformations and rarely act as a final destination therapy in a few patients. The disadvantages include persistent ventricular volume overload, increased pulmonary artery pressures, lead to superior vena caval and

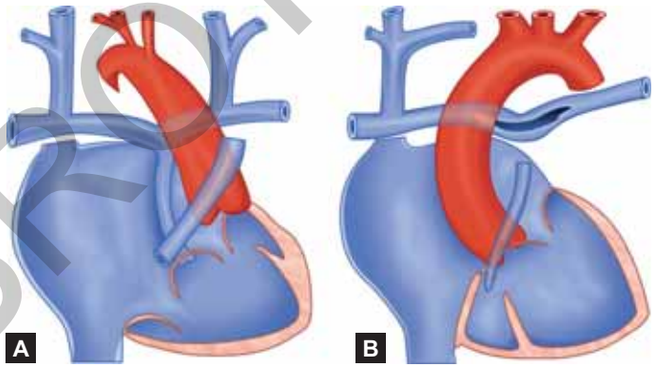

Figs. 9A and B: Second-stage palliation. Connecting the superior vena cava to pulmonary circulation forms the second-stage palliation. Antegrade pulmonary blood flow is either retained or interrupted in this stage (A). The anastomosis is completed bilaterally in patients with dual superior vena cava (B).

JAYPEE BROTHERS

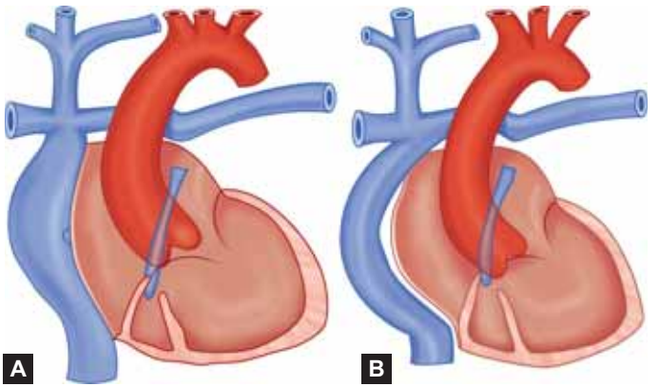

Figs. 10A and B: Final-stage palliation. Connecting the inferior vena cava to the pulmonary circulation is the final-stage palliation for univentricular hearts. The two common and recent forms of achieving this are lateral tunnel Fontan surgery (A) also called as total cavopulmonary connection and extracardiac conduit Fontan surgery (B).

cerebral congestion, increase pleural effusions, and render some patients unsuitable for third stage.

Stage III Palliation

The third stage, Fontan procedure is the final stage in the stepwise palliation of a functionally univentricular heart (**Figs. 10A and B**). Fontan and Baudet introduced this surgery in 1971 as a solution for tricuspid atresia by diverting systemic venous flows passively without an intervening ventricular pump directly into the pulmonary artery. The fundamental requisite for this passive flow is the low resistance pulmonary vascular bed that allows the pressure gradient between the two vascular bed (higher pressures in systemic vasculature and lower pressures in pulmonary vasculature) to allow flow through the lungs without an intervening ventricular pump. Apart from this pressure gradient that maintains this passive flow, the additional contributors are chest wall (diaphragmatic and thoracic cage) excursions, and peripheral skeletal muscles in the body that aid in systemic venous return toward the thorax. The resultant circulation places pulmonary and systemic vasculature in series with functional single ventricle as the only pump. This palliation is largely criticized as it only aims at oxygenating the systemic venous blood without providing a pulmonary circulatory pump.

ALTERED CIRCULATION AFTER FONTAN SURGERY

The new circulation after Fontan surgery is inherently characterized by decreased preload and increased afterload to the single ventricle, which prevents significant increase of cardiac output leaving these patients with little hemodynamic reserve. They become more dependent of their heart rate and AV nodal conduction for augmenting the cardiac output unlike normal biventricular hearts that utilize additional stroke volume and contractility reserves. The patients with Fontan circulation are additionally more dependent on respiration and skeletal muscles to augment venous return and cardiac output. Older types of Fontan surgery involved atriopulmonary anastomosis resulting in atrial enlargement, arrhythmias, thrombus formation, and poor mechanics. Recent modifications include lateral tunnel Fontan surgery and extracardiac conduit Fontan surgery with or without a fenestration to act as a pop-off for the systemic veins into the atrium. Survival is better with recent modifications of Fontan and systemic left ventricle.

HOW TO CARE FOR PATIENTS AFTER GLENN AND FONTAN SURGERIES

Univentricular hearts in developed economies are managed by stage I palliation in their early neonatal period to prevent significant hypoxia-related brain injury in oligemic patients and development of pulmonary arterial hypertension in patients with excessive pulmonary blood flow. The volume overload of ventricles is prevented in these patients by performance of stage II palliation within 3–6 months, when the pulmonary arteries and pulmonary vascular bed is relatively small due to the small weight of the patients at that age. The final palliation is completed between 2 and 4 years again to minimize the effects of continuing hypoxia that is not eliminated by the Glenn shunt.

The entire timeframe is shifted to later age in low-middle income countries. While stage I is performed in late neonatal or early infancy, Glenn shunt is done at 6–12 months and Fontan completion is performed at 4–10 years of age. The reasons behind this deferred treatment are to allow the caregivers to sort out the other associated neonatal morbidities such as sepsis, syndromic evaluations, detailed family counselling, and to overcome the challenges posed by a low bodyweight neonate in the pediatric cardiac intensive care unit. Additionally, economic constraints also contribute. A similar late age at second and third stages allows surgery on relatively larger sized pulmonary arteries and well-developed pulmonary vascular bed.

The fundamental differences between the early interventions followed in developed countries (focusing on preservation of ventricular function at the cost of challenging the small pulmonary vasculature to a passive venous flow) and later interventions in low-middle-income countries (focusing on surgery on a well-developed pulmonary vascular bed and allowing a permissive strategy on ventricular overload and hypertrophy) have found equal merits and demerits in their approaches. A passive cavopulmonary flow after second stage needs both a good functioning ventricle to pump the blood through both circulations and a good well-developed pulmonary vascular bed.

Role of pediatrician after first-stage correction comprises of aspirin to maintain patency of the shunt, guarded use of diuretics and afterload reducing agents after banding,

JAYPEE BROTHERS

vaccines and antibiotics for intercurrent infections, close monitoring of saturations, and growth to prevent inter-stage mortality and patient counselling. Following second stage, aspirin prevents thrombosis in passive venous flows, iron prevents relative anemia, respiratory physiotherapy and breathing exercises maintain healthy ventilatory mechanics, guarded use of diuretics and pulmonary or systemic vasodilators in appropriate situations. As there is a high incidence of thrombus formation in the first year after the third-stage Fontan surgery, it is common practice to give oral anticoagulation with warfarin monitored by prothrombin time evaluations and appropriate dietary restrictions of vitamin K-rich foods. Promotion of respiratory and skeletal muscle strength by regular monitored exercises, breathing exercises, yoga, avoidance of air pollution, healthy lifestyle avoiding active, and passive smoking will play a role in longevity of patients after third stage.

Drug therapy after Fontan surgery may include diuretics in patients with high venous pressures and effusions, pulmonary vasodilators such as sildenafil or bosentan in patients with evidence of high pulmonary vascular resistance, angiotensin-converting enzyme inhibitors in patients with significant AV valve regurgitations or ventricular systolic dysfunction, antiarrhythmic agents such as amiodarone for automatic or reentrant arrhythmias, beta-blockers to control ventricular rate in supraventricular arrhythmias and antibiotic prophylaxis in asplenia syndrome.

PROBLEMS ON LONG-TERM FOLLOW-UP AFTER THE FONTAN OPERATION

Post-Fontan patients may present with heart failure under four clinical groups: (1) systolic dysfunction, (2) diastolic dysfunction, (3) normal pressures, and (4) abnormal lymphatics. Arrhythmias occur in 13–16% of patients and increase with time after surgery. They can result from sick sinus syndrome, suture lines, atrial fibrillation, and progressive atrial dilatation. Some of these arrhythmias may need electrophysiological studies but results may be suboptimal and procedure may be challenging due to lack of access from venous lines. Despite 80% acute success after radiofrequency ablations, recurrences occur in 30–45% after 1 year (**Table 2**).

Liver fibrosis results from chronicity of venous congestion (less related to severity of venous congestion).[3] Hepatocellular carcinoma occurs in 1.3% of Fontan survivors. Protein-losing enteropathy is due to hypoperfusion leading to inflammation and venous congestion. The loss of mucosal integrity of gastrointestinal epithelium leaking immunoglobulins and clotting factors in the lumen. It is common in children, usually 3–8 years after surgery and occurs in 10% of Fontan patients. The treatment includes albumin infusions, enteral budesonide, heparin, diuretics, spironolactone, sildenafil, digoxin, rapid atrial pacing, and lymphatic interventions.[4,5]

Lymphatic insufficiency is caused by increased production and reduced drainage. In early days after surgery, it manifests as chylothorax and chylous ascites. After 1–2 years, they manifest with plastic bronchitis, where endobronchial leak of proteinaceous material leads to formation of viscid bronchial casts that lead to asphyxia. Thromboembolic events occur in one-third of Fontan patients. They occur due to nonpulsatile flow, venous congestion, low cardiac output, dilated atrium, arrhythmia, and protein-losing enteropathy. Asymptomatic pulmonary emboli, pulmonary infarctions, and slow elevation of pulmonary vascular resistance occur in patients with thromboembolism on pulmonary vasculature.[6,7] In patients with fenestrations and atrial arrhythmias, thromboembolism affects systemic vasculature too.

Renal dysfunction arises due to poor perfusion and venous congestion. In contrast to renal failure in usual clinical practice that is identified by elevation of creatinine levels, alternative markers such as cystatin C levels can better identify Fontan patients, who have low creatinine production. Cyanosis after Fontan surgery may result from fenestration, baffle leaks, pulmonary vein compression, venous collaterals, and pulmonary arteriovenous malformations. Pulmonary function tests show impaired exercise capacity, low vital capacity, high residual volume, skeletal muscle dysfunction, and poor performance on cardiopulmonary exercise testing. These abnormalities affect passive cavopulmonary flows and worsen Fontan failure. General health perception and psychological health are also affected due to the various somatic abnormalities.

Conception is not a common occurrence due to poor maternal health as fertility and ovulation are impaired. Early abortions and teratogenicity of various medications also contribute to fetal losses. Multidisciplinary team approach is needed in managing a pregnancy in these patients. Arrhythmias, thromboembolism, and heart failure are more common during pregnancy. Noncardiac perioperative care also needs vigilance. Anesthetics, hypoxia, atelectasis, thromboembolism, pneumonia, volume loss, and excess fluids may destabilize the precarious hemodynamics in a patient after Fontan surgery.

CURRENT STATUS OF FONTAN SURVIVAL

Perioperative mortality after Fontan surgery in carefully selected patients has reduced to 1% in current era. 10-year survival after Fontan surgery has improved to 97% with the current methods using lateral tunnels or extracardiac conduits. In best centers, current survival at 25 years is 76%, but these patients have older atriopulmonary Fontan circulations. Survival of patients operated in the last two decades is far better compared to older reports.

A number of factors have been shown to be associated with reduced survival after Fontan surgery. They include male gender, specific diagnostic categories such as hypoplastic

JAYPEE BROTHERS

TABLE 2: Problems after Fontan surgery.

No.	*Hemodynamic problem*	*Investigation*	*Management*	*Prognosis*
1.	Heart failure from systolic or diastolic dysfunction	Echocardiogram Magnetic resonance	Diuretics ACEI AT blocker	May worsen despite therapy
2.	Arrhythmias – atrial reentrant or automatic	ECG Holter electrophysiological study	Antiarrhythmics RF cryoablation	Success in 80% but recurs
3.	Pleural effusions, chylothorax, and ascites	Fluid analysis, ultrasound, CXR	Diuretics, octreotide, TPN	subsides on therapy
4.	Liver fibrosis, cirrhosis, adenoma, and carcinoma	Elastography ultrasound, MRI	Diuretics, avoid hepatotoxic drugs	Slow progress in liver disease
5.	Protein losing enteropathy with hypocalcemia	Fecal alpha-1 antitrypsin, and albumin	Budesonide Heparin	Guarded prognosis
6.	Plastic bronchitis with asphyxia	Bronchoscopy, sputum examination	tPA inhalation, physiotherapy, lymphatic interventions	Often fatal outcome
7.	Lymphatic occlusions	Magnetic resonance lymphangiography	Lymphatic interventions	Guarded prognosis
8.	Pulmonary thromboembolism	CT lungs, CXR, pulmonary angiography	Heparin, oral anticoagulation	Early treatment is beneficial
9.	Systemic thromboembolism	Vascular Doppler, CT angiography	Heparin, oral anticoagulation	Early treatment is beneficial
10.	Renal dysfunction	Cystatin C, urea, creatinine	Optimize hemodynamics	Avoid nephrotoxic drugs
11.	Cyanosis due to baffle leaks and fenestrations	Contrast echocardiogram	Fenestration closure	Appropriate treatment feasible
12.	Pulmonary function abnormalities	Spirometry cardio-pulmonary exercise test	Physiotherapy, breathing exercise	Active treatment helps
13.	General health abnormalities	Quality of life index	Multidisciplinary team work	Support groups will help
14.	Psychological health due to repeated clinic visits	Psychometric assessment	Active counseling	Support groups will help
15.	Fertility and pregnancy related issues	Ultrasound and hormonal assays	Multidisciplinary approach	Counseling and adoption service
16.	Noncardiac surgical morbidity	Anesthetic risk assessment	Prevent hypoxia, lung complication	Usually manageable

(ACEI: angiotensin-converting-enzyme inhibitors; AT: angiotensin; CT: computed tomography; CXR: chest X-ray; ECG: electrocardiography; MRI: magnetic resonance imaging; RF: radiofrequency; tPA: tissue plasminogen activator; TPN: total parenteral nutrition)

left heart syndrome, older type of Fontan procedure, earlier surgical era, older age at procedure, and concomitant valve replacement. Prolonged pleural effusions, elevated venous pressures, lower oxygen saturation, low ventricular systolic function by echocardiography, larger end-diastolic volumes on magnetic resonance also correlate with poor survival. Additionally, low peak heart rate and oxygen uptake on exercise cardiopulmonary testing, low serum sodium, high pro-brain natriuretic peptide level, arrhythmias, presence of complications such as protein-losing enteropathy or plastic bronchitis, and multisystem problems also correlate with poor survival.

Catheter interventions that may be needed in patients following Fontan surgery include stent angioplasty of stenosed or occluded conduits, dilatation and stenting of anastomosis, recanalization and stent angioplasty of branch pulmonary arteries, aortic coarctation dilatation and stenting, lymphatic interventions, closure or creation of fenestrations, device closure of persistent antegrade flows from ventricles, closure of venovenous and aortopulmonary collaterals, electrophysiological studies, and radiofrequency ablation of arrhythmias.[8,9]

Fontan surgery offers hope to a large number of patients with a single functional ventricle and provides a long-term palliation extending to third or fourth decades. Despite the myriad of problems involving multiple organs, many patients maintain adequate quality of life, thanks to the multiple medical and interventional therapies performed in these survivors.

CONCLUSION

This chapter has looked to provide an overview on a diverse set of conditions that are unified by the fact that they can be managed through a staged palliative strategy that typically culminates in the Fontan operation. Essential concepts required in understanding their physiology and management have been presented here. With improvements in access to comprehensive pediatric heart care, it can be expected that

JAYPEE BROTHERS

an increasing number of patients will be offered palliative operations for univentricular hearts and there is a need for caregivers to be familiar with the concepts presented here.

REFERENCES

1. Khairy P, Fernandes SM, Mayer JE Jr, Triedman JK, Walsh EP, Lock JE, et al. Long-term survival, modes of death, and predictors of mortality in patients with Fontan surgery. Circulation. 2008;117(1):85-92.
2. Gatzoulis MA, Munk MD, Williams WG, Webb GD. Definitive palliation with cavopulmonary or aortopulmonary shunts for adults with single ventricle physiology. Heart. 2000;83(1):51-7.
3. Kiesewetter CH, Sheron N, Vettukattill JJ, Hacking N, Stedman B, Sadler HM, et al. Hepatic changes in the failing Fontan circulation. Heart. 2007;93(5):579-84.
4. Hebson CL, McCabe NM, Elder RW, Mahle WT, McConnell M, Kogon BE, et al. Hemodynamic phenotype of the failing Fontan in an adult population. Am J Cardiol. 2013;112(12):1943-7.
5. Hebert A, Mikkelsen UR, Thilen U, Idorn L, Jensen AS, Nagy E, et al. Bosentan improves exercise capacity in adolescents and adults after Fontan operation: the TEMPO (Treatment With Endothelin Receptor Antagonist in Fontan Patients, a Randomized, Placebo-Controlled, Double-Blind Study Measuring Peak Oxygen Consumption) study. Circulation. 2014;130(23):2021-30.
6. Giardini A, Balducci A, Specchia S, Gargiulo G, Bonvicini M, Picchio FM. Effect of sildenafil on haemodynamic response to exercise and exercise capacity in Fontan patients. Eur Heart J. 2008;29(13):1681-7.
7. Potter BJ, Leong-Sit P, Fernandes SM, Feifer A, Mayer Jr JE, Triedman JK, et al. Effect of aspirin and warfarin therapy on thromboembolic events in patients with univentricular hearts and Fontan palliation. Int J Cardiol. 2013; 168(4):3940-3.
8. John AS, Johnson JA, Khan M, Driscoll DJ, Warnes CA, Cetta F. Clinical outcomes and improved survival in patients with protein-losing enteropathy after the Fontan operation. J Am Coll Cardiol. 2014;64(1):54-62.
9. Sivakumar K. Physiology of Fontan operation; complication and management. In: Cardiology Update 2019 Textbook. Kanti M (Ed). New Delhi: Das Evangel Publication; 2019. pp 753-66.

JAYPEE BROTHERS

for detailed information on pediatric books, visit our website www.jaypeebrothers.com, for detailed information on pediatric books, visit our website www.ja

IAP Specialty Series On

PEDIATRIC CARDIOLOGY

Salient Features

- Completely redesigned and rewritten: This third edition is entirely redone from scratch
- Conveniently organized and accessible content that is easy to comprehend
- Contextual: Written especially for postgraduates in Pediatrics seeking to understand pediatric cardiology
- Comprehensive: Covers all facets of pediatric cardiac care that include cardiac surgery, intensive care and catheter interventions
- Contemporary: Several new chapters such as screening, parental counseling, and office practice.

Printed in India

Available at all medical bookstores
or buy online at www.jaypeebrothers.com

JAYPEE BROTHERS
Medical Publishers (P) Ltd.
EMCA House, 23/23-B, Ansari Road,
Daryaganj, New Delhi - 110 002, INDIA
www.jaypeebrothers.com

Join us on facebook.com/JaypeeMedicalPublishers

Shelving Recommendation
PEDIATRICS

ISBN 978-93-90595-14-3