docrinology books, visit our website www.jaypeebrothers.com, for detailed information on endocrinology boo

Celebrating 50 YEARS
Passion, Quality and Innovation in Healthcare Publishing

Case Studies in Diabetic Foot



SECOND EDITION

Ghanshyam Goyal

ILS Academics & Research Foundation

JAYPEE

Contents

Section 1: Diagnostic Tools *1–14*

1. **Semmes–Weinstein Monofilament** 3
2. **Biothesiometer (VPT)** 4
3. **Ankle Brachial Pressure Index or Ankle Brachial Index** 6
4. **Infrared Thermometer** 8
5. **Transcutaneous Oxygen Pressure** 10
6. **Hand-held Doppler** 12
7. **Harris Mat** 13

Section 2: Treatment Modalities *15–32*

8. **Callus Shaving** 17
9. **Samadhan System of Offloading** 19
10. **Total Contact Cast** 21
11. **Modified Posterior Slab** 23
12. **Negative Pressure Wound Therapy or Vacuum-assisted Closure** 24
13. **Hyperbaric Oxygen Therapy** 26
14. **Platelet-rich Plasma** 28
    - Case Study *29*
15. **Four-layer Compression Bandage** 31

Section 3: Neuropathic Unilateral Ulcers *33–90*

16. **Great Toe** 36
    - Case 1 : Neuropathic Great Toe Ulcer Treated with removable TCC *36*
    - Case 2 : Neuropathic Great Toe Ulcer *38*
    - Case 3 : Neuropathic Great Toe Ulcer on Amputed Stump *39*
    - Case 4 : Great Toe Ulcer due to Increased Plantar Pressure *41*
    - Case 5 : Neuropathic Great Toe Ulcer with Foot Deformity *43*
    - Case 6 : Osteomyelitis—Surgical Management *45*
    - Case 7 : Great Toe Ulcer Treated with Modified Posterior Slab *46*

- Case 8 : Great Toe Treated with Total Contact Cast with Window *48*
- Case 9 : Transitional Offloading *50*
- Case 10 : SK Offloading *52*

17. Metatarsal Head **54**
- Case 1 : Neuropathic Third Metatarsal Head Ulcer *54*
- Case 2 : SK Offloading and Modified Footwear *56*
- Case 3 : Modified Posterior Slab *58*

18. Heel **60**
- Case 1 : Neuropathic Ulcer in Heel *60*
- Case 2 : Neuropathic Heel Ulcer *62*
- Case 3 : Neuropathic Heel Ulcer Treated with Total Contact Cast *64*
- Case 4 : Neuropathic Heel Ulcer Treated with Total Contact Cast with Window *66*
- Case 5 : Neuropathic Ulcer in Heel Treated with Total Contact Cast with Window *68*
- Case 6 : Metatarsal Head Ulcer with Maggots *70*
- Case 7 : Heel Ulcer (Non Healing) *72*
- Case 8 : Heel Ulcer with Osteomyelitis *74*
- Case 9 : Heel Ulcer Treated with Modified Window Walking Cast *76*

19. Other Location **78**
- Case 1 : Rat Bite *78*
- Case 2 : Neuropathic Renal Foot with Toe Deformity *80*
- Case 3 : Diabetic Foot Ulcer on Dorsum of Foot with Interdigital Mycosis *83*
- Case 4 : Blister on Dorsum of Foot *85*
- Case 5 : Ulcer on Dorsum of Foot Following Shoe Bite *87*
- Case 6 : Leg Ulcer with Cellulitis *89*

Section 4: Neuropathic Bilateral Ulcers *91–108*

20. Great Toe **93**
- Case 1 : Bilateral Great Toe Ulcer *93*
- Case 2 : Bilateral Great Toe Ulcer with Osteomyelitis *96*
- Case 3 : Bilateral Diabetic Foot Ulcer with Nail Pathology *98*
- Case 4 : Hurricane Burn *100*

21. Metatarsal Head **101**
- Case 1 : Neuropathic Bilateral Plantar Surface Ulcers on First Metatarsal Head *101*
- Case 2 : Neuropathic Bilateral First Metatarsal Head Ulcer *104*

22. Other Location **106**
- Case 1 : Bilateral Leg and Foot Ulcers Following Chemical Burn Injury *106*

Section 5: Ischemic Cases *109–134*

23. Peripheral Arterial Disease **111**
- Case 1 : Ischemic Infected Foot *111*
- Case 2 : Neuroischemic Ulcer *114*
- Case 3 : Ischemic Ulcer due to Application of Compression Bandage *116*
- Case 4 : Ischemic Tendo-Achilles Ulcer *118*
- Case 5 : Ischemic Ulcer Treated with PTA *120*
- Case 6 : Ischemic Ulcer in a Case of CAD *123*
- Case 7 : Tram Car Injury *125*
- Case 8 : Ischemic Case *127*
- Case 9 : Great Toe Neuroischemic Ulcer *130*
- Case 10 : Ischemic Heel Ulcer *132*

Section 6: Osteomyelitis *135–156*

24. Medical Management of Osteomyelitis **137**
- Case 1 : Bilateral Neuropathic Great Toe Ulcer with Osteomyelitis *137*
- Case 2 : Bilateral Great Toe Ulcers with Osteomyelitis *140*
- Case 3 : Diabetic Foot Ulcer on Dorsum of Fifth Toe with Osteomyelitis *143*

25. Surgical Management of Osteomyelitis **145**
- Case 1 : Neuropathic Ulcer with Osteomyelitis *145*
- Case 2 : Fifth Toe Ulcer with Osteomyelitis *147*
- Case 3 : Infected Great Toe Ulcer with Osteomyelitis *150*
- Case 4 : Great Toe Ulcer on Dorsum with Osteomyelitis *152*
- Case 5 : Diabetic Foot Infection with Osteomyelitis *154*

Section 7: Charcot's Foot *157–190*

26. Unilateral, Bilateral, and Charcot's Foot in Renal Diseases (CKD) **161**
- Case 1 : Charcot's Foot: Right *161*
- Case 2 : Charcot's Foot: Left *164*
- Case 3 : Bilateral Charcot's Foot with Midfoot Ulcer in Left *166*
- Case 4 : Management of Charcot's Foot *168*
- Case 5 : Charcot's Foot *170*
- Case 6 : Management of Charcot's Foot in Stage IV CKD *173*
- Case 7 : Charcot's Foot with Deformity *175*
- Case 8 : Charcot's Joint *178*
- Case 9 : Acute Charcot with Osteomyelitis *180*
- Case 10 : Charcot Foot: Left with Midfoot Ulcer on Dorsum *182*

- Case 11 : Charcot Exostectomy *185*
- Case 12 : Surgical Management (Exostectomy) of Charcot Foot *187*

Section 8: Infected Diabetic Foot *191–232*

27. Mild, Moderate, and Severe Infections **194**
- Case 1 : Neuropathic Ulcer with Infection *194*
- Case 2 : Neuropathic Infected Foot *196*
- Case 3 : Severe Diabetic Foot Infection *198*
- Case 4 : Diabetic Foot Infection: Limb-threatening *200*
- Case 5 : Ischemic Infected Foot *202*
- Case 6 : Severe Diabetic Foot Infection *202*
- Case 7 : Multidisciplinary Management of a Complicated Infected Diabetic Foot *205*
- Case 8 : Ulcer After Hot Compression *208*
- Case 9 : Severe Diabetic Foot Infection *210*
- Case 10 : Limb-threatening Diabetic Foot Infection *212*
- Case 11 : Gangrene of 5th Toe: Amputated in OPD *214*
- Case 12 : Use of Advanced Modality in Severe Diabetic Foot Infection *216*
- Case 13 : Thermal Injury Leading to Severe Diabetic Foot Infection *218*
- Case 14 : Transitional Offloading in Plantar Surface Diabetic Foot Ulcer *220*
- Case 15 : Limb- to Life-threatening Diabetic Foot Infection *222*
- Case 16 : Moderate Diabetic Foot Infection with Ulceration *225*
- Case 17 : Filariasis with Diabetic Foot Infection *227*
- Case 18 : Bilateral Diabetic Foot Ulcer with Moderate Infection *229*

Section 9: Renal Foot *233–240*

28. Neuropathic Renal Foot **235**
- Case 1 : Neuropathic Renal Foot *235*
- Case 2 : Diabetic Renal Foot *238*

Section 10: Diabetic Hand Wounds: Not Uncommon *241–250*

29. Diabetic Hand Wounds: An Overlooked and Neglected Phenomenon **243**
- Case 1 : Thumb Injury in a Patient with Type 1 Diabetes Mellitus *244*
- Case 2 : Infection in Thumb Following Injury *245*
- Case 3 : Injury to Index Finger while Cutting Nail *246*
- Case 4 : Blister Over Palm of Right Hand *247*
- Case 5 : Infection in Forearm Following Trauma *248*
- Case 6 : Infection in Right Hand *249*

Section 11: Footwear Injury *251–254*

30. Footwear Injury **253**

Section 12: Foreign Body Injury *255–266*

31. Foreign Body Injury **257**
- Case 1 : Foreign Body Injury Caused by Barefoot Walking *257*
- Case 2 : Glass Prick in a Neuropathic Foot *259*
- Case 3 : Injury to an Insensate Diabetic Foot *262*
- Case 4 : Glass Piece Embedded in an Insensate Foot *265*

Section 13: Iceberg Phenomenon *267–274*

32. Iceberg Phenomenon: More than What Meets the Eye **269**
- Case 1 : Fungal Infection Progressing to Limb-threatening Infection *270*
- Case 2 : Blister over Dorsum Progressing to Limb-threatening Infection *272*

Section 14: Major Lower Limb Amputations *275–288*

33. Above Knee and Below Knee **277**
- Case 1 : Forefoot Amputation Following Foreign Body Prick *277*
- Case 2 : PAD Leading to Major Amputation *279*
- Case 3 : Diffuse PAD Leading to Major Amputation *282*
- Case 4 : PAD with Infected Heel *284*
- Case 5 : Diabetic Foot Infection: Limb- to Life-threatening *286*

Section 15: Venous Stasis Ulcers *289–298*

34. Venous Ulcers **291**
- Case 1 : Nonhealing Ulcer in Ankle Joint Area *292*
- Case 2 : Right Leg Ulcer *293*
- Case 3 : Noninfected Right Leg Ulcer *296*

Bibliography **299**

Index **301**

3

CHAPTER

Ankle Brachial Pressure Index or Ankle Brachial Index

JAYPEE BROTHERS

Ankle brachial pressure index (ABPI) is a noninvasive vascular screening test to identify large vessel, peripheral arterial disease by comparing systolic blood pressures in the ankle to the higher of the brachial systolic blood pressures, which is the best estimate of central systolic blood pressure. ABPI is performed using a continuous wave Doppler, a sphygmomanometer and pressure cuffs to measure brachial and ankle systolic pressures. The ankle brachial index (ABI) is the first-line test for both screening for peripheral arterial disease and for diagnosing it. It is inexpensive and noninvasive to obtain and has a high sensitivity (79–95%) and specificity (95–96%) (**Figs. 1** and **2**).

Ankle brachial pressure index is a ratio derived from dividing the higher of the ankle pressures (i.e., dorsalis pedis and posterior tibial) for each leg by the higher of the right and left arms' brachial systolic pressures. If blood flow is normal in the lower extremities, the pressure at the ankle should be equal or be slightly higher than that in the arm with an ABI of 1.0 or more. An ABI <0.9 indicates lower extremity arterial disease (**Table 1** and **Fig. 3**).



FIG. 1: Ankle brachial pressure test.



FIG. 2: Ankle brachial pressure recorder.

TABLE 1 **ABI value interpretation.**

Value	Clinical indication
1.0–1.30	Normal
0.91–0.99	Borderline PAD
≤0.90	Abnormal
0.71–0.90	Mild PAD
0.41–0.70	Severe PAD or CLI
>1.30	Vascular calcification

(ABI: ankle brachial index; CLI: critical limb ischemia; PAD: peripheral arterial disease)
Source: IDF Clinical Practice Recommendations on the Diabetic Foot – 2017

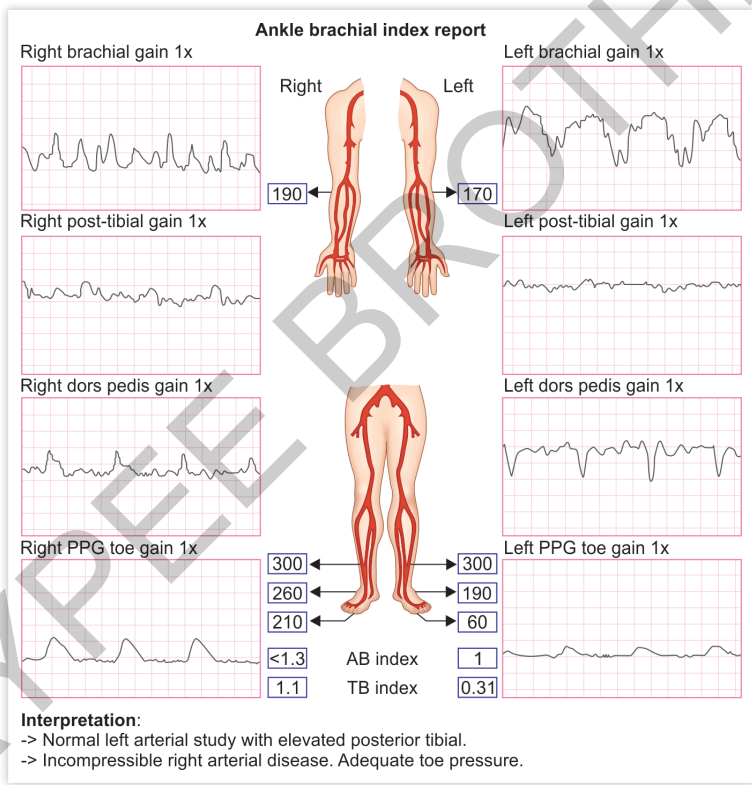

FIG. 3: Ankle brachial pressure report.

The purpose of the ABPI is to support the diagnosis of vascular disease by providing an objective indicator of arterial perfusion to a lower extremity.

The ABPI is an indirect examination that infers the anatomical location of an occlusion or stenosis. The exact location of the stenosis or occlusion cannot be determined by ABPI alone. ABPI interpretation is given in **Table 1**.

JAYPEE BROTHERS

or detailed information on endocrinology books, visit our website www.jaypeebrothers.com, for detailed infor

Case Studies in Diabetic Foot

Salient Features

- This is the second edition of the well-received previous edition of the subjected title with a quick and exciting read
- The diabetic foot is a deep-rooted complication of diabetes mellitus, a worldwide problem
- People with diabetes are susceptible to foot problems that occurs due to prolonged periods of high blood sugar levels
- This universal epidemic is promptly increasing at an alarming rate, majorly in developing countries and millions of people are basically affected in India
- This book almost covers major cases under various sections of diabetic foot starting from Treatment Modalities, Neuropathic Ulcers and Charcot's Foot
- Major Amputations, Foreign Body Injury and Iceberg Phenomena are majorly covered in separate sections
- The target audience of the book covers diabetologists, endocrinologists, resident physicians, medical students and medical fraternity involved in diabetic foot care.

Ghanshyam Goyal
MBBS MD (Medicine)
Consultant Diabetologist and Diabetic Foot Specialist
Director
ILS Hospitals, Salt Lake, Kolkata, West Bengal, India

Printed in India

Available at all medical bookstores
or buy online at www.jaypeebrothers.com



JAYPEE BROTHERS
Medical Publishers (P) Ltd.
EMCA House, 23/23-B, Ansari Road,
Daryaganj, New Delhi - 110 002, INDIA
www.jaypeebrothers.com

Join us on facebook.com/JaypeeMedicalPublishers

Shelving Recommendations
ENDOCRINOLOGY
DIABETOLOGY

