s.com, for detailed information on anatomy books, visit our website www.jaypeebrothers.com, for detailed information on anatomy books

Inderbir Singh's

Textbook of ANATOMY for DENTAL Students

Upper Extremity ▪ Lower Extremity ▪ Thorax ▪ Abdomen and Pelvis
Head and Neck ▪ Central Nervous System

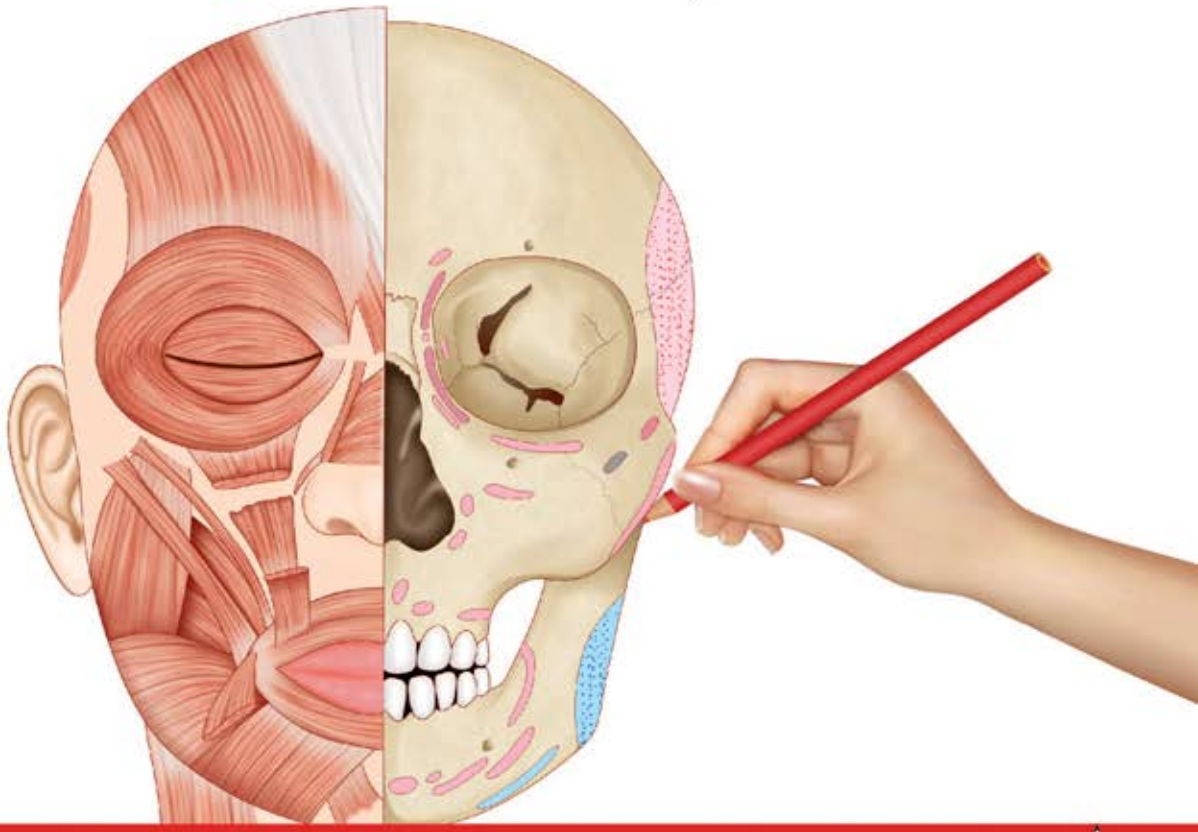

Revised by
V Subhadra Devi

JAYPEE

Contents

PART 1: UPPER EXTREMITY

1. Some Essential Terms **3**
The Subject of Anatomy 3
Main Subdivisions of the Human Body 3
Some Commonly Used Descriptive Terms 3
Structures Constituting the Human Body 6
How Muscles are Named 7
Some Features of Joints 8

2. Bones of Upper Extremity **13**
Skeleton of the Upper Limb 13
The Skeleton of the Hand 34

3. Pectoral Region, Axilla and Breast **44**
The Pectoral Region 44
Cutaneous Nerves of the Pectoral Region 44
Muscles of the Pectoral Region 45
The Axilla 48
The Axillary Artery 49
The Axillary Vein 53
Lymph Nodes and Lymphatic Drainage 53
Lymph Nodes of Upper Limb 54
The Brachial Plexus and its Branches 56
The Mammary Glands (Breasts) 64

4. The Back and Scapular Region **68**
The Back 68
Muscles of the Back 69
Nerves of the Back 69
The Scapular Region 73
Nerves of Scapular Region 79
Arteries of Scapular Region 80

5. Cutaneous Nerves and Veins of the Free Upper Limb **84**
Cutaneous Nerves of the Free Upper Limb 84
Veins of the Upper Limb 86
Anterior Compartment of the Arm 88
The Brachial Artery 91
Nerves of the Front of the Arm 94
Cubital Fossa 96
Posterior Compartment of the Arm 97

6. The Forearm and Hand **100**
Front of Forearm and Hand 100
Muscles of the Front of the Forearm 100

Important Fascia in the Wrist and Hand 104
Muscles in the Palm 106
Nerves of the Forearm and Hand 109
Arteries of the Forearm 118
Back of the Forearm and Hand 128
Muscles of the Back of the Forearm 128
Nerves and Arteries on the Back of the Forearm and Hand 133

7. General Features of Joints and Joints of the Upper Limb 135
Classification of Joints 135
Classification of Joints on the Basis of Structure 135
Classification of Joints on the Basis of Movements 139
Joints of the Upper Limb 141
Joints Connecting the Scapula and Clavicle 141
The Sternoclavicular Joint 141
The Shoulder Joint 143
The Elbow Joint 149
The Radioulnar Joints 151
The Wrist Joint 153
Other Joints of the Upper Limb 154

8. Surface Marking and Radiological Anatomy of Upper Limb 157
Surface Marking 157
Radiological Anatomy 162

PART 2: LOWER EXTREMITY

9. Bones of Lower Extremity 167
The Hip Bone 167
Pelvis as a Whole 177
The Femur 180
The Patella 186
The Tibia 188
The Fibula 193
The Skeleton of the Foot 197

10. Cutaneous Nerves, Veins and Lymphatic Drainage: Front and Medial Side of Thigh 209
Cutaneous Innervation of the Lower Limb 209
Veins of the Lower Limb 214
Lymph Nodes and Lymphatic Drainage of the Lower Limb 216
General Review of the Front and Medial Side of Thigh 218
Muscles of Front of Thigh 224
Muscles of Medial Side of Thigh 229
The Femoral Artery 232
Femoral Vein 235
Nerves on Front and Medial Side of Thigh 238

11. Gluteal Region, Back of Thigh and Popliteal Fossa 245
Gluteal Region 245
Muscles of the Gluteal Region 245
Arteries of Gluteal Region 248
Muscles of the Back of the Thigh 250

Popliteal Fossa 253
Popliteal Vessels 254
Nerves in the Gluteal Region and Back of Thigh 256
Sacral Ventral Rami and Sacral Plexus 256
The Sciatic Nerve 258
The Tibial Nerve 259
The Common Peroneal Nerve 260

12. Front and Lateral Side of Leg and the Dorsum of Foot 263
Compartments of the Leg 263
Muscles of Anterior Compartment of Leg 263
Extensor and Peroneal Retinacula 265
Muscles of Lateral Compartment of Leg 268
Blood Vessels of the Region 270
The Tibial Nerve (in Popliteal Fossa) 273
The Common Peroneal Nerve 274
The Deep Peroneal (Fibular) Nerve 274
The Superficial Peroneal (Fibular) Nerve 276

13. Back of Leg and Sole 278
Muscles of the Back of the Leg 279
Arteries of the Back of the Leg 286
Muscles and Related Structures in the Sole 288
Arteries of the Sole 294
The Tibial Nerve 297
Medial Plantar Nerve 298
The Lateral Plantar Nerve 300

14. Joints of the Lower Limb 303
Joints and Ligaments of the Pelvis 303
The Hip Joint 304
The Knee Joint 306
The Ankle Joint 313
Intertarsal Joints 315
Other Joints of the Lower Limb 316
Arches of the Foot 316

15. Surface Marking and Radiological Anatomy of the Lower Limb 319
Surface Marking 319
Radiological Anatomy 323

PART 3: THORAX

16. Bones Seen in Relation to the Thorax 329
Introduction to the Vertebral Column 329
Introduction to Skeleton of the Thorax 329
Structure of a Typical Vertebra 329
The Sternum 334
The Ribs 337

17. Intervertebral Joints and Joints of Sternum and Ribs 345
Intervertebral Joints 345
Joints of the Sternum 347

Joints of Ribs with Vertebral Column 348
Joints between Ribs, Costal Cartilages and Sternum 349
Movements of Ribs 351

18. Walls of the Thorax 353
Muscles of Thorax 353
Some Muscles of Thorax seen on the Back 354
The Diaphragm 356
Arteries of Thoracic Wall 363
Veins of the Thoracic Wall 366
Nerves of Thoracic Wall 368

19. The Trachea, Bronchi and Lungs 374
Introduction to the Respiratory System 374
The Thoracic Cavity 377
The Trachea 379
The Principal Bronchi 382
The Lungs 383
The Pleura 395

20. The Heart and Pericardium 401
Introduction to Cardiovascular System 401
Some Elementary Facts about the Heart 401
Exterior of the Heart 402
Interior of the Heart 405
Conducting System of the Heart 413
The Pericardium 413
Surface Projection of the Heart 415

21. Blood Vessels of the Thorax 419
The Pulmonary Trunk and Arteries 419
The Aorta 420
Branches of Aorta 425
Branches of the Arch of the Aorta 430
Branches of Descending Thoracic Aorta 432
Veins of the Thorax 433
Veins of the Heart 433
The Pulmonary Veins 435
The Superior Vena Cava 435

22. The Oesophagus, The Thymus, Lymphatics and Nerves of the Thorax 438
The Oesophagus 438
The Thymus 442
Lymphatics of the Thorax 444
Lymph Nodes of the Thorax 446
Nerves of the Thorax 450
The Phrenic Nerves 451
Preliminary Remarks on the Autonomic Nervous System 452
The Vagus Nerve 455
The Sympathetic Trunk 458

23. Surface Marking and Radiological Anatomy of the Thorax 463
Surface Marking 463
Radiological Anatomy of the thorax 467

PART 4: ABDOMEN AND PELVIS

24. Bones and Joints of the Abdomen **473**
Bones of the Abdomen 473
Lumbar Vertebrae 473
The Sacrum and Coccyx 476
Joints of the Abdomen 480

25. Introduction to the Abdomen and the Anterior Abdominal Wall **485**
Introduction to the Abdomen 485
Regions of the Abdomen 488
Some Introductory Remarks about the Peritoneum 490
The Anterior Abdominal Wall 491
Anterolateral Muscles of Abdominal Wall 491

26. The Perineum and Related Genital Organs **512**
Introduction to the Perineum 512
The Testis and Epididymis 513
The Ductus Deferens 515
The Spermatic Cord 516
The Penis 520
The Perineum 522
Anal Triangle and Ischiorectal Fossa 528
Vessels of the Perineum 531
Nerves of the Perineum 532

27. Oesophagus, Stomach and Intestines **535**
Abdominal Part of Oesophagus 535
The Stomach 535
The Small Intestine 541
The Jejunum and Ileum 544
The Large Intestine 545
The Vermiform Appendix 553
The Sigmoid Colon 558
Innervation of the Gut 559

28. The Liver, Pancreas and Spleen **561**
The Liver 561
Extrahepatic Biliary Apparatus 573
The Pancreas 576
The Spleen 580

29. Blood Vessels of Stomach, Intestines, Liver, Pancreas and Spleen **583**
The Coeliac Trunk and its Branches 583
Superior Mesenteric Artery 587
Inferior Mesenteric Artery 589
The Hepatic Portal System 590

30. Kidney, Ureter and Suprarenal Gland **595**
Introduction to the Urinary System 595
The Kidneys 595
The Ureters 600
The Suprarenal Glands 604

31. Posterior Abdominal Wall and Some Related Structures **608**
Muscles of Posterior Abdominal Wall 610
The Abdominal Aorta 612
Branches of Abdominal Aorta 614
The Inferior Vena Cava and its Main Tributaries 619
Nerves of Posterior Abdominal Wall 625

32. Walls of the Pelvis **629**
Muscles and Fascia of Pelvic Wall 629
Blood Vessels of True Pelvis 632
Nerves of the Pelvis 637

33. Pelvic Viscera and Peritoneum **639**
Pelvic Viscera 639
The Rectum 639
The Anal Canal 642
The Ureters 649
The Urinary Bladder 651
The Urethra 657
The Prostate 661
The Ovaries 664
The Uterine Tubes 666
The Uterus 668
The Vagina 671
The Peritoneum 673

34. Lymphatics and Autonomic Nerves of Abdomen and Pelvis **684**
Lymphatics of Abdomen and Pelvis 684
Chief Lymph Nodes of Abdomen and Pelvis 684
Lymphatic Drainage of Abdominal and Pelvic Viscera 685
Autonomic Nerves of Abdomen and Pelvis 692
Parasympathetic Nerves in Abdomen and Pelvis 693
Sympathetic Nerves in Abdomen and Pelvis 694

35. Surface and Radiological Anatomy of the Abdomen **697**
Regions of the Abdomen 697
Relationship of Inguinal Canal to the Surface of the Abdominal Wall 697
Surface Marking of Parts of the Gastrointestinal Tract 697
Surface Marking of Biliary Apparatus, Pancreas and Spleen 701
Surface Marking of Urinary Organs 702
Surface Marking of Some Arteries 704
Surface Marking of Some Large Veins 705
Radiological Anatomy of the Abdomen and Pelvis 706

PART 5: HEAD AND NECK

36. Bones and Joints of the Head and Neck **715**
Vertebral Column 715
Atypical Cervical Vertebrae 716
The Skull 719
The Mandible 738
The Hyoid Bone 741

Joints of Head and Neck 743
The Atlanto-axial Joints 744
The Atlanto-occipital Joints 745

37. Scalp, Face, Parotid Region and Lacrimal Apparatus 748
The Scalp 748
The Face 751
Muscles of the Face 757
Parotid Gland 760
Vessels of the Face and Parotid Region 765
Lymph Nodes of Head and Neck 766
Nerves of the Face 766

38. Temporal and Infratemporal Regions 768
Temporal Region 768
Infratemporal Fossa 769
Muscles of Mastication 772
The Temporomandibular Joint 776

39. Submandibular Region and Tongue 779
The Submandibular Gland 779
The Sublingual Gland 781
Suprahyoid Muscles 783
The Tongue 784
Muscles of the Tongue 787
Blood Vessels, Lymphatics, and Nerves of the Tongue 787

40. Cranial Cavity and Vertebral Canal 795
The Cranial Cavity 795
The Meninges 796
Nerves and Arteries in the Cranial Cavity 803
The Spinal Cord 807

41. Muscles of the Neck, Triangles of the Neck, Deep Cervical Fascia and Lymph Nodes 813
Muscles of the Neck 813
The Platysma 813
The Sternomastoid and Trapezius 813
Infrahyoid Muscles 813
The Lateral Vertebral Muscles 814
Anterior Vertebral Muscles (Prevertebral Muscles) 815
Deep Muscles of the Back 815
Triangles of the Neck 821
The Posterior Triangle 823
Subdivisions of the Anterior Triangle 824
Suboccipital Triangle 826
Deep Cervical Fascia 827
Investing Layer 827
Pretracheal Fascia 828
Prevertebral Fascia 828
Carotid Sheath 828
Lymph Nodes of Head and Neck 829

42. Blood Vessels of Head and Neck **833**
Arteries 833
The Common Carotid Arteries 833
Internal Carotid Artery 834
The External Carotid Arteries 838
The Subclavian Arteries 847
Veins 854
The Internal Jugular Veins 854
The Subclavian Veins 855
The Intracranial Venous Sinuses 855
Tributaries of Internal Jugular Veins in the Neck 860
Other Veins of the Head and Neck 861

43. Nerves of the Head and Neck **868**
Cervical Nerves 868
The Cervical Plexus and its Branches 870
The Cranial Nerves 874
Types of Fibres in Peripheral Nerves 875
Cranial Nerve Nuclei 879
The Olfactory Nerves 883
The Optic Nerve 884
The Oculomotor Nerve 887
The Trochlear Nerve 891
The Abducent Nerve 891
The Trigeminal Nerve 893
The Ophthalmic Nerve 895
The Maxillary Nerve 898
The Facial Nerve 908
The Vestibulocochlear Nerve 916
The Glossopharyngeal Nerve 918
The Vagus Nerve 923
The Accessory Nerve 927
The Hypoglossal Nerve 929
Cervical Part of Sympathetic Trunk 931

44. Orbit, Eye and Ear **935**
The Orbit 935
Contents of the Orbit 935
Muscles of the Orbit 935
The Lacrimal Gland 939
Nerves and Vessels of Orbit 940
The Eyeball 943
The Ear and Some Related Structures 953
The Auricle 955
External Acoustic Meatus 956
The Middle Ear 957
The Internal Ear 969

45. Oral Cavity, Nasal Cavity, Pharynx, Larynx, Trachea and Oesophagus **976**
The Oral Cavity and Some Related Structures 976
The Oral Cavity 976
The Palate 978

Muscles of the Soft Palate 978
The Teeth 981
The Nasal Cavities and Paranasal Sinuses 984
The Paranasal Sinuses 988
The Pharynx 991
Muscles of the Pharynx 994
The Palatine Tonsils 996
The Larynx 998
Interior of the Larynx 1000
Muscles of the Larynx 1002
The Trachea 1005
The Oesophagus 1006

46. Endocrine Glands of the Head and Neck, Carotid Sinus and Carotid Body 1007
The Hypophysis Cerebri 1007
The Pineal Body 1013
The Thyroid Gland 1014
The Parathyroid Glands 1019
The Carotid Sinus 1020
The Carotid Bodies and Paraganglia 1021

47. Surface Marking and Radiological Anatomy of Head and Neck 1022
Surface Marking 1022
Surface Marking of Some Viscera 1022
Paranasal Sinuses 1023
Arteries 1023
Veins 1025
Intracranial Venous Sinuses 1025
Nerves 1026
Radiological Anatomy 1028

PART 6: CENTRAL NERVOUS SYSTEM

48. Introduction to Central Nervous System and Internal Structure of Spinal Cord 1033
Introduction to the Central Nervous System 1033
Internal Structure of Spinal Cord 1037

49. Gross Anatomy of Brain 1040
Gross Anatomy of the Brainstem 1040
Preliminary Review of the Internal Structure of the Brainstem 1043
Gross Anatomy of the Cerebellum 1048
Gross Anatomy of the Cerebral Hemispheres 1051
An Introduction to Some Structures within the Cerebral Hemispheres 1059
Important Functional Areas of the Cerebral Cortex 1061
White Matter of Cerebral Hemispheres 1063

50. Tracts of Spinal Cord and Brainstem; and Cerebellar Connections 1066
Tracts of Spinal Cord and Brainstem 1066
Descending Tracts Ending in the Spinal Cord 1066
Descending Tracts Ending in the Brainstem 1071
Ascending Tracts 1072

Connections of the Cerebellum 1078
Cerebellar Peduncles 1078

51. Internal Structure of Brainstem 1084
The Medulla 1084
The Pons 1089
The Midbrain 1091

52. Diencephalon, Basal Ganglia, Olfactory Region and Limbic System 1096
The Diencephalon 1096
The Thalamus 1096
The Hypothalamus 1100
The Metathalamus 1105
The Epithalamus 1105
The Subthalamic Region 1106
The Basal Ganglia 1106
The Olfactory Region and Limbic System 1109
The Olfactory Region 1109
The Olfactory Pathway 1110
The Limbic System 1111

53. Internal Capsule Commissures 1116
The Internal Capsule 1116
Commissures of the Brain 1119

54. Pathways for Special Senses 1120
Visual Pathway 1120
Pathway for Hearing 1124
Pathways for Taste 1126
Pathways for Smell 1126

55. Ventricles of the Brain and Cerebrospinal Fluid 1127
The Lateral Ventricles 1127
The Third Ventricle 1129
The Fourth Ventricle 1131
The Cerebrospinal Fluid 1134

56. Blood Supply of the Brain and Some Investigative Procedures for Neurological Diagnosis 1137
Arteries that Supply the Brain 1137
Arterial Supply of the Cerebral Cortex 1141
Arteries Supplying the Interior of the Cerebral Hemisphere 1143
Venous Drainage of the Brain 1146

Index 1153

4 The Back and Scapular Regio

CHAPTER

THE BACK

1. The posterior aspect of the thorax and abdomen is referred to simply as the ***back***.
2. Here, there is a deep layer of muscles belonging to the back proper (studied along with the head and neck
3. Superficial to them there are several muscles that belong to the upper limb, but are placed on the back. Some these are inserted into the scapula while others reach the humerus.
4. The muscles of the upper limb present on the back and in the shoulder region produce important movements of the upper limb. To understand their actions properly it is necessary to explain some facts about these movements before we study the muscles.

Movements of the Arm

1. The basic movements to be seen at any joint are flexion, extension, abduction, adduction, and rotatory movements. In the case of the arm, these movements are somewhat different than at most joints. Note the follow
2. Movements of the arm take place at the shoulder joint that is formed by articulation of the head of the humerus with the glenoid cavity of the scapula.
3. In relation to the wall of the thorax the scapula is placed obliquely so that its costal surface faces forwards ***medially***, while the dorsal surface faces backwards ***and laterally***. Because of this orientation the glenoid cavity does not face directly laterally, but faces ***forwards and laterally***.
4. As movements of the arm are described with reference to the plane of the scapula (and not in relation to trunk) the definition of some movements is somewhat different from that for other joints as follows:
   a. In the neutral position the arm hangs vertically by the side of the trunk.
   b. Flexion and extension take place in a plane ***at right angles to the plane of the scapula***.
   c. In ***flexion*** the arm moves forwards (4.1) ***and somewhat medially***.
   d. Reversal of this movement (i.e., bringing it back to the side of the trunk) is ***extension***.
   e. Continuation of extension beyond the vertical position of the arm is called ***hyperextension***.
   f. The movements of abduction and adduction take place ***in the plane of the scapula***.
   g. In this movement the arm moves laterally, and somewhat forwards (4.2).
   h. After reaching the horizontal position (i.e., from 1 to 2 in 4.2) the movement can be continued to raise arm to a vertical position (3): this is referred to as ***overhead abduction***.
   i. Bringing the arm back to the neutral position (i.e., back to 1) is called ***adduction***.
   j. Further adduction brings the arm in front of the chest (4). Abduction and adduction take place partly at shoulder joint, and partly by rotation of the scapula.
   k. The rotatory movements of the arm are ***medial rotation*** and ***lateral rotation*** (4.3A and B).
   l. A rotation of the humerus that carries the flexed forearm medially is medial rotation.
   m. The opposite movement in which the forearm is carried laterally is lateral rotation.
   n. Note further that rotation is named with reference to the the ***front*** of the humerus.
   o. It follows that any muscle passing from the trunk (or scapula) to the front of the humerus will be a medial rotator. A muscle passing to the back of the humerus will be a lateral rotator.

JAYPEE BROTHERS

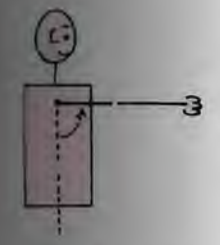

4.1: Scheme to illustrate the movement of flexion of the arm

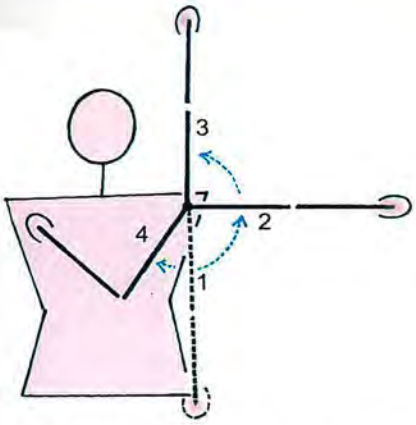

4.2: Scheme to illustrate abduction and adduction of the arm

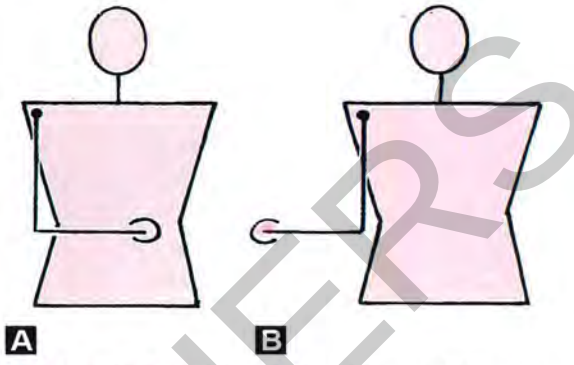

4.3A and B: (A) Medial rotation of the arm (B): Lateral rotation of the arm

Movements of the Scapula

These are as follows:

1. In ***protraction***, the entire scapula slides forwards over the chest wall. Reversal of this movement is ***retraction***.
2. In ***elevation***, the entire scapula moves upwards (as in shrugging the shoulders); and the opposite movement is called ***depression***.
3. In addition to these simple movements the scapula can undergo rotation.
   a. To understand this movement imagine that the scapula is transfixed by an imaginary nail passing through the centre of its body (4.4A and B).
   b. Rotation is named in terms of movement of the inferior angle of the scapula.
4. In ***forward rotation*** (also called ***lateral rotation***) the inferior angle of the scapula passes forwards and somewhat laterally (4.4B).
   a. Simultaneously, the superior angle and the acromion pass backwards and medially.
   b. The glenoid cavity comes to face upwards.
   c. This movement takes place during abduction of the arm, and is essential for raising the arm above the head.
5. Reversal of this movement constitutes ***backward (or medial) rotation***.

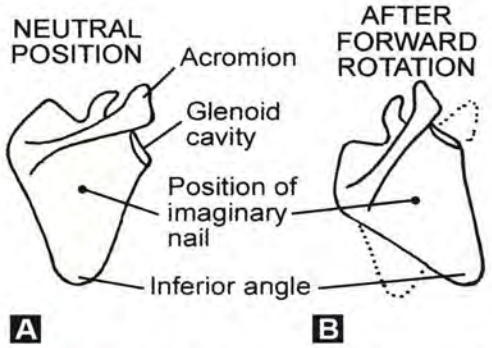

4.4A and B: (A) Neutral position of the scapula (B): Position of the scapula after forward rotation

MUSCLES OF THE BACK

1. The trapezius is described in 4.5 and illustrated in 4.6.
2. The latissimus dorsi is described in 4.7 and illustrated in 4.8.
3. Three muscles: the levator scapulae, the rhomboideus minor and rhomboideus major are described in 4.9 and the attachments of the levator scapulae are shown in 4.10.

NERVES OF THE BACK

Cutaneous Nerves of the Back

1. The skin of the back is supplied mainly by cutaneous branches arising from dorsal rami of spinal nerves (4.11). The lateral parts of the back are innervated by cutaneous branches from ventral rami. Note that dorsal rami make no contribution to the cutaneous supply of the free upper limb.

JAYPEE BROTHERS

4.5: Trapezius	
Origin	1. Superior nuchal line (medial one-third) 2. External occipital protuberance 3. Ligamentum nuchae 4. Spines of vertebrae C7 to T12 5. Intervening supraspinous ligaments
Insertion	1. Clavicle (posterior border of lateral one-third) 2. Acromion (medial margin) 3. Scapula (crest of spine and tubercle on it)
Nerve supply	1. Accessory nerve, spinal part (motor) 2. Branches from nerves C3, 4 (sensory)
Action	1. Forward rotation of scapula (with serratus anterior) 2. Elevation of scapula (with levator scapulae) 3. Retraction of scapula (with rhomboids) 4. Draws head backwards and laterally. When muscles of both sides act the head is drawn directly backwards

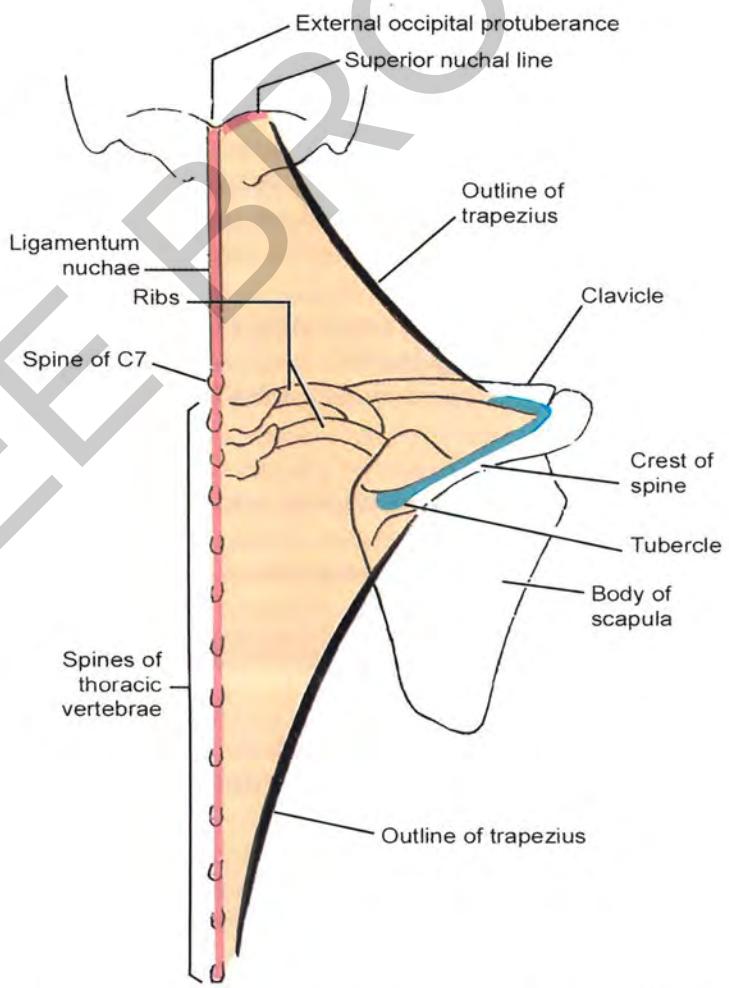

4.6: Scheme to show the attachments of the trapezius

JAYPEE BROTHERS

4.7: Latissimus dorsi	
Origin	1. Spines of vertebrae T7 to T12 2. Intervening supraspinous ligaments 3. Lumbar fascia 4. Slip from iliac crest 5. Slips from lowest 3 or 4 ribs 6. Slip from inferior angle of scapula
Insertion	Muscle ends in a tendon which is inserted into anterior aspect of upper end of humerus, in floor of intertubercular sulcus
Nerve supply	Thoracodorsal nerve (C6, 7, 8)
Action	1. Adduction and medial rotation of arm 2. Extension of flexed arm, against resistance 3.Depression of raised arm against resistance (with pectoralis major) 4. Elevation of trunk (when the arms are raised and fixed) (with pectoralis major)
Notes	Fibres of the muscle converge towards axilla and end in a tendon that winds round the lower border of the teres major. The two form the posterior fold of the axilla

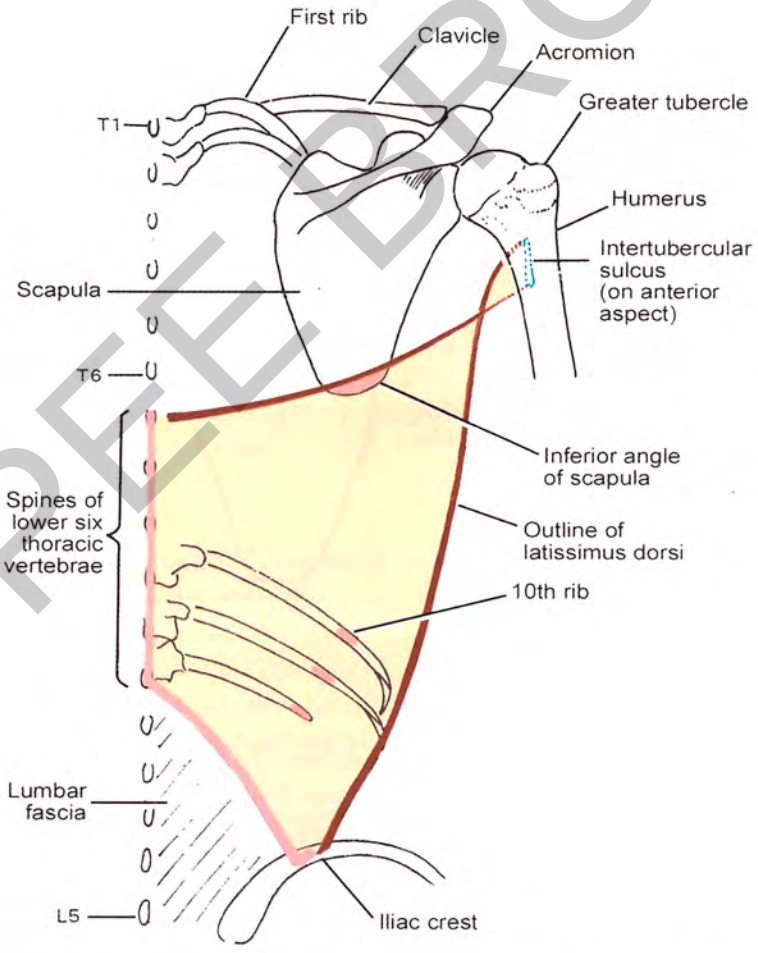

4.8: Scheme to show the attachments of the latissimus dorsi

JAYPEE BROTHERS

4.9: Levator scapulae, rhomboideus minor and rhomboideus major

Muscle	*Levator Scapulae*	*Rhomboideus Minor*	*Rhomboideus Major*
Origin	Transverse processes of upper four cervical vertebrae	1. Lowest part of ligamentum nuchae 2. Spines of vertebrae C7 and T1	1. Spines of vertebrae T2 to T5 2. Intervening supraspinous ments
Insertion	Medial border of scapula from superior angle to root of spine	Medial border of scapula opposite root of spine	Medial border of scapula, root of spine up to inferior an
Nerve supply	1. Branches from spinal nerves C3, C4. 2. Dorsal scapular nerve	Dorsal scapular nerve (C4, 5)	Dorsal scapular nerve (C4,5)
Action	1. Elevation of scapula 2. Backward rotation of scapula 3. Stabilization of scapula during movements of upper limb 4. Bends neck to its own side	1. Retraction of scapula 2. Backward rotation of scapula 3. Stabilization of scapula during movements of upper limb	1. Retraction of scapula 2. Backward rotation of scapu 3. Stabilization of scapula dur movements of upper limb

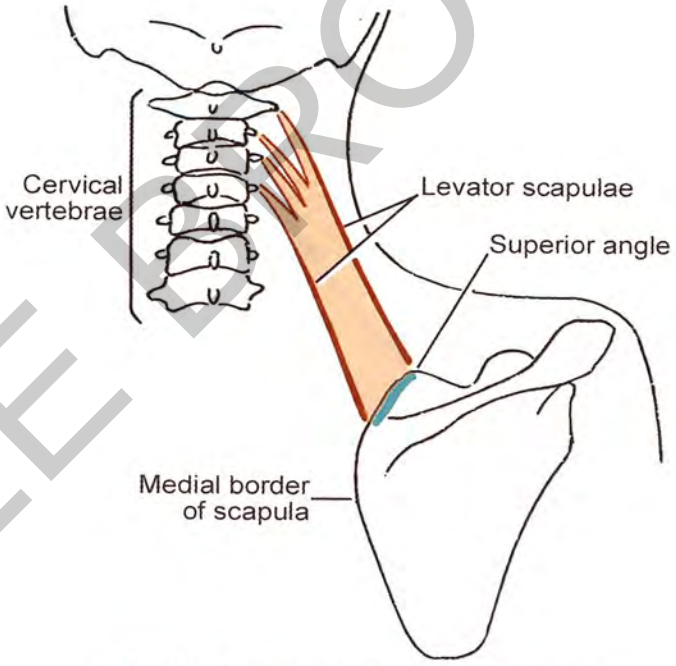

4.10: Attachments of the levator scapulae

2. Each dorsal ramus divides into medial and lateral branches. These branches supply deep muscles of the (erector spinae). [These muscles do not belong to the upper limb. In fact, no muscle of either the upper or l limb is innervated by dorsal rami].
3. Of the two branches of a dorsal ramus only one gives off cutaneous branches.
   a. In the cervical and upper thoracic region these arise from the medial branches, and become superficial the middle line of the back.
   b. In the lower thoracic and lumbar region the cutaneous branches arise from the lateral branch, and be superficial along a line corresponding to the lateral edge of the erector spinae.

JAYPEE BROTHERS

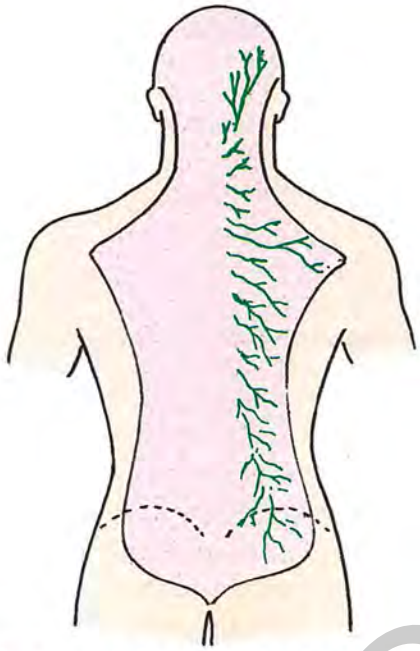

4.11: Area of skin of the back supplied by dorsal rami of spinal nerves

Nerves Supplying Muscles

Spinal part of accessory nerve

1. Running downwards deep to the trapezius, and supplying it, there is the spinal part of the accessory nerve.
2. The accessory nerve is the eleventh cranial nerve. It has a cranial part arising from the medulla oblongata of the brain, and a spinal part arising from the upper part of the spinal cord.
3. The two parts unite for a short part of their course and again separate.
4. This nerve will be studied in detail when we consider the head and neck.
   a. Here we may note that the spinal part of the nerve reaches the trapezius in the lower part of the neck and descends into the back, deep to this muscle.
   b. We have already seen that the trapezius also receives branches from the cervical plexus (C3, C4) but these probably carry only proprioceptive fibres.

Dorsal Scapular Nerve

1. The dorsal scapular nerve arises from root C5 of the brachial plexus.
2. It passes backwards and downwards through the lower part of the neck (through the scalenus medius) to reach the anterior aspect of the levator scapulae.
3. It then descends into the back to reach the anterior (i.e., deep) aspect of the rhomboideus muscles. Here, it is accompanied by the dorsal scapular artery (or the deep branch of the transverse cervical artery).
4. The dorsal scapular nerve supplies the rhomboideus major and minor and may give a branch to the levator scapulae.

THE SCAPULAR REGION

In the scapular region we see several muscles that take origin from the scapula and gain insertion into the humerus These are:

1. The deltoid muscle (4.12 and 4.13)
2. The supraspinatus (4.14)

JAYPEE BROTHERS

3. The infraspinatus (4.15 and 4.16)
4. The teres minor (4.15 and 4.17)
5. The teres major (4.15, 4.18 and 4.20)
6. The subscapularis (4.19 and 4.20).



WANT TO KNOW MORE?

Relations of the deltoid muscle

The deltoid muscle covers the region of the shoulder joint from the lateral side, the front and the back. It there covers a large number of structures. These are:

1. Upper end of the humerus.
2. Coracoid process.
3. Coracoacromial ligament.
4. Pectoralis minor.
5. Origins of the long and short heads of the biceps brachii and of the coracobrachialis.
6. Insertion of the pectoralis major, teres major, latissimus dorsi, and the long head of the triceps.
7. Insertions of the supraspinatus, infraspinatus and teres minor (by posterior part of deltoid).
8. Origin of the lateral head of the triceps (by posterior part of deltoid).
9. Axillary nerve.
10. Anterior and posterior circumflex humeral arteries.
11. There are a number of bursae deep to the deltoid, the most important of which is the subacromial bursa (a called the subdeltoid bursa).



CLINICAL CORRELATION

Paralysis of the deltoid

1. Paralysis of the deltoid, followed by atrophy, occurs when the axillary nerve is injured.
   a. Because of atrophy, the rounded contour of the shoulder is lost and there may be a slight hollow bel the acromion.
   b. There is loss of sensation on the lateral side of the upper part of the arm.
2. To test the deltoid muscle the examiner first abducts the patient's arm to 15 degrees. He then asks the pati to continue abduction against resistance.
3. Injury to the axillary nerve can occur in fracture through the surgical neck of the humerus.

Mechanism of Abduction of the Arm

1. Abduction of the arm is a complicated movement and the deltoid is one of the most important muscles for
2. The supraspinatus also has an important role.
3. This is, therefore, an appropriate place for us to examine the contribution of various muscles to this movem
4. Abduction of the arm takes place partly at the shoulder joint, and partly by rotation of the scapula as explai below.
   a. The first few degrees of abduction at the shoulder joint are produced by the supraspinatus.
   b. The deltoid produces abduction of the arm at the shoulder joint up to about 90 degrees.
   c. Further abduction is produced by forward rotation of the scapula. The muscles responsible for this ac are the serratus anterior and the trapezius acting together.

JAYPEE BROTHERS

4.12: Deltoid	
Origin	1. Clavicle: upper surface and anterior border of lateral one-third 2. Acromion: lateral margin and upper surface 3. Spine of scapula: lower lip of crest
Insertion	Deltoid tuberosity on lateral aspect of shaft of humerus
Nerve supply	Axillary nerve (C5, 6)
Action	1. Abduction of arm at shoulder joint up to 90 degrees (This is by acromial fibres) 2. Flexion and medial rotation of humerus (anterior fibres) 3. Extension and lateral rotation of humerus (posterior fibres)
Notes	See notes on mechanism of abduction of arm and relations of deltoid given below

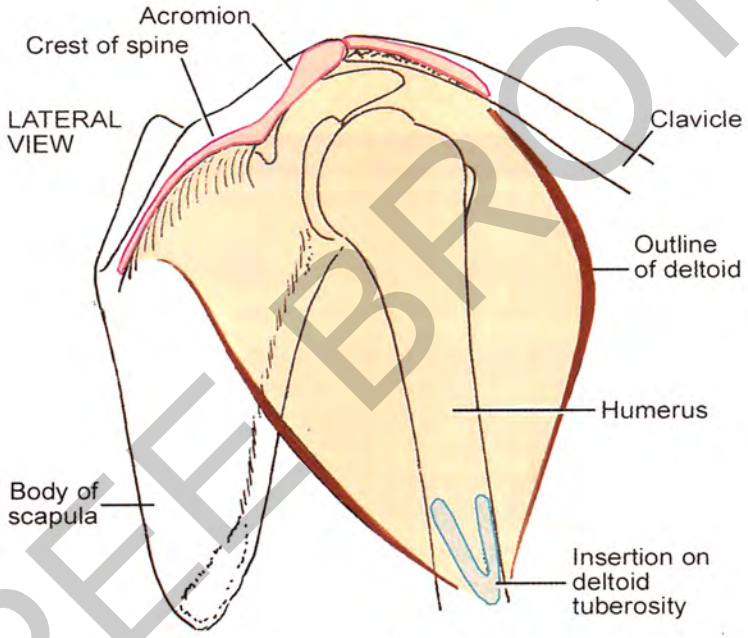

4.13: Attachments of the deltoid muscle

4.14: Supraspinatus	
Origin	Posterior aspect of scapula (medial two-thirds of supraspinous fossa)
Insertion	Greater tubercle of humerus (uppermost impression)
Nerve supply	Suprascapular nerve (C4, 5, 6)
Action	1. Stabilises shoulder joint (along with other muscles around the joint) 2. Abduction of arm (first few degrees)
Notes	1. The muscle passes under the coracoacromial arch 2. See clinical note below

JAYPEE BROTHERS

4.15: Infraspinatus , teres major and teres minor

Muscle	*Infraspinatus*	*Teres Minor*	*Teres Major*
Origin	Scapula, posterior aspect (medial two-thirds of infraspinous fossa)	Scapula, posterior aspect (along upper two-thirds of lateral border)	Scapula, posterior aspect (Inf angle, and lower one-third of eral border)
Insertion	Posterior aspect of upper end of humerus, middle impression on greater tubercle	Posterior aspect of upper end of humerus, lowest impression on greater tubercle	Anterior aspect of upper end humerus, on medial lip of int bercular sulcus
Nerve supply	Suprascapular nerve (C4, 5, 6)	Axillary nerve	Lower subscapular nerve (C6
Action	1. Both these muscles are adductors and lateral rotators of the humerus 2. They stabilise the shoulder joint and strengthen the posterior part of the capsule 3. During abduction of the arm (by deltoid and supraspinatus) their downward pull neutralises the upward pull of the deltoid and prevents the head of the humerus from getting stuck under the coracoacromial arch. (The subscapularis has a similar role)		1. Adductor and medial rotat arm 2. Helps in extension of arm 3. Aids abduction of the arm like the infraspinatus 4. Strengthens capsule of sho joint and stabilises it

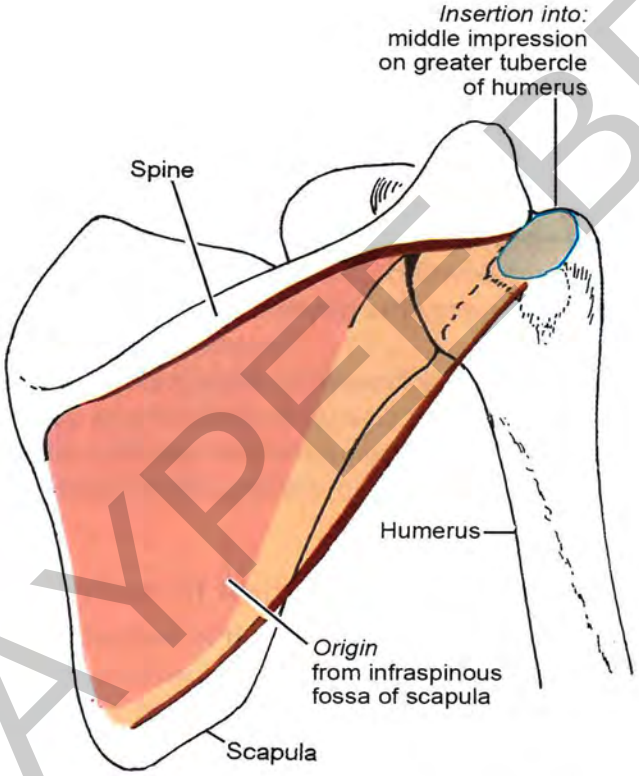

4.16: Attachments of the infraspinatus

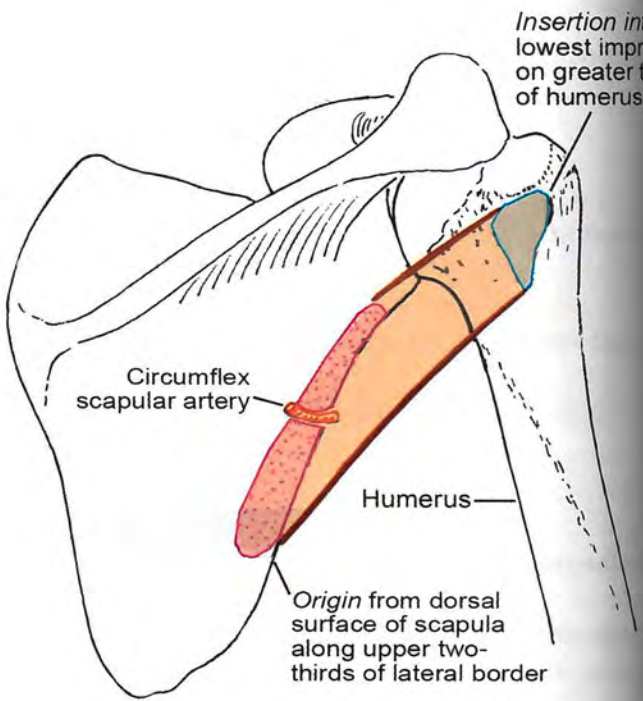

4.17: Attachments of the teres minor

JAYPEE BROTHERS

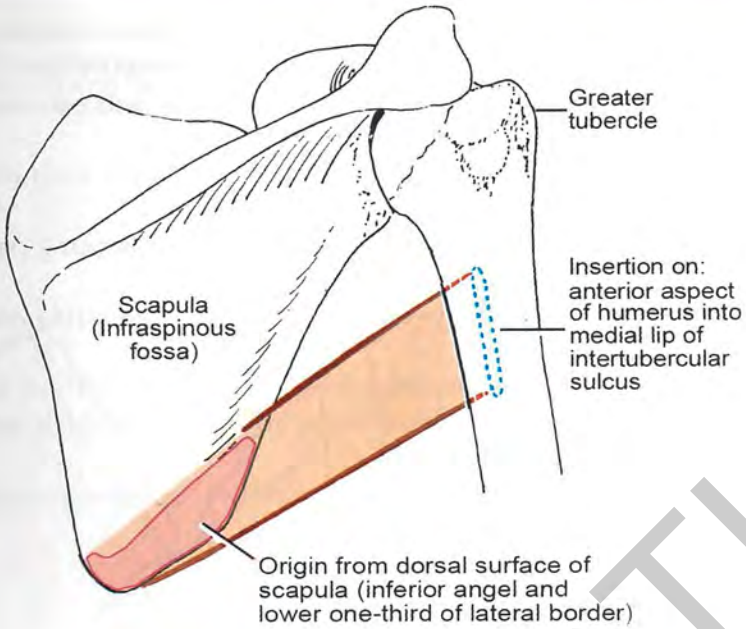

4.18: Attachments of the teres major

4.19: Subscapularis	
Origin	Scapula, costal surface (medial two-thirds of subscapular fossa)
Insertion	Lesser tubercle of humerus
Nerve supply	Upper and lower subscapular nerves (C5, 6, 7)
Action	1. Adductor and medial rotator of arm 2. Helps in extension of arm 3. Its downward pull on the humerus cancels the upward pull of the deltoid and allows smooth abduction of the arm 4. Strengthens capsule of shoulder joint and stabilises it These actions are the same as those of the teres major
Notes	The subscapularis and teres major form the posterior wall of the axilla. The contents of the axilla lie over them

Musculotendinous Cuff of Shoulder

1. As the tendons of the subscapularis, teres minor, supraspinatus and infraspinatus approach their insertions they flatten and their edges unite with each other.
2. In this way a strong cuff (covering) is formed for the shoulder joint. This is an important factor in giving strength to the joint.
3. As these muscles are all rotators of the humerus, this structure is also called the ***rotator cuff***.



CLINICAL CORRELATION

1. The cuff does not extend on to the inferior aspect of the shoulder joint, leaving a weak region through which dislocation of the head of the humerus can take place more easily than in any other direction.

JAYPEE BROTHERS

2. ***Rupture of the tendinous cuff*** involves injury mainly to the supraspinatus tendon.
   a. It is more likely to occur in old persons because of degeneration with age.
   b. The patient is unable to initiate abduction at the shoulder joint, but can maintain it once the arm is p tially abducted.
3. ***Strain of the supraspinatus*** is common in persons who have to work for long periods with the arms in s abduction (e.g., typists). It can cause distressing and persistent pain.
4. The ***subacromial bursa*** lies deep to the coracoacromial arch and the adjoining part of the deltoid muscle.
   a. The bursa facilitates abduction at the shoulder joint.
   b. During overhead abduction, the greater tuberosity slips below the bursa and comes to lie deep to th romion.
   c. When the bursa is inflamed (***subacromial bursitis***) pressure over the deltoid, just below the acromion e pain, but pain cannot be elicited after abduction of the arm (because the bursa is now under the acrom This is called ***Dawbarn's sign***.
   d. Subacromial bursitis is usually associated with inflammation of the supraspinatus tendon.

Quadrangular and Triangular Spaces

In 4.21 note the following:

1. The lower border of the teres minor is separated by a gap from the upper border of the teres major.
2. More anteriorly, the lower border of the subscapularis forms the upper boundary of the gap.
3. The gap mentioned above is divided into medial and lateral parts by the long head of the triceps.
4. The medial part is quadrangular in shape and is called the ***quadrangular space***. The lateral part of the g triangular in shape and is called the ***triangular space***.

The Quadrangular Space

It boundaries are formed as follows:

1. Upper border, by the teres minor and the subscapularis.
2. Lower border, by the teres major.

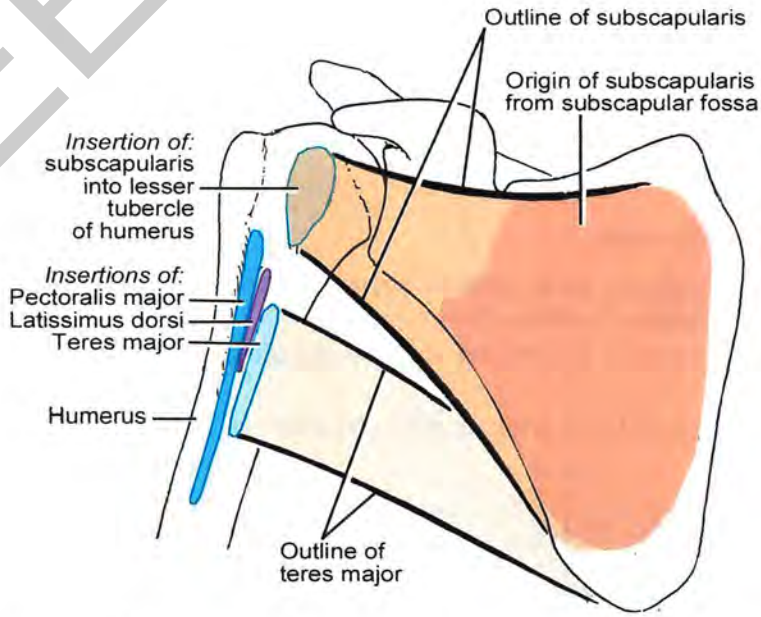

4.20: Attachments of the subscapularis. The teres major is also shown. Note the various insertions in the intertubercular sulcus

JAYPEE BROTHERS

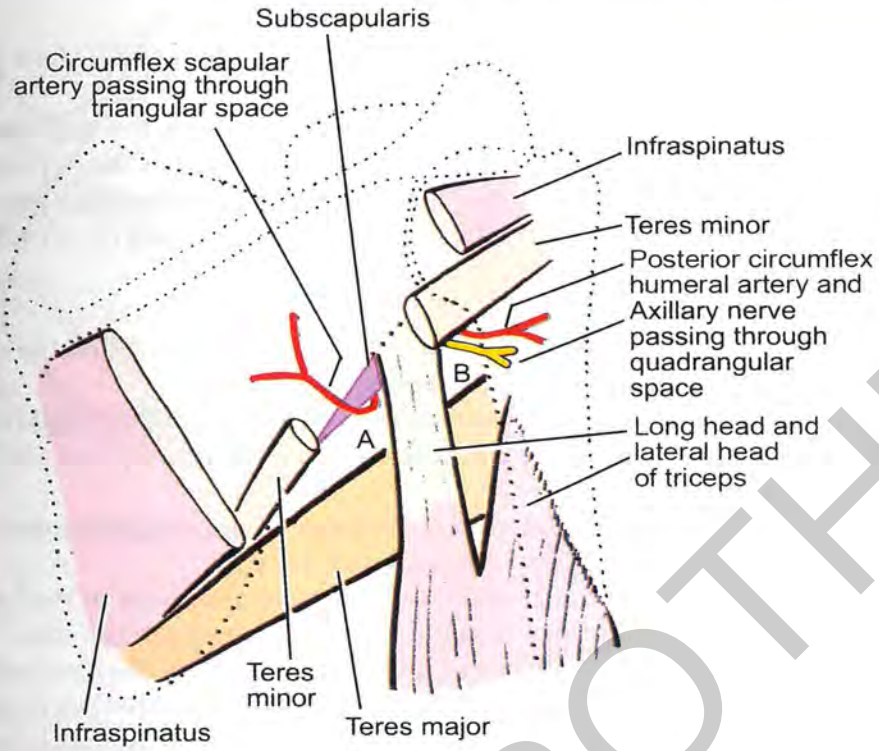

4.21: Diagram to show the triangular space (A), and the quadrangular space (B), of the scapular region

3. Medial border by the long head of the triceps.
4. Lateral border by the surgical neck of the humerus.

The structures passing through this space are:

1. The axillary nerve
2. The posterior circumflex humeral artery.

The Triangular Space

1. Its upper and lower boundaries are the same as those of the quadrangular space.
2. Its lateral boundary is formed by the long head of the triceps.
3. The circumflex scapular branch of the subscapular artery passes through this space.

Lower Triangular Space

1. Just below the teres major (in the arm) we see another triangular space between the humerus (laterally) and the long head of the triceps (medially).
2. Note that two very important structures i.e., the radial nerve and the profunda brachii artery pass through this space to reach the back of the arm.

NERVES OF SCAPULAR REGION

1. The nerves of the scapular region are the upper and lower subscapular nerves, the suprascapular nerve and the axillary nerve.
2. The ***upper subscapular nerve*** arises from the posterior cord and supplies the subscapularis.
3. The ***lower subscapular nerve*** arises from the posterior cord. It supplies the teres major and also gives a branch to the subscapularis.

JAYPEE BROTHERS

The Suprascapular Nerve

1. The suprascapular nerve runs laterally and backwards over the shoulder (4.22). As it does so, it lies de trapezius.
2. Reaching the upper border of the scapula it passes backwards through the suprascapular notch (b transverse scapular ligament) to enter the supraspinous fossa and supplies the supraspinatus.
3. The nerve then enters the infraspinous fossa where it ends by supplying the infraspinatus. The nerve a branches to the shoulder joint ('a' in 4.22) and to the acromioclavicular joint ('b' in 4.22).

The Axillary Nerve

1. The axillary nerve (4.23) supplies the deltoid and the teres minor. It is also called the circumflex humer and is a branch of the posterior cord of the brachial plexus.
2. At its origin it lies behind the axillary artery. It descends over the subscapularis, and reaching its lower passes backwards through the quadrangular space described above, in company with the posterior ci humeral artery.
3. As it passes through the space it is closely related to the capsule of the shoulder joint which lies above
4. The nerve ends by dividing into an anterior and a posterior branch.
   a. The ***anterior branch*** passes laterally and forwards round the surgical neck of the humerus and ends plying the deltoid. Some ramifications pass through the deltoid to reach the skin.
   b. The ***posterior branch*** supplies the posterior part of the deltoid and also the teres minor.
   c. Its terminal part becomes the ***upper lateral cutaneous nerve of the arm***. This nerve supplies the skin lower part of the deltoid muscle. (The skin over the upper part of the deltoid is supplied by the la praclavicular nerves). The axillary nerve also gives a branch to the shoulder joint ('c' in 4.23).



CLINICAL CORRELATION

The axillary nerve can be injured in a fracture through the surgical neck of the humerus. The deltoid is pa (See below).

ARTERIES OF SCAPULAR REGION

1. In the back and scapular region we see some arteries that begin in the neck as (direct or indirect) bra the subclavian artery.
2. Like the axillary artery, the subclavian artery is divided into first, second and third parts (by a muscle c scalenus anterior).
3. A short artery called the ***thyrocervical trunk*** arises from the junction of the first and second parts of the vian artery (4.24A and B). The thyrocervical trunk divides into three branches as follows:
   a. The ***inferior thyroid artery*** is distributed only within the neck. It supplies the thyroid gland.
   b. The ***suprascapular artery*** descends into the scapular region and is described below.
   c. The distribution of the third branch of the thyrocervical trunk is variable, and depending on this, th is given alternative names. Both variants described below are almost equally common.
   d. In the first variant the third branch is called the ***transverse cervical artery***. It divides into a ***superficia*** (which is confined to the neck), and a ***deep branch*** which descends into the back in company with th scapular nerve.
   e. In the second variant the third branch of the subclavian artery is called the ***superficial cervical artery***
      i. This artery supplies the same territory as the superficial branch of the transverse cervical artery
      ii. When this is the case we find that the dorsal scapular nerve is accompanied by an artery arising from the third part of the subclavian artery: this is the ***dorsal scapular artery***.

JAYPEE BROTHERS

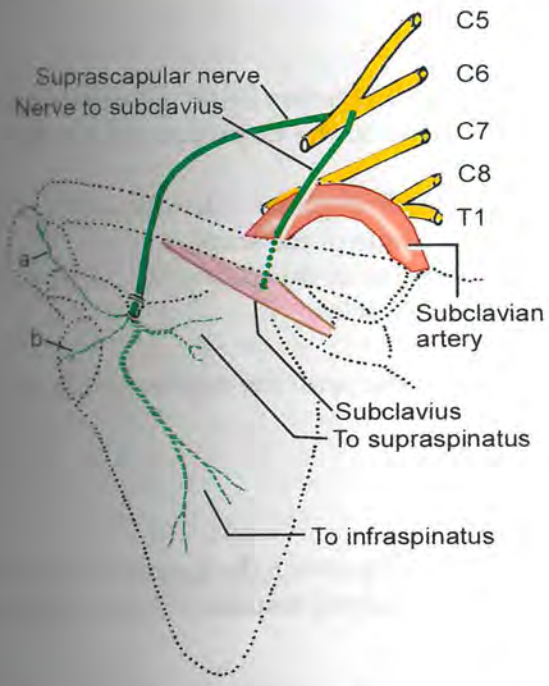

4.22: Scheme to show the course of the suprascapular nerve, and the nerve to the subclavius

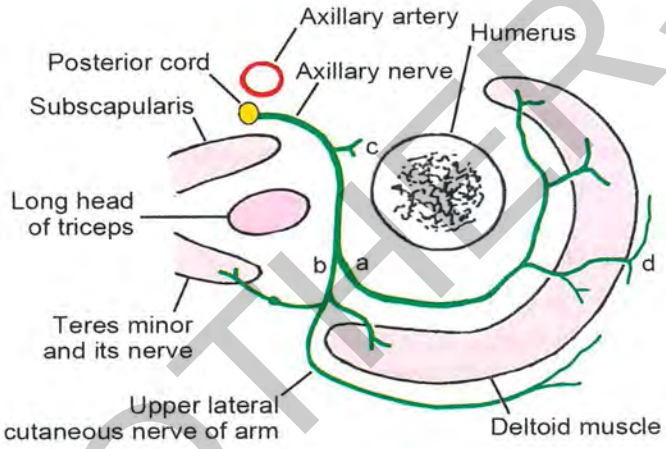

4.23: Scheme to show the course and distribution of the axillary nerve. a: anterior branch; b: posterior branch; c: branch to shoulder joint; d: cutaneous twig from anterior branch

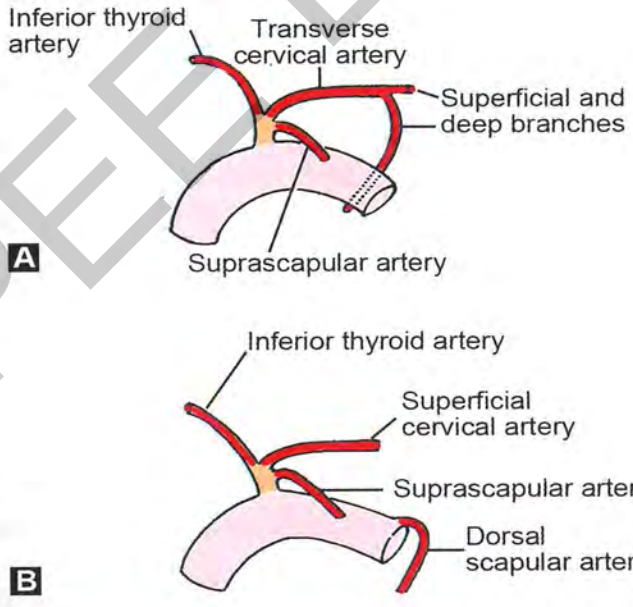

4.24A and B: Two patterns of branching of the thyrocervical trunk

JAYPEE BROTHERS

The Transverse Cervical Artery

This artery divides into superficial and deep branches.

1. The ***superficial branch*** of the artery (or, alternatively, the superficial cervical artery) runs laterally acr posterior triangle of the neck to reach the trapezius. It then ascends deep to the trapezius, supplying neighbouring structures.
2. The ***deep branch*** of the transverse cervical artery (or the dorsal scapular artery) passes laterally and back in the lower part of the posterior triangle of the neck to reach the upper angle of the scapula.
   a. It then runs along the medial border of this bone up to the inferior angle: in this part of its course it first deep to the levator scapulae, and then deep to the rhomboideus muscles.
   b. It supplies these muscles and the trapezius.
   c. It gives branches that pass ventral or dorsal to the scapula to anastomose with the suprascapular an scapular arteries.

The Suprascapular Artery

This artery is seen in both the neck and the upper limb.

1. From its origin it runs laterally behind the clavicle. It then passes backwards to reach the superior border scapula: here it passes above the transverse scapular ligament and enters the supraspinous fossa. After some branches to the supraspinatus it passes into the infraspinous fossa.
2. The muscles supplied by this artery are:
   a. Supraspinatus
   b. Infraspinatus
   c. Sternocleidomastoid
   d. Subclavius.
   e. A branch enters the subscapular fossa and supplies the subscapularis.
3. The suprascapular artery gives off cutaneous branches to the upper part of the chest (suprasternal branc to the acromial region (acromial branch).
4. Articular branches supply the shoulder joint and the acromioclavicular joint.
5. The artery also establishes several anastomoses as described below.

Anastomosis around the Scapula

1. On the back of the body of the scapula the suprascapular artery anastomoses with the deep branch of the verse cervical artery and with the circumflex scapular branch of the subscapular artery (4.25).
2. On the ventral surface of the body of the scapula, branches of the suprascapular artery anastomose w subscapular artery and with the deep branch of the transverse cervical artery.
3. Over the acromion branches of the suprascapular artery anastomose with the thoracoacromial and p circumflex humeral arteries.



CLINICAL CORRELATION

1. It may be noted that the anastomoses around the scapula described above connect the first part of the vian artery to the third part of the axillary artery.
2. They serve as collateral channels in case of obstruction to the arterial trunk between these levels.
3. The collaterals take time to become effective and are useful in gradual obstruction of the artery.
4. If the axillary artery has to be ligated the collateral circulation may be inadequate.

JAYPEE BROTHERS

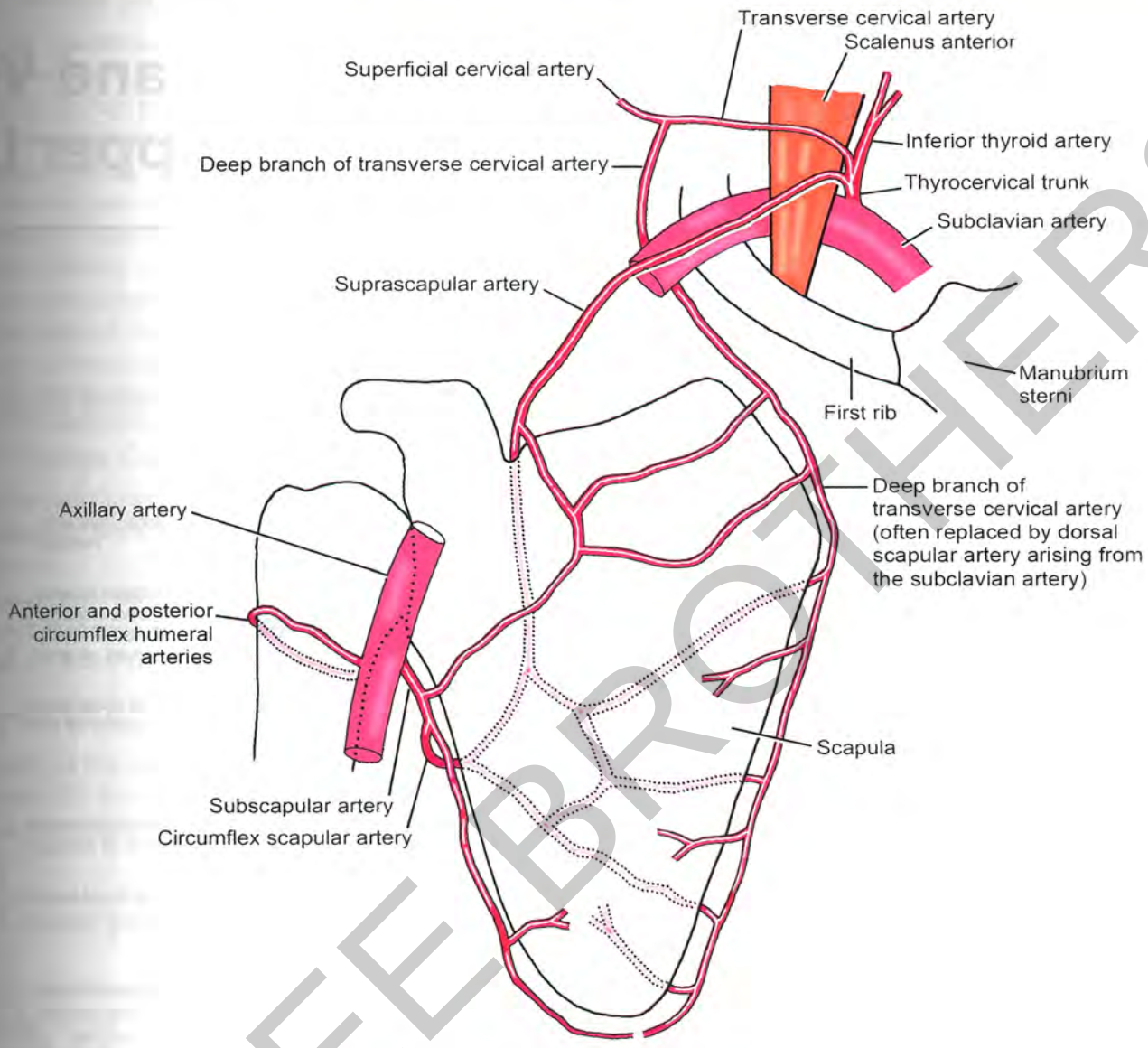

4.25: Anastomoses around the scapula

JAYPEE BROTHERS

for detailed information on anatomy books, visit our website www.jaypeebrothers.com, for detailed information on anatomy books, visit ou

Inderbir Singh's *Textbook of*
Anatomy
for DENTAL Students

Salient Features

- Important topics for dental students are simplified for understanding the concepts in anatomy.
- Simple language and numerous high quality and hand drawn simple illustrations for easy reproducibility.
- It is a standard textbook in a single volume to justify the needs of dental students.
- On-line content is provided for quick revision of certain important topics with additional content.

V Subhadra Devi Ms (Anatomy) is Professor of Anatomy, Apollo Institute of Medical Sciences and Research (AIMSR), Chittoor, Andhra Pradesh, India. She did her graduation and postgraduation from SV Medical College, Tirupati, Andhra Pardesh. She worked as teaching faculty in various capacities at SV Medical College; Osmania Medical College, Hyderabad, Telangana, India, and Sri Padmavathi Medical College for Women (SPMCW), SVIMS University, Tirupati, Andhra Pradesh, India.

She has 40 plus years of teaching and research experience; her field of interest is Developmental Anatomy and Histology. She has to her credit more than 70 publications in both national and international journals. She has authored the Textbooks of Histology and General Anatomy and the 3 volumes of Inderbir Singh's Gross Anatomy and Inderbir Singh's Human Embryology, 11th edition Textbooks.

She is a recipient of Combined Andhra Pradesh State Meritorious Teacher's award. National resource person in Medical Education Technology, Reviewer of Swayam Project of MHRD of Government of India.

She is a life member of Anatomical Society of India (ASI), National Clinical Anatomists Association (NCA), Regional Society of Anatomists of Andhra Pradesh and Telangana States (RSA), Basic Sciences Association, Indian Geriatrics Society and Indian Society of the Human Genetics. She is also Honorary Editor-in-Chief for International Journal of Anatomy and Research, and editorial board member in various national and international Journals.

Printed in India

Available at all medical bookstores
or buy online at www.jaypeebrothers.com

JAYPEE BROTHERS
Medical Publishers (P) Ltd.
EMCA House, 23/23-B, Ansari Road,
Daryaganj, New Delhi - 110 002, INDIA
www.jaypeebrothers.com

Join us on facebook.com/JaypeeMedicalPublishers

Shelving Recommendations
ANATOMY & DENTISTRY

ISBN 978-93-90595-49-5

9 789390 595495