s.com, for detailed information on radiology books, visit our website www.jaypeebrothers.com, for detailed information on radiology books

Get Full Access with added features at emedicine360.com



Volume 4

m, for detailed information on radiology books, visit our website www.jaypeebrothers.com, for detailed information on radiology books

Get Full Access with added features at emedicine360.com



Volume 3

AIIMS-MAMC-PGI's
Comprehensive Textbook of
DIAGNOSTIC

site www.jaypeebrothers.com, for detailed information on radiology books

medicine360.com



Volume 2

.com, for detailed information on radiology books, visit our website www.jaypeebrothers.com, for detailed information on radiology books

Get Full Access with added features at emedicine360.com



Volume 1

AIIMS-MAMC-PGI's
Comprehensive Textbook of
DIAGNOSTIC
RADIOLOGY

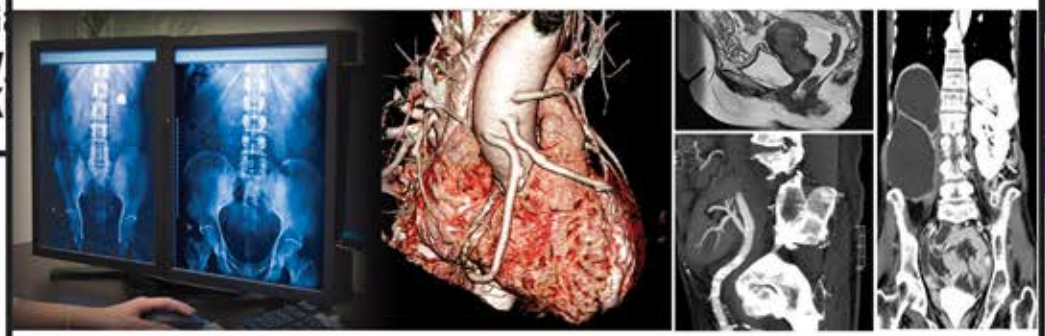

- Genitourinary Imaging
- Advances in Imaging Technology

Arun Kumar Gupta
Anju Garg
Manavjit Singh Sandhu

3rd Edition

JAYPEE

AIIMS-MAMC-PGI's

Comprehensive Textbook of DIAGNOSTIC RADIOLOGY

Third Edition

VOLUME 1

- Genitourinary Imaging
- Advances in Imaging Technology

Editors

Arun Kumar Gupta MD FAMS
Professor and Head
Department of Radiodiagnosis
All India Institute of Medical Sciences
New Delhi, India

Anju Garg MD
Director Professor and Head
Department of Radiodiagnosis
Maulana Azad Medical College
New Delhi, India

Manavjit Singh Sandhu MD FICR
CCST (UK)
Professor and Head
Department of Radiodiagnosis
Postgraduate Institute of
Medical Education and Research
Chandigarh, India

JAYPEE BROTHERS MEDICAL PUBLISHERS
The Health Sciences Publisher
New Delhi | London

JAYPEE BROTHERS

ASSOCIATE EDITORS

VOLUME 1

Section 1: Genitourinary Imaging

Gaurav Shanker Pradhan DMRD DNB
Director Professor
Department of Radiodiagnosis
Maulana Azad Medical College
New Delhi, India

Alpana Manchanda MD
Director Professor
Department of Radiodiagnosis
Maulana Azad Medical College
New Delhi, India

Sapna Singh MD DNB MNAMS
Professor
Department of Radiodiagnosis
Maulana Azad Medical College
New Delhi, India

Section 2: Advances in Imaging Technology

Sanjay Sharma MD DNB MNAMS FRCR FICR
Professor
Department of Radiodiagnosis
(RP Center division)
All India Institute of Medical Sciences
New Delhi, India

Atin Kumar MD DNB MNAMS FICR
Professor
Department of Radiodiagnosis
(Trauma Centre Division)
All India Institute of Medical Sciences
New Delhi, India

Shivanand Gamanagatti MD MNAMS FICR
Professor
Department of Radiodiagnosis
(Trauma Centre Division)
All India Institute of Medical Sciences
New Delhi, India

VOLUME 2

Section 3: Paediatric Imaging

Ashu Seith Bhalla MD MAMS FICR
Professor
Department of Radiodiagnosis
All India Institute of Medical Sciences
New Delhi, India

Manisha Jana MD DNB FRCR
Additional Professor
Department of Radiodiagnosis
All India Institute of Medical Sciences
New Delhi, India

Devasenathipathy Kandasamy MD DNB FRCR
Additional Professor
Department of Radiodiagnosis
All India Institute of Medical Sciences
New Delhi, India

Priyanka Naranje MD DNB MNAMS
Associate Professor
Department of Radiodiagnosis
All India Institute of Medical Sciences
New Delhi, India

Section 4: Gastrointestinal and Hepatobiliary Imaging

Deep Narayan Srivastava MD MBA FAMS FICR
Professor
Department of Radiodiagnosis
All India Institute of Medical Sciences
New Delhi, India

Raju Sharma MD MAMS FICR
Professor
Department of Radiodiagnosis
All India Institute of Medical Sciences
New Delhi, India

JAYPEE BROTHERS

VOLUME 3

Section 5: Chest and Cardiovascular Imaging

Sanjiv Sharma MD
Professor and Head
Department of Cardiovascular Radiology and Endovascular Interventions
CN Centre
All India Institute of Medical Sciences
New Delhi, India

Rashmi Dixit MD
Director Professor
Department of Radiodiagnosis
Maulana Azad Medical College
New Delhi, India

Section 6: Musculoskeletal and Breast Imaging

Mahesh Prakash MD MAMS FIACM FICR
Professor
Department of Radiodiagnosis
Postgraduate Institute of Medical Education and Research
Chandigarh, India

Anindita Sinha MD MAMS
Additional Professor
Department of Radiodiagnosis
Postgraduate Institute of Medical Education and Research
Chandigarh, India

VOLUME 4

Section 7: Neuroradiology Including Head and Neck Imaging

Paramjeet Singh MD FICR
Professor
Department of Radiodiagnosis
Postgraduate Institute of Medical Education and Research
Chandigarh, India

Shailesh B Gaikwad MD FNAMS CCST
Professor and Head
Department of Neuroimaging and Interventional Neuroradiology (CN Centre)
All India Institute of Medical Sciences
New Delhi, India

Vivek Gupta MD DM
Former Professor
Department of Radiodiagnosis
Postgraduate Institute of Medical Education and Research
Chandigarh, India

Ajay Garg MD
Professor
Department of Neuroimaging and Interventional Neuroradiology (CN Centre)
All India Institute of Medical Sciences
New Delhi, India

JAYPEE BROTHERS

CONTRIBUTORS

Ajay Garg MD (Radiodiagnosis) Eur Dip in Neuroradiology (EDiNR) Eur Dip in Pediatric Neuroradiology (EDiPNR)
Professor, Department of Neuroimaging and Interventional Neuroradiology
CN Centre
All India Institute of Medical Sciences
New Delhi, India

Ajay Gulati MD MAMS
Additional Professor
Department of Radiodiagnosis
Postgraduate Institute of Medical Education and Research, Chandigarh, India

Ajay Kumar MD
Professor
Department of Radiodiagnosis
Postgraduate Institute of Medical Education and Research, Chandigarh, India

Akshay Kumar Saxena MD DNB FICR
Professor
Department of Radiodiagnosis
Postgraduate Institute of Medical Education and Research, Chandigarh, India

Alpana Manchanda MD
Director Professor
Department of Radiodiagnosis
Maulana Azad Medical College
New Delhi, India

Anil Kumar Pandey MSc PhD
Associate Professor (Medical Physics)
Department of Nuclear Medicine and PET
All India Institute of Medical Sciences
New Delhi, India

Anindita Sinha MD MAMS
Additional Professor
Department of Radiodiagnosis
Postgraduate Institute of Medical Education and Research
Chandigarh, India

Anjali Prakash DMRD DNB MNAMS
Director Professor
Department of Radiodiagnosis
Maulana Azad Medical College
New Delhi, India

Anju Garg MD
Director Professor and Head
Department of Radiodiagnosis
Maulana Azad Medical College
New Delhi, India

Ankur Goyal MD DNB MNAMS
Associate Professor
Department of Radiodiagnosis
All India Institute of Medical Sciences
New Delhi, India

Anmol Bhatia MD FPGI (Paediatric Radiology)
Assistant Professor
Department of Radiodiagnosis and Imaging
Postgraduate Institute of Medical Education and Research
Chandigarh, India

Anuj Prabhakar DNB DM (Neuroradiology)
Assistant Professor
Postgraduate Institute of Medical Education and Research
Chandigarh, India

Anupam Lal MD
Professor
Department of Radiodiagnosis
Postgraduate Institute of Medical Education and Research
Chandigarh, India

Arun Kumar Gupta MD FAMS
Professor and Head
Department of Radiodiagnosis
All India Institute of Medical Sciences
New Delhi, India

Ashu Seith Bhalla MD MAMS FICR
Professor
Department of Radiodiagnosis
All India Institute of Medical Sciences
New Delhi, India

Atin Kumar MD DNB MNAMS FICR
Professor
Department of Radiodiagnosis
(Trauma Center Division)
All India Institute of Medical Sciences
New Delhi, India

Chandan J Das MD DNB MAMS FICR FRCP
Additional Professor
Department of Radiodiagnosis
All India Institute of Medical Sciences
New Delhi, India

Chandrashekhara SH MD DNB MNAMS
Additional Professor
Department of Radiodiagnosis
Dr BRA Institute—Rotary Cancer Hospital
All India Institute of Medical Sciences
New Delhi, India

Chirag Kamal Ahuja MD DM (Neuroradiology)
Associate Professor
Department of Radiodiagnosis and Imaging
Postgraduate Institute of Medical Education and Research
Chandigarh, India

Deep Narayan Srivastava MD MBA FAMS FICR
Professor
Department of Radiodiagnosis
All India Institute of Medical Sciences
New Delhi, India

Devasenathipathy Kandasamy MD DNB FRCR
Additional Professor
Department of Radiodiagnosis
All India Institute of Medical Sciences
New Delhi, India

Ekta Dhamija MD
Associate Professor
Department of Radiodiagnosis
Dr BRA Institute—Rotary Cancer Hospital
All India Institute of Medical Sciences
New Delhi, India

JAYPEE BROTHERS

Gaurav Shanker Pradhan DMRD DNB
Director Professor
Department of Radiodiagnosis
Maulana Azad Medical College
New Delhi, India

Gita Devi MD DNB
Assistant Professor
Department of Radiodiagnosis
Postgraduate Institute of Medical Education and Research
Chandigarh, India

Gurpreet Singh Gulati MD
Former Professor
Department of Cardiac Radiology
Cardio-Thoracic Sciences Centre
All India Institute of Medical Sciences
New Delhi, India

Harish Bhujade MD FVIR
Assistant Professor
Department of Radiodiagnosis
Postgraduate Institute of Medical Education and Research
Chandigarh, India

Jyoti Kumar MD DNB MNAMS FICR
Professor
Department of Radiodiagnosis
Maulana Azad Medical College
New Delhi, India

Kartik Ganga MD
Fellow
Department of Cardiovascular Radiology and Endovascular Interventions
All India Institute of Medical Sciences
New Delhi, India

Kirti Gupta MD, Neuropathology
Fellowship (St Jude, USA)
Professor
Department of Histopathology
Postgraduate Institute of Medical Education and Research
Chandigarh, India

Kumble S Madhusudhan MD FRCR MAMS
Additional Professor
Department of Radiodiagnosis
All India Institute of Medical Sciences
New Delhi, India

Kushaljit Singh Sodhi MD PhD MAMS FICR
Professor
Department of Radiodiagnosis
Postgraduate Institute of Medical Education and Research
Chandigarh, India

Madhavi Tripathi MD DNB (Nuclear Medicine)
Additional Professor
Department of Nuclear Medicine and PET
All India Institute of Medical Sciences
New Delhi, India

Madhusudhan KS MD MAMS FRCR
Additional Professor
Department of Radiodiagnosis
All India Institute of Medical Sciences
New Delhi, India

Mahesh Prakash MD MAMS FIACM FICR
Professor
Department of Radiodiagnosis
Postgraduate Institute of Medical Education and Research
Chandigarh, India

Manavjit Singh Sandhu MD FICR CCST (UK)
Professor and Head
Department of Radiodiagnosis
Postgraduate Institute of Medical Education and Research
Chandigarh, India

Mandeep Garg MD FRCR
Professor
Department of Radiodiagnosis
Postgraduate Institute of Medical Education and Research
Chandigarh, India

Mandeep Kang MD MAMS FICR
Professor
Department of Radiodiagnosis
Postgraduate Institute of Medical Education and Research
Chandigarh, India

Manisha Jana MD DNB FRCR
Additional Professor
Department of Radiodiagnosis
All India Institute of Medical Sciences
New Delhi, India

Manish Modi MD DM
Professor
Department of Neurology
Postgraduate Institute of Medical Education and Research
Chandigarh, India

Manphool Singhal MD DNB MAMS FICR (India) FSCCT (USA) CMR-fellowship (London) CMR-Certification (SCMR USA and ESCVI France)
Additional Professor
Department of Radiodiagnosis
Postgraduate Institute of Medical Education and Research
Chandigarh, India

Mukesh Kumar Yadav (MD Radiodiagnosis)
Formerly Associate Professor
PGIMER, Chandigarh
Associate Professor
Department of Radiodiagnosis
All India Institute of Medical Sciences (IRCH)
New Delhi, India

Naveen Kalra MD FICR MAMS
Professor
Department of Radiodiagnosis
Postgraduate Institute of Medical Education and Research
Chandigarh, India

Nidhi Prabhakar MD DNB
Senior Research Associate
Department of Radiodiagnosis
Postgraduate Institute of Medical Education and Research
Chandigarh, India

Niraj N Pandey DM
Assistant Professor
Department of Cardiovascular Radiology and Endovascular Interventions
CN Centre
All India Institute of Medical Sciences
New Delhi, India

Niranjan Khandelwal MD Dip NBE FICR FAMS
Former Head
Department of Radiodiagnosis
Postgraduate Institute of Medical Education and Research
Chandigarh, India

JAYPEE BROTHERS

Pankaj Gupta MD DNB
Assistant Professor
Department of Radiodiagnosis and Imaging
Postgraduate Institute of Medical Education and Research
Chandigarh, India

Paramjeet Singh MD FICR
Professor
Department of Radiodiagnosis
Postgraduate Institute of Medical Education and Research
Chandigarh, India

Pratik Kumar PhD (AIIMS) Dip RP (BARC)
Professor, Medical Physics Unit
BRA Institute Rotary Cancer Hospital
AIIMS, New Delhi, India

Priya Jagia MD DNB
Professor
Department of Cardiovascular Radiology and Endovascular Interventions
All India Institute of Medical Sciences
New Delhi, India

Priyanka Naranje MD DNB MNAMS
Associate Professor
Department of Radiodiagnosis
All India Institute of Medical Sciences
New Delhi, India

Punit Sharma MD
Former Senior Resident
Department of Nuclear Medicine
All India Institute of Medical Sciences
New Delhi, India

Radhika Batra MD DNB
Associate Professor
Department of Radiodiagnosis
Maulana Azad Medical College
New Delhi, India

Rajat Jain MD DNB FRCR FICR MNAMS
Assistant Professor
Department of Radiodiagnosis
Maulana Azad Medical College
New Delhi, India

Raju Sharma MD MAMS FICR
Professor
Department of Radiodiagnosis
All India Institute of Medical Sciences
New Delhi, India

Rakesh Kumar DRM DNB PhD
Professor and Head
Diagnostic Nuclear Medicine Division
Department of Nuclear Medicine and PET
All India Institute of Medical Sciences
New Delhi, India

Rakesh Kumar Vasishta MD FRCPath
Former Professor and Head
Department of Histopathology
Postgraduate Institute of Medical Education and Research
Chandigarh, India

Rashmi Dixit MD
Director Professor
Department of Radiodiagnosis
Maulana Azad Medical College
New Delhi, India

Sameer Vyas MD DM MAMS (Neuroradiology)
Additional Professor
Department of Radiodiagnosis
Postgraduate Institute of Medical Education and Research
Chandigarh, India

Sanjay Sharma MD DNB MNAMS FRCR FICR
Professor
Department of Radiodiagnosis
(Division at Rajendra Prasad Center for Ophthalmic Sciences)
All India Institute of Medical Sciences
New Delhi, India

Sanjeev Kumar MD
Associate Professor
Department of Cardiovascular Radiology and Endovascular Interventions
All India Institute of Medical Sciences
New Delhi, India

Sanjiv Sharma MD
Professor and Head
Department of Cardiovascular Radiology and Endovascular Interventions
CN Centre
All India Institute of Medical Sciences
New Delhi, India

Sapna Singh MD DNB MNAMS
Professor
Department of Radiodiagnosis
Maulana Azad Medical College
New Delhi, India

Satyam DNB MNAMS
Specialist
Department of Radiodiagnosis
Lok Nayak Hospital and Associated
Maulana Azad Medical College
New Delhi, India

Shailesh B Gaikwad MD FNAMS CCST
Professor and Head
Department of Neuroimaging and Interventional Neuroradiology
CN Centre
All India Institute of Medical Sciences
New Delhi, India

Shamim Ahmed Shamim MD (Nuclear Medicine)
Associate Professor
Department of Nuclear Medicine
All India Institute of Medical Sciences
New Delhi, India

Shashi Bala Paul PhD MAMS
Senior Scientist
Department of Radiodiagnosis
All India Institute of Medical Sciences
New Delhi, India

Shivanand Gamanagatti MD MNAMS FICR
Professor
Department of Radiodiagnosis
(Trauma Center Division)
All India Institute of Medical Sciences
New Delhi, India

Smita Manchanda MD DNB MNAMS
Associate Professor
Department of Radiodiagnosis
All India Institute of Medical Sciences
New Delhi, India

Smriti Hari MD MAMS
Professor
Department of Radiodiagnosis
All India Institute of Medical Sciences
New Delhi, India

Sreedhara BC MD FVIR
Assistant Professor
Department of Radiodiagnosis
Postgraduate Institute of Medical Education and Research
Chandigarh, India

JAYPEE BROTHERS

Subrat Kumar Acharya DM FNASc
FASc FNA JC Bose Fellow
Former Professor and Head
Department of Gastroenterology
All India Institute of Medical Sciences
New Delhi, India

Sudesh Prabhakar MD DM
Former Professor and Head
Department of Neurology
Postgraduate Institute of Medical
Education and Research
Chandigarh, India

Sudha Suri MD
Emeritus Professor
Department of Radiodiagnosis
Postgraduate Institute of Medical
Education and Research
Chandigarh, India

Surabhi Vyas MD DNB MNAMS
Additional Professor
Department of Radiodiagnosis
All India Institute of Medical Sciences
New Delhi, India

Swati Gupta MD DNB FRCR
Associate Professor
Department of Radiodiagnosis
Maulana Azad Medical College
New Delhi, India

Tulika Singh MD
Additional Professor
Department of Radiodiagnosis
Postgraduate Institute of Medical
Education and Research
Chandigarh, India

Ujjwal Gorsi (MD Radiodiagnosis)
Associate Professor
Department of Radiodiagnosis
Postgraduate Institute of Medical
Education and Research
Chandigarh, India

Uma Debi MD
Associate Professor
Department of Radiodiagnosis
Postgraduate Institute of Medical
Education and Research
Chandigarh, India

Veenu Singla MD
Professor
Department of Radiodiagnosis
Postgraduate Institute of Medical
Education and Research
Chandigarh, India

Vikas Bhatia MD DNB
DM (Neuroradiology)
Assistant Professor
Department of Radiodiagnosis
Postgraduate Institute of Medical
Education and Research
Chandigarh, India

Vineeta Ojha MD DNB
DM Senior Resident
Department of Cardiovascular Radiology
and Endovascular Interventions
All India Institute of Medical Sciences
New Delhi, India

Virendra Jain MD FRCR
Former Senior Resident
Department of Radiodiagnosis
Maulana Azad Medical College
New Delhi, India

Vivek Gupta MD DM
Former Professor
Department of Radiodiagnosis
Postgraduate Institute of Medical
Education and Research
Chandigarh, India

JAYPEE BROTHERS

CONTENTS

VOLUME 1

Section 1: Genitourinary Imaging

1. **Imaging Techniques and Radiological Anatomy of the Upper Urinary Tract** 3
   Sapna Singh, Jyoti Kumar, Anjali Prakash
2. **Current Status of Nuclear Medicine in Urinary Tract Imaging** 34
   Rakesh Kumar, Madhavi Tripathi
3. **Renal Calculus Disease and Obstructive Uropathy** 51
   Uma Debi, Mahesh Prakash, Mandeep Kang
4. **Renal Parenchymal Disease** 67
   Sreedhara BC, Anupam Lal, Anindita Sinha
5. **Nontubercular Infections of the Urinary Tract** 84
   Ujjwal Gorsi, Naveen Kalra, Ajay Kumar
6. **Tubercular Infection of the Urinary Tract** 95
   Ashu Seith Bhalla, Priyanka Naranje, Arun Kumar Gupta
7. **Renal Cystic Diseases** 110
   Jyoti Kumar, Anjali Prakash, Sapna Singh
8. **Renal Neoplasms** 124
   Anjali Prakash, Gaurav Shanker Pradhan, Rashmi Dixit
9. **Renovascular Hypertension** 157
   Sanjeev Kumar, Vineeta Ojha, Sanjiv Sharma
10. **Imaging of Renal Transplant** 177
    Ajay Gulati, Manavjit Singh Sandhu, Tulika Singh
11. **Imaging Techniques and Radiological Anatomy of Lower Urinary Tract** 189
    Gaurav Shanker Pradhan, Satyam, Jyoti Kumar
12. **Urinary Bladder and Urethral Diseases** 199
    Anupam Lal, Paramjeet Singh, Harish Bhujade
13. **Imaging Techniques and Radiological Anatomy of Female Genital Tract** 216
    Swati Gupta, Sapna Singh, Anju Garg, Satyam
14. **Benign Adnexal Disease** 233
    Anju Garg, Alpana Manchanda, Radhika Batra
15. **Malignant Ovarian and Tubal Disease** 276
    Smita Manchanda, Surabhi Vyas, Manisha Jana

JAYPEE BROTHERS

16. **Benign Diseases of the Uterus and Vagina** 295
Rashmi Dixit, Anju Garg, Alpana Manchanda

17. **Malignant Diseases of the Uterus and Vagina** 318
Alpana Manchanda, Anju Garg, Gaurav Shanker Pradhan

18. **Female Infertility** 346
Radhika Batra, Rashmi Dixit, Swati Gupta

19. **Imaging Techniques and Radiological Anatomy of the Male Genital Tract** 366
Anmol Bhatia, Paramjeet Singh, Sameer Vyas

20. **Disorders of the Prostate Gland** 373
Ujjwal Gorsi, Paramjeet Singh, Anupam Lal

21. **Scrotal Diseases** 387
Anupam Lal, Manphool Singhal, Sreedhara BC

22. **Male Infertility and Erectile Dysfunction** 402
Deep Narayan Srivastava, Chandan J Das

23. **Imaging of the Adrenal Gland** 415
Devasenathipathy Kandasamy, Raju Sharma, Arun Kumar Gupta

24. **The Retroperitoneum** 437
Smriti Hari, Sanjay Sharma, Ekta Dhamija, Ankur Goyal

25. **Urinary Tract Trauma** 455
Atin Kumar, Shivanand Gamanagatti

26. **Nonvascular Interventions in the Urinary Tract** 470
Mandeep Kang, Naveen Kalra, Ujjwal Gorsi, Sreedhara BC

27. **Vascular Interventions in the Genitourinary Tract** 483
Shivanand Gamanagatti, Ankur Goyal, Deep Narayan Srivastava

Section 2: Advances in Imaging Technology

28. **Ultrasound Instrumentation: Practical Applications** 501
Ujjwal Gorsi, Anmol Bhatia, Kushaljit Singh Sodhi, Akshay Kumar Saxena

29. **Image Optimization in Ultrasound** 514
Rashmi Dixit, Anju Garg, Alpana Manchanda, Anjali Prakash

30. **Ultrasound Elastography: Principles and Application** 535
Veenu Singla, Tulika Singh, Anindita Sinha

31. **Computed Tomography Hardware including Dual Energy Computed Tomography: An Update** 554
Smita Manchanda, Ashu Seith Bhalla, Priyanka Naranje

32. **Advanced Computed Tomography Applications and Software** 579
Mukesh Kumar Yadav, Priyanka Naranje, Ekta Dhamija

33. **Magnetic Resonance Instrumentation and MRI Safety Issues: An Update** 597
Anjali Prakash, Jyoti Kumar, Sapna Singh

34. **Image Optimization in Magnetic Resonance Imaging** 623
Jyoti Kumar, Anjali Prakash, Rashmi Dixit, Gaurav Shanker Pradhan

JAYPEE BROTHERS

35. **Diffusion-weighted Magnetic Resonance Imaging** 641
Devasenathipathy Kandasamy, Raju Sharma

36. **Perfusion MRI** 657
Sameer Vyas, Pankaj Gupta, Paramjeet Singh, Niranjan Khandelwal

37. **Magnetic Resonance Angiography** 677
Ajay Kumar, Sameer Vyas, Sreedhara BC, Naveen Kalra

38. **Magnetic Resonance Imaging Pulse Sequences** 696
Vikas Bhatia, Manphool Singhal, Mahesh Prakash

39. **Digital Radiography: An Update** 709
Alpana Manchanda, Rashmi Dixit, Sapna Singh, Radhika Batra

40. **Digital Mammography** 726
Smriti Hari, Surabhi Vyas, Chandrashekhara SH

41. **Fluoroscopy and Digital Subtraction Angiography** 732
Deep Narayan Srivastava, Kumble S Madhusudhan

42. **Tools and Drugs in Interventional Radiology** 751
Atin Kumar, Chandan J Das

43. **Magnetic Resonance Contrast Media** 765
Anju Garg, Radhika Batra, Alpana Manchanda

44. **Ultrasound Contrast Agents** 778
Shashi Bala Paul, Manisha Jana

45. **Iodinated Contrast Media: An Update (To Include Reactions and Management)** 800
Gaurav Shanker Pradhan, Swati Gupta, Jyoti Kumar, Anju Garg

46. **Radiology Information System and Picture Archiving and Communication System** 811
Devasenathipathy Kandasamy, Shivanand Gamanagatti, Arun Kumar Gupta

47. **Evidence-based Radiology and a Primer on Biostatistics** 816
Sanjay Sharma, Ankur Goyal, Manisha Jana

48. **Radiation Hazards and Radiation Units** 826
Pratik Kumar, Anil Kumar Pandey

49. **Radiation Protection** 839
Sapna Singh, Gaurav Shanker Pradhan, Swati Gupta

50. **Planning Modern Imaging Department with Regulatory Requirements in Radiology Practice** 852
Ajay Gulati, Nidhi Prabhakar, Uma Debi

51. **Recent Advances in PET/CT and PET/MR** 867
Rakesh Kumar, Madhavi Tripathi

52. **Ethical and Legal Issues in Radiology** 887
Chirag Kamal Ahuja, Mandeep Kang, Manavjit Singh Sandhu

53. **Basics of Radiomics, Texture Analysis and Radiogenomics** 895
Chandan J Das, Devasenathipathy Kandasamy, Ankur Goyal, Raju Sharma

54. **Artificial Intelligence in Radiology** 900
Chirag Kamal Ahuja, Kushaljit Singh Sodhi, Mandeep Garg, Mandeep Kang

55. **Structured Reporting in Radiology** 908
Ashu Seith Bhalla, Smita Manchanda, Manisha Jana

JAYPEE BROTHERS

VOLUME 2

Section 3: Paediatric Imaging

56. **Technical Considerations in Pediatric Imaging** 917
Surabhi Vyas, Ashu Seith Bhalla, Arun Kumar Gupta

57. **Recent Advances in Pediatric Radiology** 932
Akshay Kumar Saxena, Kushaljit Singh Sodhi, Anmol Bhatia

58. **Frontiers in Research: Genomics, Radiogenomics, Texture Analysis, Safety of Gadolinium-based Contrast, etc.** 942
Devasenathipathy Kandasamy, Atin Kumar, Manisha Jana, Raju Sharma

59. **Vascular Interventions in Children** 949
Sanjeev Kumar, Niraj N Pandey, Sanjiv Sharma

60. **Nonvascular Interventions in Children** 963
Priyanka Naranje, Devasenathipathy Kandasamy, Shivanand Gamanagatti

61. **Imaging of Pediatric Trauma** 972
Shivanand Gamanagatti, Atin Kumar

62. **Neonatal Respiratory Distress** 991
Akshay Kumar Saxena, Kushaljit Singh Sodhi, Anmol Bhatia

63. **Childhood Pulmonary Infections** 1002
Jyoti Kumar, Anjali Prakash, Alpana Manchanda

64. **Imaging of Pediatric Chest Masses** 1025
Devasenathipathy Kandasamy, Smita Manchanda, Arun Kumar Gupta

65. **Pediatric Airway** 1041
Ashu Seith Bhalla, Surabhi Vyas, Priyanka Naranje

66. **Pediatric Interstitial Lung Diseases** 1066
Priyanka Naranje, Ashu Seith Bhalla, Manisha Jana

67. **Developmental Anomalies of Gastrointestinal Tract** 1081
Alpana Manchanda, Anju Garg, Radhika Batra

68. **Imaging of Anorectal Anomalies** 1113
Arun Kumar Gupta, Manisha Jana, Devasenathipathy Kandasamy

69. **Gastrointestinal Masses and Inflammatory Conditions of Gastrointestinal Tract in Children** 1131
Arun Kumar Gupta, Devasenathipathy Kandasamy, Raju Sharma, Manisha Jana

70. **Hepatic and Pancreatic Masses in Children** 1162
Kushaljit Singh Sodhi, Akshay Kumar Saxena, Anmol Bhatia

71. **Imaging and Interventions in Pediatric Budd–Chiari Syndrome** 1186
Kumble S Madhusudhan, Sanjay Sharma

72. **Childhood Biliopathies** 1209
Rashmi Dixit, Sapna Singh, Anju Garg

JAYPEE BROTHERS

73. Congenital Anomalies of the Urinary Tract 1234
Arun Kumar Gupta, Chandan J Das, Smriti Hari

74. Urinary Tract Infections (Including Vesicoureteral Reflux and Neurogenic Bladder) 1255
Anmol Bhatia, Kushaljit Singh Sodhi, Akshay Kumar Saxena

75. Renal and Retroperitoneal Masses 1264
Anju Garg, Alpana Manchanda, Radhika Batra

76. Evaluation of Female Pelvis and Testicular Abnormalities 1300
Anmol Bhatia, Kushaljit Singh Sodhi, Akshay Kumar Saxena

77. Imaging of Disorders of Sex Differentiation 1321
Manisha Jana, Arun Kumar Gupta, Sanjay Sharma

78. Skeletal Dysplasias 1338
Gaurav Shanker Pradhan, Radhika Batra, Sapna Singh

79. Short Stature and Skeletal Maturity Assessment 1362
Manisha Jana, Arun Kumar Gupta, Priyanka Naranje

80. Spinal Dysraphism 1376
Raju Sharma, Ankur Goyal, Devasenathipathy Kandasamy

81. Imaging of Pediatric Joint Pathology 1395
Anjali Prakash, Rajat Jain, Gaurav Shanker Pradhan, Jyoti Kumar

82. Benign Bone and Soft-tissue Tumors and Conditions 1419
Mahesh Prakash, Kushaljit Singh Sodhi, Anindita Sinha

83. Pediatric Malignant Bone and Soft-tissue Tumors 1434
Ankur Goyal, Manisha Jana, Deep N Srivastava

84. Congenital Brain Anomalies 1451
Sameer Vyas, Vikas Bhatia, Ajay Kumar

85. Hypoxic-ischemic Encephalopathy 1469
Atin Kumar, Manisha Jana, Devasenathipathy Kandasamy, Arun Kumar Gupta

86. Craniospinal Sonography 1488
Radhika Batra, Rashmi Dixit, Manisha Jana, Anjali Prakash, Devasenathipathy Kandasamy

87. Infectious and Inflammatory Diseases of the Brain 1519
Chirag Kamal Ahuja, Anuj Prabhakar, Paramjeet Singh

88. Pediatric Brain Tumors 1551
Shailesh B Gaikwad, Ajay Garg

89. Metabolic Disorders of the Brain 1584
Sapna Singh, Jyoti Kumar, Rashmi Dixit

90. Pediatric Neck Lesions 1622
Smita Manchanda, Ashu Seith Bhalla

JAYPEE BROTHERS

Section 4: Gastrointestinal and Hepatobiliary Imaging

91. **Imaging Techniques for Abdomen** 1645
Smriti Hari, Smita Manchanda

92. **Imaging a Patient with Dysphagia** 1662
Alpana Manchanda, Jyoti Kumar, Gaurav Shanker Pradhan

93. **Tumors of Stomach and Duodenum** 1696
Gaurav Shanker Pradhan, Rashmi Dixit, Jyoti Kumar, Virendra Jain

94. **Small Bowel Tumors** 1720
Rashmi Dixit, Gaurav Shanker Pradhan, Anju Garg

95. **Colorectal Tumors** 1752
Naveen Kalra, Mandeep Kang, Mahesh Prakash

96. **Ulceroconstrictive Diseases of the Gut** 1776
Devasenathipathy Kandasamy, Manisha Jana, Arun Kumar Gupta

97. **Imaging of Ischemic Bowel Disease** 1798
Ajay Gulati, Naveen Kalra, Mandeep Kang

98. **Gastrointestinal Hemorrhage: Imaging and Intervention** 1812
Deep Narayan Srivastava, Kumble S Madhusudhan, Shivanand Gamanagatti

99. **Imaging of Appendix** 1827
Anju Garg, Sapna Singh

100. **Diffuse Liver Diseases** 1844
Surabhi Vyas, Ashu Seith Bhalla, Arun Kumar Gupta

101. **Clinical Aspects of Liver Cirrhosis: A Perspective for the Radiologist** 1859
Shashi Bala Paul, Shivanand Gamanagatti, Arun Kumar Gupta, Subrat Kumar Acharya

102. **Benign Focal Lesions of Liver** 1874
Sapna Singh, Anjali Prakash

103. **Malignant Focal Lesions of Liver** 1904
Raju Sharma, Kumble S Madhusudhan

104. **Interventional Radiology in Treatment of Liver Tumors** 1927
Deep Narayan Srivastava, Shivanand Gamanagatti, Shashi Bala Paul

105. **Imaging in Liver Transplant** 1945
Chandan J Das, Kumble S Madhusudhan, Deep Narayan Srivastava

106. **Imaging and Interventions in Hepatic Venous Outflow Tract Obstruction** 1956
Naveen Kalra, Ujjwal Gorsi, Niranjan Khandelwal

107. **Imaging Approach to Obstructive Biliopathy** 1972
Anjali Prakash, Rashmi Dixit

108. **Inflammatory Pathologies of the Biliary Tract** 1979
Anmol Bhatia, Ajay Gulati, Uma Debi

109. **Malignant Pathologies of Biliary Tree** 1989
Ujjwal Gorsi, Ajay Gulati, Mandeep Garg

110. **Biliary Interventions** 2001
Mandeep Kang, Naveen Kalra, Anupam Lal

JAYPEE BROTHERS

111. **Acute Pancreatitis: Imaging and Interventions** 2013
Kumble S Madhusudhan, Raju Sharma

112. **Chronic Pancreatitis and its Variants** 2031
Anupam Lal, Manphool Singhal, Mandeep Kang

113. **Pancreatic Cancer Imaging** 2044
Ankur Goyal, Raju Sharma

114. **Cystic Pancreatic Tumors and Neuroendocrine Tumors of Pancreas** 2066
Jyoti Kumar, Alpana Manchanda, Sapna Singh

115. **Nontraumatic Acute Abdomen** 2079
Mandeep Kang, Anmol Bhatia, Anindita Sinha

116. **Imaging in Abdominal Trauma** 2095
Atin Kumar, Shivanand Gamanagatti, Chandrashekhara SH

117. **Imaging of Peritoneum and Mesentery** 2113
Anju Garg, Anjali Prakash, Alpana Manchanda

118. **Imaging of Spleen** 2149
Mukesh Kumar Yadav, Priyanka Naranje, Ekta Dhamija

119. **Imaging of the Postoperative Abdomen** 2178
Mandeep Kang, Ujjwal Gorsi, Anmol Bhatia

120. **Portal Hypertension: Imaging and Intervention** 2196
Shivanand Gamanagatti, Kumble S Madhusudhan

121. **Percutaneous Nonvascular Gastrointestinal Tract Interventions** 2223
Shivanand Gamanagatti, Deep Narayan Srivastava, Chandrashekhara SH

VOLUME 3

Section 5: Chest and Cardiovascular Imaging

122. **Chest Radiography and Sonography: Techniques and Anatomy** 2237
Mahesh Prakash, Manavjit Singh Sandhu

123. **MDCT and MRI Thorax: Techniques and Normal Anatomy** 2250
Rashmi Dixit, Anjali Prakash, Alpana Manchanda

124. **Basic Radiographic Pattern of Lung Diseases** 2278
Gaurav Shanker Pradhan, Radhika Batra, Rashmi Dixit, Alpana Manchanda

125. **Basic Patterns of Lung Disease on CT** 2293
Alpana Manchanda, Satyam, Gaurav Shanker Pradhan, Jyoti Kumar

126. **Imaging of Pulmonary Tuberculosis** 2316
Mandeep Garg, Anmol Bhatia, Naveen Kalra

127. **Nontubercular Pulmonary Infections** 2324
Anju Garg, Swati Gupta, Jyoti Kumar

JAYPEE BROTHERS

128. **Pulmonary Manifestations in Immunocompromised Host** 2350
Mandeep Kang, Pankaj Gupta

129. **Pattern Approach to Interstitial Lung Disease and Imaging of Idiopathic Interstitial Pneumonias** 2363
Mandeep Garg, Uma Debi

130. **Imaging of Interstitial Lung Disease of Known Etiology** 2372
Smriti Hari, Surabhi Vyas, Sanjay Sharma, Deep Narayan Srivastava

131. **Miscellaneous Interstitial Lung Diseases** 2381
Ashu Seith Bhalla, Manisha Jana

132. **Mediastinum** 2393
Raju Sharma, Kumble S Madhusudhan, Arun Kumar Gupta

133. **Imaging of Solitary Pulmonary Nodule** 2417
Sapna Singh, Anju Garg, Anjali Prakash

134. **Imaging of Pulmonary Neoplasms** 2442
Priyanka Naranje, Mukesh Yadav, Chandan J Das, Arun Kumar Gupta

135. **Imaging of the Tracheobronchial Tree** 2464
Ashu Seith Bhalla, Smita Manchanda

136. **Intensive Care Chest Radiology** 2490
Akshay Kumar Saxena, Kushaljit Singh Sodhi, Nidhi Prabhakar

137. **Imaging in Thoracic Trauma** 2499
Atin Kumar, Shivanand Gamanagatti

138. **Imaging of Pleura** 2512
Anjali Prakash, Rashmi Dixit, Sapna Singh

139. **Imaging of the Diaphragm and Chest Wall** 2540
Ujjwal Gorsi, Sameer Vyas, Anupam Lal

140. **Bronchial Artery Embolization** 2556
Ashu Seith Bhalla, Ankur Goyal

141. **Diagnostic and Therapeutic Interventions in Chest** 2568
Naveen Kalra, Mandeep Kang, Anupam Lal, Ujjwal Gorsi

142. **Chest X-ray Evaluation in Cardiac Disease** 2580
Sanjiv Sharma, Gurpreet Singh Gulati, Priya Jagia

143. **Imaging Approach in Children with Congenital Heart Disease** 2587
Priya Jagia, Sanjiv Sharma, Gurpreet Singh Gulati, Sanjeev Kumar

144. **Imaging in Ischemic Heart Disease** 2595
Gurpreet Singh Gulati, Sanjiv Sharma, Priya Jagia

145. **Imaging in Cardiomyopathies** 2608
Priya Jagia, Gurpreet Singh Gulati, Sanjiv Sharma

146. **Imaging Evaluation of Cardiac Masses** 2614
Gurpreet Singh Gulati, Priya Jagia, Sanjiv Sharma

147. **Imaging Diagnosis of Valvular Heart Disease** 2626
Priya Jagia, Sanjiv Sharma, Gurpreet Singh Gulati

JAYPEE BROTHERS

148. **Imaging of the Pericardium** 2634
Jyoti Kumar, Sapna Singh, Anju Garg, Gaurav Shanker Pradhan

149. **Imaging and Interventions of Aorta** 2647
Manphool Singhal, Kartik Ganga, Sanjeev Kumar, Vivek Gupta, Niranjan Khandelwal

150. **Imaging in Pulmonary Vascular Disease** 2683
Ujjwal Gorsi, Sanjeev Kumar, Kushaljit Singh Sodhi, Akshay Kumar Saxena

151. **Peripheral Vascular Diseases: Imaging and Interventions** 2698
Devasenathipathy Kandasamy, Shivanand Gamanagatti

Section 6: Musculoskeletal and Breast Imaging

152. **Current Concepts in Cross-sectional Imaging of Musculoskeletal Diseases** 2715
Shivanand Gamanagatti, Ankur Goyal, Raju Sharma

153. **Nuclear Medicine Imaging for Musculoskeletal Disorders** 2734
Rakesh Kumar, Madhavi Tripathi, Shamim Ahmed Shamim

154. **Angiography and Interventions in Musculoskeletal Lesions** 2750
Deep Narayan Srivastava, Madhusudhan KS

155. **Tuberculosis of Bones and Joints** 2763
Gaurav Shanker Pradhan, Rashmi Dixit, Jyoti Kumar

156. **Nontubercular Bone and Joint Infections** 2775
Anindita Sinha, Manphool Singhal, Kushaljit Singh Sodhi

157. **Tuberculosis of the Spine** 2791
Rashmi Dixit, Gaurav Shanker Pradhan, Radhika Batra

158. **Nontubercular Infections of the Spine** 2807
Sameer Vyas, Manavjit Singh Sandhu, Ujjwal Gorsi

159. **Imaging in Rheumatological Disorders** 2820
Mandeep Kang, Gita Devi, Mahesh Prakash

160. **Degenerative Disease of the Spine** 2839
Jyoti Kumar, Anju Garg, Anjali Prakash

161. **Skeletal Disorders of Metabolic and Endocrine Origin** 2852
Alpana Manchanda, Jyoti Kumar, Swati Gupta

162. **Osteoporosis** 2885
Chirag Kamal Ahuja, Mukesh Kumar Yadav, Vikas Bhatia, Ajay Kumar

163. **Diagnostic Approach to Focal Bone Lesions** 2902
Shivanand Gamanagatti, Raju Sharma

164. **Benign Bone Tumors and Tumor-like Conditions** 2916
Mahesh Prakash, Anindita Sinha, Akshay Kumar Saxena

165. **Malignant Bone Tumors** 2930
Anju Garg, Radhika Batra, Sapna Singh

166. **Imaging in Marrow Disorders: Benign and Malignant** 2961
Swati Gupta, Sapna Singh, Alpana Manchanda

JAYPEE BROTHERS

167. Magnetic Resonance Imaging of Shoulder and Temporomandibular Joints 2995
Mahesh Prakash, Paramjeet Singh

168. Magnetic Resonance Imaging of Wrist 3022
Anindita Sinha, Harish Bhujade, Mahesh Prakash

169. Magnetic Resonance Imaging of the Hip and Pelvis 3046
Anjali Prakash, Alpana Manchanda, Rashmi Dixit

170. Magnetic Resonance Imaging of the Knee 3076
Sapna Singh, Anjali Prakash, Gaurav Shanker Pradhan

171. Magnetic Resonance Imaging of Ankle 3122
Anindita Sinha, Mahesh Prakash

172. Radiological Evaluation of Appendicular Trauma 3141
Atin Kumar, Devasenathipathy Kandasamy, Arun Kumar Gupta

173. Imaging of Soft Tissue Tumors 3155
Ashu Seith Bhalla, Ankur Goyal, Priyanka Naranje

174. Imaging of Peripheral Nerves 3175
Mahesh Prakash, Harish Bhujade, Anindita Sinha

175. Imaging in Prosthetic Joints 3194
Ankur Goyal, Shivanand Gamanagatti

176. A Systematic Approach to Imaging of Breast Lesions 3207
Smita Manchanda, Smriti Hari, Manisha Jana, Arun Kumar Gupta

177. Benign and Malignant Lesions of the Breast 3237
Smriti Hari, Smita Manchanda, Ekta Dhamija

178. Breast Interventions 3262
Surabhi Vyas, Smriti Hari, Smita Manchanda

179. Advances in Breast Imaging 3280
Tulika Singh, Veenu Singla, Uma Debi

180. Male Breast Imaging 3293
Veenu Singla, Tulika Singh, Nidhi Prabhakar

VOLUME 4

Section 7: Neuroradiology Including Head and Neck Imaging

181. Evaluation of Plain X-ray Skull: A Systematic Approach 3305
Niranjan Khandelwal, Sudha Suri, Vikas Bhatia

182. Normal Anatomy of Brain on CT and MRI 3319
Paramjeet Singh

183. Normal Cerebral Angiography 3341
Shailesh B Gaikwad, Ajay Kumar, Anuj Prabhakar

JAYPEE BROTHERS

184. **Advances in Neuroimaging Techniques: Computed Tomography** 3349
Sameer Vyas, Paramjeet Singh, Niranjan Khandelwal

185. **Advances in Neuroimaging Techniques: Magnetic Resonance Imaging** 3361
Paramjeet Singh, Niranjan Khandelwal, Sameer Vyas

186. **Magnetic Resonance Spectroscopy** 3381
Vikas Bhatia, Paramjeet Singh, Niranjan Khandelwal

187. **Functional MRI** 3404
Anuj Prabhakar

188. **Imaging and Interventions in Cerebral Ischemia** 3412
Shailesh B Gaikwad, Anuj Prabhakar

189. **Imaging of Subarachnoid Hemorrhage** 3430
Niranjan Khandelwal, Vivek Gupta

190. **Endovascular Management of Intracranial Aneurysms** 3447
Shailesh B Gaikwad

191. **Endovascular Management of Arteriovenous Malformations** 3463
Ajay Kumar, Niranjan Khandelwal, Shailesh B Gaikwad, Chirag Kamal Ahuja, Vivek Gupta

192. **Carotid-cavernous Fistulas** 3478
Chirag Kamal Ahuja, Vivek Gupta, Ajay Kumar, Niranjan Khandelwal

193. **Central Nervous System Infections** 3492
Sapna Singh, Gaurav Shanker Pradhan, Anju Garg, Anjali Prakash

194. **Imaging of White Matter Disease** 3545
Anjali Prakash, Jyoti Kumar, Swati Gupta, Gaurav Shanker Pradhan

195. **Imaging of Epilepsy** 3584
Shailesh B Gaikwad, Anuj Prabhakar

196. **Imaging of Supratentorial Brain Tumors** 3601
Shailesh B Gaikwad, Ajay Garg

197. **Imaging of Infratentorial Tumors** 3622
Ajay Garg

198. **Sellar and Parasellar Lesions** 3645
Paramjeet Singh, Chirag Kamal Ahuja, Niranjan Khandelwal

199. **Intraventricular Lesions** 3673
Chirag Kamal Ahuja, Paramjeet Singh, Niranjan Khandelwal

200. **Imaging of the Temporal Bone** 3697
Vivek Gupta, Niranjan Khandelwal

201. **Imaging of the Globe and Orbit** 3717
Sanjay Sharma, Smriti Hari, Deep Narayan Srivastava, Kumble S Madhusudhan

202. **Imaging of the Paranasal Sinuses** 3735
Vivek Gupta, Niranjan Khandelwal

203. **Imaging of the Neck Spaces** 3759
Rashmi Dixit, Sapna Singh, Radhika Batra, Alpana Manchanda

204. **Thyroid Imaging** 3795
Alpana Manchanda, Anju Garg, Jyoti Kumar, Rashmi Dixit

JAYPEE BROTHERS

205. **Malignancies of Upper Aerodigestive Tract** 3826
Mukesh Kumar Yadav, Ankur Goyal, Ashu Seith Bhalla, Sanjay Sharma

206. **Imaging of Skull Base Lesions** 3850
Atin Kumar, Manisha Jana, Priyanka Naranje, Ashu Seith Bhalla

207. **Maxillofacial Imaging: Imaging of Cysts, Tumors and Tumor-like Conditions of the Jaw** 3870
Ashu Seith Bhalla, Smita Manchanda, Atin Kumar, Chandan J Das

208. **Craniovertebral Junction Anomalies** 3894
Niranjan Khandelwal, Vivek Gupta

209. **Endovascular Management of Craniofacial Vascular Lesions** 3910
Ajay Kumar, Niranjan Khandelwal, Chirag Kamal Ahuja

210. **Imaging of Head Trauma** 3924
Shivanand Gamanagatti, Atin Kumar, Arun Kumar Gupta, Surabhi Vyas

211. **Imaging of Facial Trauma** 3947
Ajay Kumar, Vivek Gupta, Paramjeet Singh

212. **Imaging of Acute Spinal Trauma** 3961
Sameer Vyas, Niranjan Khandelwal, Paramjeet Singh

213. **Spinal Neoplasm** 3975
Ajay Garg

214. **Spinal Vascular Malformations** 3995
Shailesh B Gaikwad

215. **Imaging of Low Backache** 4005
Raju Sharma, Shivanand Gamanagatti, Devasenathipathy Kandasamy, Arun Kumar Gupta

216. **Localization in Clinical Neurology** 4043
Manish Modi, Sudesh Prabhakar

217. **Basic Neuropathology** 4054
Kirti Gupta, Rakesh Kumar Vasishta

Index 4069

JAYPEE BROTHERS

CHAPTER

183

Normal Cerebral Angiography

Shailesh B Gaikwad, Ajay Kumar, Anuj Prabhakar

JAYPEE BROTHERS

CEREBRAL ANGIOGRAPHY TECHNIQUE

INTRODUCTION

This is an important albeit invasive procedure wherein most cases of suspected vascular pathologies baring few exceptions are diagnosed. It is a direct examination of the blood vessels that provide not only the information of the vascular anatomy but also the flow dynamics.

Historical Background

Cerebral angiography was first introduced by Moniz. Moniz and Almeida Lima, performed the first cerebral angiography on living human patients in 1927.[1]

Definition

It is the demonstration of the cerebral vascular anatomy by direct injection of the iodinated contrast medium into the vessel.

Six Vessel Angiography

It includes the study of the following vessels:

1. Right internal carotid artery
2. Left internal carotid artery
3. Right external carotid artery
4. Left external carotid artery
5. Right vertebral artery
6. Left vertebral artery.

Indications[2]

- Evaluate intracranial circulation when CT or MR angiography is inconclusive either due to failure to visualize the pathology or patient factors like clips, coils or patient motion.
- Define presence/extent of atherosclerotic vessel disease, especially when information on the presence and nature of collateral supply is needed.
- Define etiology of hemorrhage.
- Define presence, location, and anatomy of intracranial aneurysms and arteriovenous malformations.
- Evaluate vasospasm related to subarachnoid hemorrhage.
- Investigate reversible cerebral vasoconstriction syndrome.
- Define presence/extent of trauma to cervicocerebral vessels.
- Define vascular supply to tumors.
- Define presence/extent of vasculitis.
- Evaluate pulsatile tinnitus or cranial bruit.
- Define presence of venous occlusive disease.
- Perform physiologic testing of brain function and balloon test occlusion.
- Determine presence of intracranial flow for the purpose of documenting angiographic brain death, especially when nuclear medicine blood flow study is inconclusive.
- Evaluate cerebral circulation before or after planned intervention.

Contraindications

There are no absolute contraindications to cerebral angiography.[3] Relative contraindications include:

- Allergy to iodinated contrast agents
- Abnormal renal function
- Coagulopathy
- Local site infection
- Pregnancy.

Patient Preparation

Careful history taking is very important before the procedure. It is advisable to take informed consent from the patient in case of elective procedure and from relatives in case of emergency. Patient should be well hydrated before the procedure. Patient must have passed urine before the procedure. A detailed informed consent should be obtained including specific risks of the procedure. Laboratory parameters that should be evaluated include complete blood cell count, serum creatinine or glomerular filtration rate, prothrombin time and



FIGS. 1A AND B: DSA biplane machine with monitors.

international normalized ratio, as dictated by the patients' clinical situation. Anticoagulants should be withheld when possible. Patients should eat nothing by mouth 6 hours before the procedure. The morning insulin dose should be reduced in half. Inguinal region should be shaved and prepared prior to the procedure.[3]

Requirements

- Digital subtraction angiography (DSA) machine **(Figs. 1A and B)**
- Catheterization equipment **(Fig. 2)**
- Disposables.

Catheterization Equipment

Cleaning agents, blade no. 11, puncture needle, vascular sheath, mini-guidewire, various catheters, Terumo guidewire, and syringes.



FIG. 2: Instruments required: (left to right) Sheath, dilator, puncture needle, syringes, terumo wire, short guidewire, single puncture needle, catheter.

Site of the Puncture

The common femoral artery (CFA) crosses the pelvic brim at the level of the inguinal ligament, which extends from the spine of the anterior superior iliac crest to the pubic tubercle. It then enters the femoral sheath which is made up of 3 compartments containing the femoral artery laterally and the vein medially. The medial and smallest compartment is called the femoral canal which contains lymphatic vessels and lymph nodes. Lateral to the femoral artery and outside the femoral sheath is the femoral nerve. The CFA represents an ideal site for arterial access and sheath insertion because it is relatively large, is less involved with atherosclerosis, and is readily compressible against the underlying head of the femur.

The ideal site of femoral arterial puncture (not skin puncture) is a point 1 cm lateral to the most medial aspect of the femoral head, midway between its superior and inferior border. Various landmarks have been utilized for identification of the femoral artery:

1. The skin crease may be used as a marker for the underlying inguinal ligament, and an arterial puncture 2 to 3 cm below the midpoint of the skin crease has been used. This technique may be inaccurate in obese patients.
2. A point 2 to 3 cm below the midpoint of a line between the anterior superior iliac spine and pubic tubercle (mid inguinal point) may be used as a site for femoral arterial cannulation **(Figs. 3 and 4)**.
3. Fluoroscopic landmark: The femoral head is identified. skin puncture done at the lower border of the femoral head, with the needle entering the skin at a 30° to 45° angle. Artery puncture is performed at the mid portion of the head of femur in its medial third.
4. Ultrasound-guided femoral arterial cannulation may be performed in obese patients or in those with a weak pulse.

Caudal punctures have an increased risk of hematoma, and pseudoaneurysms as there is lack of underlying bony structure and scaffolding by femoral sheath. High puncture above the inguinal ligament is associated with an increased

JAYPEE BROTHERS

risk of retroperitoneal hemorrhage due to lack of effective compression and tamponade. Infrainguinal puncture and bleeding may also cause retroperitoneal hemorrhage due to tracking of the blood upward underneath the ligament and into the retroperitoneal space.[4]

Preparation

Sterilize the site first with savlon, then with betadine and with spirit in the last.

Wipe with sterilized gauze piece.

Local Anesthesia

For local anesthesia (LA), give subcutaneous injection of 2% xylocaine without adrenaline. Palpate the artery with index, mid and ring finger of the left hand. Infiltrate 2–3 mL each on the either side of the artery. Care must be taken to not to inject LA into the vessel, before giving injection always check by withdrawing to rule out arterial puncture. Give injection slowly for the patient comfort **(Fig. 5)**.

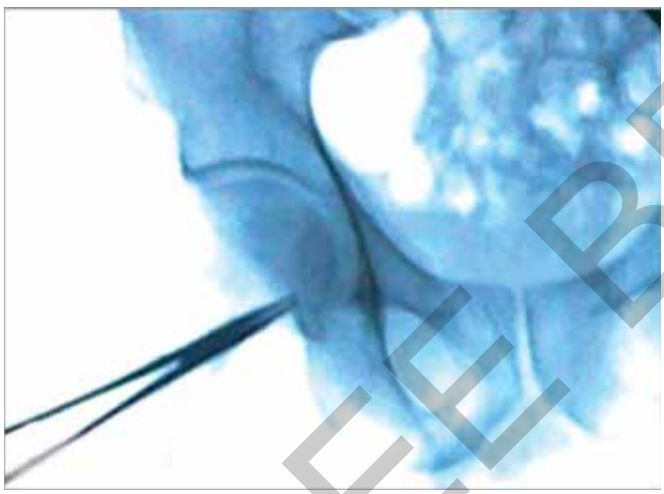

FIG. 3: Marking the site of puncture on fluoroscopy.

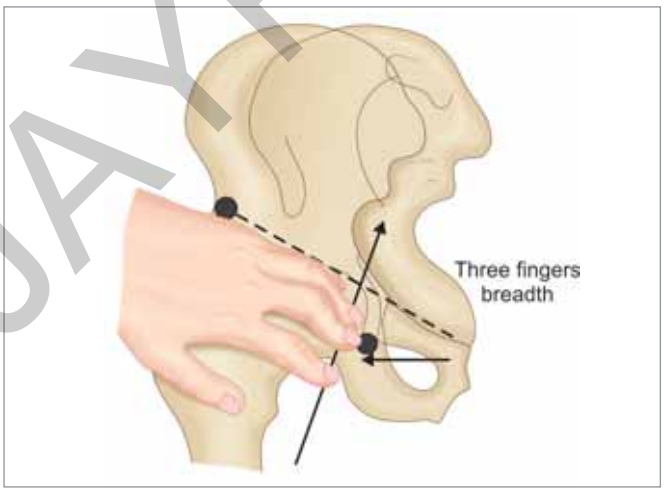

FIG. 4: Localization and palpation of femoral artery.

Artery Puncture

- Give 3 mm wide and 3 mm deep, superficial skin incision at the puncture site by using 11 no. blade. It is ideal to check the site under fluoroscopy before arterial puncture.
- **Seldinger technique:** Palpate femoral artery by the index, middle and ring finger, of the left hand. Take Medicut (puncture needle with needle inside and plastic cannula outside) in the right hand and advance toward the artery at about 45° angle. Feel the pulse of the artery through the needle in the right hand and as one feels it over femoral artery, enter artery with a jab **(Fig. 6)**. Remove the needle and slowly withdraw the cannula till the jet of the blood is obtained. Rule out venous puncture (blood will not come out in jets). After confirming arterial access introduce a 0.035-inch short J-tip guidewire, and remove the cannula. If resistance is encountered as the guidewire leaves the needle tip, the guidewire should be removed and the needle adjusted to ensure brisk flow. Lowering the hub of the needle before guidewire insertion or slight repositioning either laterally or medially will aid in smooth guidewire advancement. The guidewire must enter smoothly without resistance. Is case excess resistance is felt, the needle and guidewire complex must be removed and a fresh attempt should be made. Finally, introduce arterial sheath over the short guidewire.[4]
- Again check the position of the sheath by withdrawing blood using syringe. Arterial blood will come into syringe in pulsatile manner and with thrust.
- Inject 2500 unit of heparin (0.5 mL) and flush sheath with saline to flush in remaining part of heparin in the sheath lumen.
- Take the desired catheter and start angiography **(Fig. 7)**.

Puncture Technique

It is of two types:

1. Single wall puncture
2. Double wall puncture.



JAYPEE BROTHERS



FIG. 5: Infiltrating local anesthetic at the site of puncture.



FIG. 6: Arterial puncture.



FIG. 7: Placement of arterial sheath.

In single wall puncture technique, only the anterior wall of artery is punctured and in double wall both anterior as well as posterior wall get punctured. Single wall is safe in experienced hands while double wall is safer in inexperienced hand as chances of dissection of artery are higher in single wall technique. In double wall technique the chance of posterior wall hematoma is high. Improper technique can lead to trauma of the vessel regardless of the type of needle used.

Procedure

The aortic arch anatomy will help determine the selection of the catheter. Types I and II arch configurations can be routinely catheterized with an angled catheter, while a reverse curve catheter is generally necessary to select vessels arising from Type III arches. In patients with atherosclerotic vessel disease a hydrophilic 0.035-inch wire with a curved tip such as the terumo wire (Terumo Interventional Systems, Somerset, NJ) is used. The guidewire is advanced into the artery followed by the catheter. As the wire is removed, an inadvertent vacuum effect may occur if the catheter is in a small artery or if the end hole is wedged against the wall of the artery. To prevent inadvertent air embolus, the guidewire should be removed slowly, keeping the catheter hub filled with heparinized saline by dripping or injecting it into the hub while the wire is withdrawn.[3] For Internal carotid artery (ICA) injection, an angled tip catheter and hydrophilic guidewire are needed. If a reverse curve catheter is used for common carotid artery (CCA) catheterization, an exchange of catheters is required over an exchange length guidewire placed in the external carotid artery.

While performing diagnostic angiography for vertebral arteries (VA), the left VA is preferred as it is mostly larger than the right in diameter. The right VA is catheterized only if the left VA is not accessible, right VA pathology is suspected, or when contrast does not reflux into the right posterior inferior cerebellar artery (PICA) on left VA injection. Extra care should be taken when VA injection is performed, as the VA is prone to vasospasm and dissection.[2]

For anterior intracranial cerebral angiography, standard AP Towne's view and lateral projections are used. Oblique images at 45 degrees may separate overlapping arteries. Special views like Stenvers view for middle cerebral artery (MCA) and submental vertex view for anterior communicating artery may be acquired if necessary. For vertebral arteriograms, the standard projections are AP (Towne's view) and lateral projections centered caudally and dorsally to cover the posterior circulation.[3]

Important Points to Remember

Check for free backflow of the blood in the catheter. Inject test amount 2–3 mL of contrast before taking run to check the exact position of the catheter and to check vascular spasm. Instruct the patient before every injection and inform the effect of the contrast like flushing and warm sensation or alteration in the taste, etc.

Postprocedural Management

Before removing the sheath, aspirate few milliliter of the blood to aspirate out any thrombus that could have formed during the procedure. If there is free backflow and if no clots

JAYPEE BROTHERS

are visible in the aspirate, the sheath can be safely removed. Compress the arterial puncture site which is about 0.5 cm above the skin puncture site (for about 20-min). Compress the actual puncture site with middle finger, compress above it with index finger and below it with ring finger. Puncture site should be clearly visible during compression so that hematoma formation can be avoided. Do not obliterate the pulse, distal pulse should be faintly palpable. Apply steady moderate pressure for 15 minutes, reduce the pressure in next 5-minut. Never remove compression abruptly. After compression feel all distal pulses. If the patient has both an arterial and a venous sheath, the arterial sheath should be removed first and the venous sheath removed 5 minutes later. This technique avoids the risk of arteriovenous fistula formation and also preserves a venous access for medication administration in case of a vasovagal reaction.[4]

Bed rest is recommended for 8 hours after the procedure. The patient is instructed to avoid bending his/her leg. Check groin for hematoma formation. Monitor BP, pulse and neurological status of the patient. If patient is unable to pass urine then catheterize the patient until the patient is able to ambulate.

Complications

Complications may be neurological and non-neurological. Stroke is the main neurological complication. Non-neurological complications are renal failure, arterial occlusions requiring intervention, arteriovenous fistula, and hematoma requiring transfusions or surgical intervention. In a study by Kaufmann et al. 19826 consecutive patients undergoing DSA were retrospectively reviewed. Neurologic complications occurred in 2.63%, with 0.14% of these causing permanent disability. Deaths occurred in 0.06%. Access-site hematoma was the most common complication overall (4.2%). Patients suffering from atherosclerotic vascular disease, subarachnoid hemorrhage and frequent transient ischemic attack were more likely to have complications.[5]

CEREBRAL ANGIOGRAPHIC ANATOMY

ARTERIAL ANATOMY

The brain is supplied by the two internal cerebral arteries, and two vertebral arteries which join to form the basilar artery. The basilar artery divides into two posterior cerebral arteries which along with posterior communicating arteries form the posterior part of circle of Willis. The anterior part of circle of Willis is constituted by both anterior cerebral arteries, anterior communicating artery and internal cerebral arteries.

The internal carotid artery (ICA) is divided into the following segments as per the Bouthillier classification system:[6]

- C1 cervical—CCA bifurcation to entrance of carotid canal
- C2 petrous—extends up to posterior edge of formaen lacerum
- C3 lacerum—extends up to superior margin of petrolingual ligament
- C4 cavernous—extends up to proximal dural ring (anterior clinoid process)
- C5 clinoid—extends up to distal dural ring
- C6 ophthalmic—extends up to just proximal to the origin of Posterior communicating artery (PCom)
- C7 communicating—extends up to ICA bifurcation

ICA on each side enters the cranium by passing through the carotid canal in the petrous temporal bone (petrous segment). Petrous ICA give rise to Vidian artery (artery of pterygoid canal) and caroticotympanic artery which supplies middle and internal ear and occasionally the persistent stapedial artery. At times, the ICA courses posterolaterally than anteromedial (normal course) and presents as pulsatile retrotympanic mass called. Knowledge of this variant is necessary to differentiate it from glomus tympanicum so that hazardous biopsy can be avoided.

The ICA runs within the cavernous sinus to pierce the dura to enter the subarachnoid space adjacent to the anterior clinoid process. The cavernous ICA can be subdivided into ascending cavernous (C5), first posterior genu (C4), horizontal part (C3), second anterior genu (C2) and the rest of cavernous segment (C1). Meningohypophyseal artery arises near junction of C5 and C4. Meningohypophyseal artery branches supply the posterior pituitary, cavernous sinus, clival dura and sometimes III to VI cranial nerves. The horizontal part (C3) extends between first posterior (C4) and second anterior genu (C2). After second genu (C2), rest of the cavernous ICA is called as C1 segment **(Fig. 8)**. The inferolateral trunk arises from C4 segment and supplies the dura of the cavernous sinus and cranial nerves III, IV, V and VI. The superior hypophyseal trunk arises from supraclinoid ICA and supplies anterior pituitary. The ophthalmic artery arises from ophthalmic ICA **(Fig. 9)**. The anterior choroidal artery arises from ICA just above PCom origin which arises posteromedially from communicating segment of ICA. The anterior choroidal artery supplies the choroid plexus

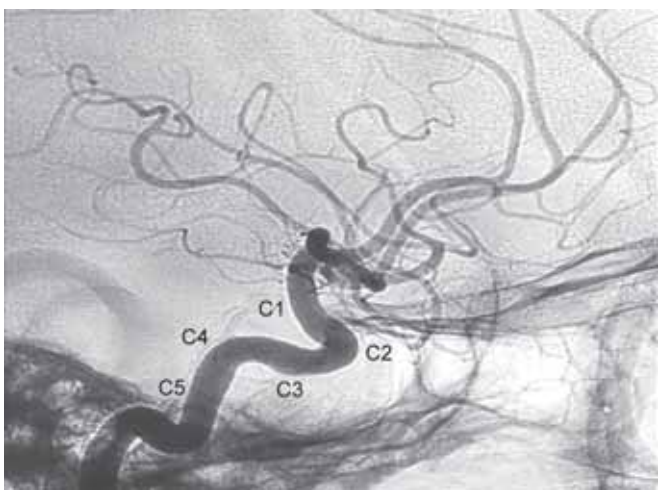

FIG. 8: ICA cavernous segments: Image showing cavernous ICA segments. C5 segment extends from carotid canal opening to first posterior genu (C4), horizontal segment (C3) extends between first posterior genu (C4) and second anterior genu (C2). Rest of cavernous ICA is called (C1).

JAYPEE BROTHERS

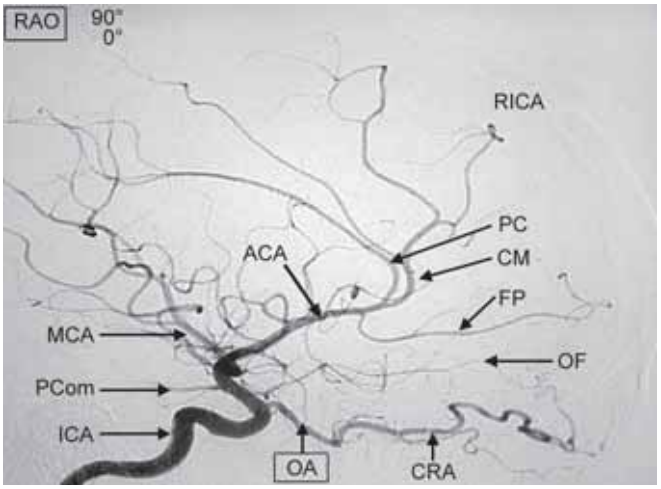

FIG. 9: Anterior circulation lateral view: Selective ICA angiogram lateral view showing different important branches (as annotated). (ICA: internal carotid artery; OA: ophthalmic a rtery; CRA: central retinal artery, PCom: posterior communicating artery; MCA: middle cerebral artery; ACA: anterior cerebral artery; OF: orbitofrontal artery; FP: frontopolar artery; CM: callosomarginal artery; PC: pericallosal artery).

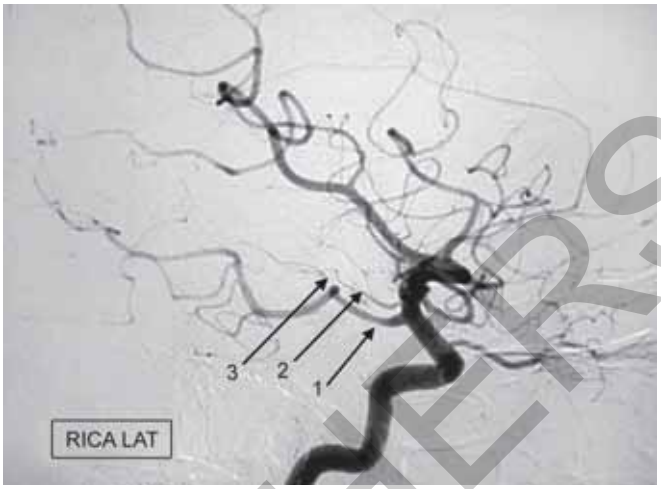

FIG. 10: Lateral ICA angiogram showing fetal PCA (1), anterior choroidal artery (2) and the plexal point (3), the point where artery enters the choroidal fissure.

of the lateral ventricles, medial temporal lobe and some striate branches to deep ganglionic structures **(Fig. 10)**. The PCom runs posteriorly to join the posterior cerebral arteries (branches of basilar artery) to complete the circle of Willis. PCom supplies the deep ganglionic structures including the thalamus.

The anterior cerebral arteries proceed medially within the interhemispheric fissure separated by the falx. Both anterior cerebral arteries are connected by the anterior communicating artery in the midline completing the anterior part of circle of Willis (located in the suprasellar cistern).

Anterior cerebral artery (ACA) is thus divided into three segments. Horizontal (A1) segment which extends from the ACA origin to its junction with the anterior communicating artery (ACom). The medial lenticulostriate arteries arise from A1 segment. A2 segment which extends from the junction of ACom to its bifurcation into pericallosal and callosomarginal arteries. The orbitofrontal and frontopolar arteries arise from A2 segment. The recurrent artery of Heubner which is a lenticulostriate branch may arise from proximal A2 segment and less commonly from A1 segment. A3 segment refers to the cortical branches that supply the anterior two-thirds of medial hemispheric surface and a small superior area over the convexities.

Middle cerebral artery (MCA) is also divided into three major segments. Horizontal (M1) segment: Extends from the origin of MCA to its bifurcation or trifurcation at Sylvian fissure. The lateral lenticulostriate arteries arise from M1 segment and supply the lentiform nucleus, parts of internal capsule and caudate nucleus. Insular (M2) segment: At its genu, the MCA divides into its insular (M2) branches, which loop over the insula and pass laterally to exit from sylvian fissure. Opercular (M3) segment: This gives off branches that emerge from the Sylvian fissure and ramify over the hemispheric surface. The insular and the opercular branches supply the temporal, parietal and variable parts of frontal and occipital lobes **(Figs. 11 and 12)**.

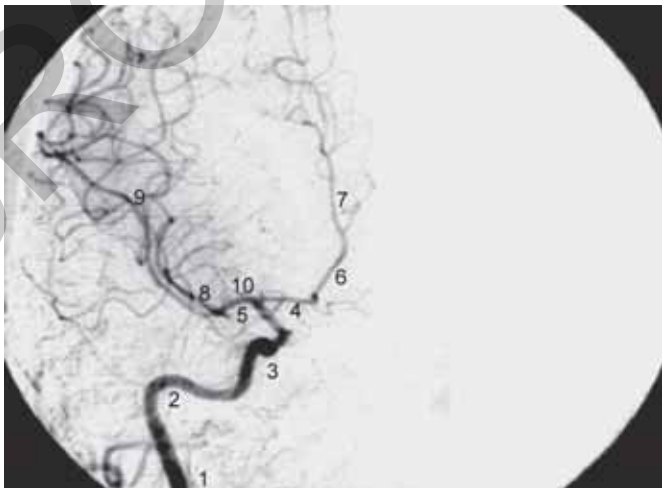

FIG. 11: Right internal carotid artery angiogram PA view. (1: Cervical segment of ICA; 2: Petrous segment of ICA; 3: Cavernous segment of ICA; 4: Anterior cerebral artery (A1); 5: Middle cerebral artery (M1); 6: Anterior cerebral artery (A2); 7: Anterior cerebral artery (A3); 8: Middle cerebral artery (M2); 9: Middle cerebral artery (M3); 10: Lenticulostriate arteries).

The two vertebral arteries (VA) arise from the respective subclavian arteries, course cephalad and enter the cranium through the foramen magnum. These unite in the posterior fossa, usually anterior to the medulla to form the basilar artery. Most of the time vertebral arteries are asymmetrical. In about 60% left vertebral artery is dominant, in 25% right can be dominant and in about 25% both vertebral artery can be symmetrical in size. Left vertebral artery can arise directly from aorta in small percentage.

The intracranial VA gives two major branches: Anterior spinal artery supplying the spinal cord and PICA on each side which supplies choroid plexus of fourth ventricle, medulla,

JAYPEE BROTHERS

cerebellar tonsils, inferior vermis and parts of cerebellar hemispheres.

Basilar artery (BA) runs anterior to pons in the prepontine cistern and terminates in the interpeduncular cistern by dividing into posterior cerebral arteries (PCAs). In prepontine cistern, it lies within the space marginated by lateral margin of clivus. Any further deviation from these boundaries is considered as dolichoectasia. In addition, the basilar artery gives off anterior inferior cerebellar artery (AICA) and superior cerebellar artery (SCA) on each side, just before bifurcation into posterior cerebral arteries. The anterior inferior cerebellar artery is the first major branch of basilar artery and most of the time (about 70%) arises as single vessel.

AICA courses posterolaterally within the CP angle cistern, whereas SCA curves around the pons and the midbrain just below the tentorial hiatus **(Figs. 13 and 14)**. The AICA supplies the VII, VIII CN, inferolateral pons, middle cerebellar peduncle and anterolateral surface of cerebellum. The SCA supplies the entire superior surface of cerebellum, vermis, deep cerebellar white matter and dentate nuclei. In addition, BA also gives off multiple short and long segment circumflex perforating branches which supply the ventral pons and rostral brainstem.

The PCAs are usually terminal branches of basilar artery but they can arise directly from supraclinoid ICA with hypertrophy of PCom and hypoplasia of ipsilateral P1 segment of PCA called as fetal PCA ***(see* Fig. 10)**. PCA on each side is divided into three major segments. Precommunicating (P1 or peduncular) segment: It extends from the origin of PCA to its junction with the PCom. The posterior thalamoperforating arteries and medial posterior choroidal artery usually arise from P1 segment. Ambient (P2) segment: It courses around the midbrain above the trochlear nerve and tentorial incisura. The lateral posterior choroidal artery and thalamogeniculate arteries arise from the P2 segment.

Quadrigeminal (P3) segment: It runs behind the midbrain in the quadrigeminal plate cistern. The major branches of P3 segment are inferior temporal arteries, parieto-occipital artery, calcarine artery and posterior pericallosal arteries which supply the occipital lobe and posterior part of parietal lobe **(Figs. 13A and B)**.

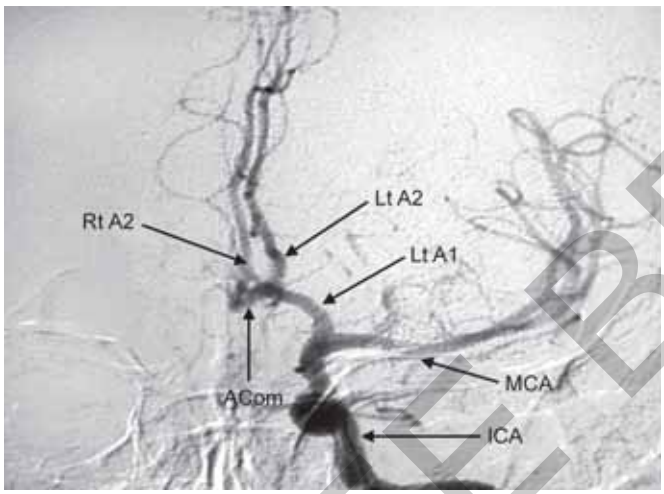

FIG. 12: Left ICA angiogram frontal view revealing ICA bifurcation, MCA, ACA segments and ACom (as annotated).

Venous Anatomy (Fig. 14)

The cerebral venous system is composed of two components, the dural venous sinuses and the cerebral veins.

Dural Sinuses

Superior sagittal sinus (SSS): It is situated in the midline and typically originates near the crista galli anteriorly and extends posteriorly to its confluence with the straight and lateral sinuses at the torcula.

Inferior sagittal sinus is situated in the inferior free margin of the falx cerebri and joins the vein of Galen to form the straight sinus.

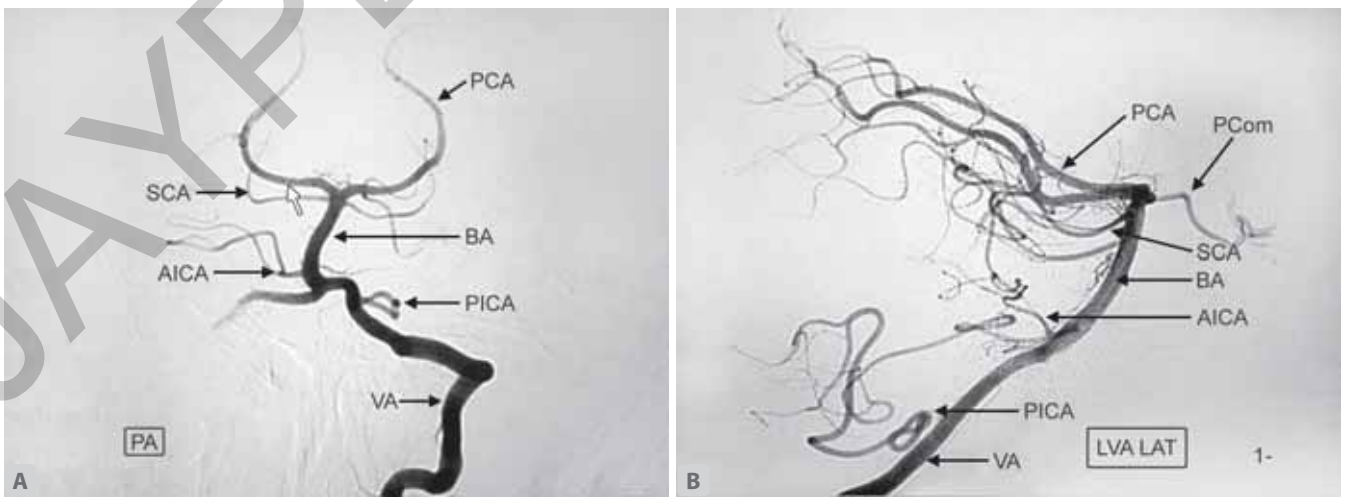

FIGS. 13A AND B: Posterior circulation frontal and lateral view showing the major arteries and their branches. (VA: vertebral artery; BA: basilar artery; PICA: posterior inferior cerebellar artery; AICA: Anterior inferior cerebellar artery; SCA: superior cerebellar artery; PCA: posterior cerebral artery; PCom: posterior communicating artery)

JAYPEE BROTHERS

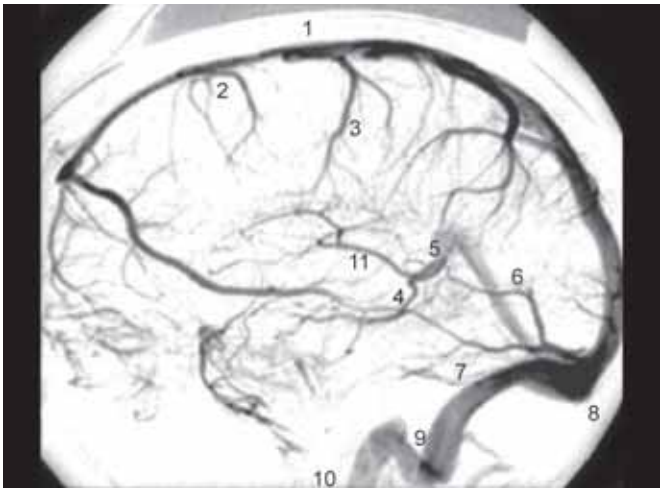

FIG. 14: Right internal carotid angiogram venous phase (lateral view). 1: Superior sagittal sinus; 2: Superior cerebral veins; 3: Vein of Trolard; 4: Basal vein of Rosenthal; 5: Vein of Galen; 6: Straight sinus; 7: Transverse sinus; 8: Torcular herophili; 9: Sigmoid sinus; 10: Internal jugular vein; 11: Internal cerebral vein).

Straight sinus courses backwards to unite with the SSS at the torcular herophili.

Transverse and occipital sinuses: The torcular herophili divides into the transverse (lateral) and occipital sinuses. The transverse sinuses course laterally around the tentorial attachment to form the sigmoid sinuses and drain into the internal jugular veins on either side. The occipital sinus is rudimentary.

Cavernous sinuses: The cavernous sinuses are the largest venous sinuses located in the parasellar region. Its major tributaries are superior and inferior ophthalmic veins. The ICA and 3rd, 4th, 6th, ophthalmic and maxillary divisions of 5th cranial nerves course within each sinus. Both cavernous sinuses communicate with each other, preclival venous plexus, sigmoid sinuses, and jugular bulb (through superior and inferior petrosal sinuses).

Cerebral Veins

These are divided into superficial (cortical) veins and deep veins.

Superficial cortical veins: These are variable in number and enter the SSS near the vertex. The larger veins which may be identified are superficial middle cerebral vein which runs along the sylvian fissure, vein of Trolard which courses from sylvian fissure to SSS and vein of Labbe which courses from sylvian fissure to the transverse sinus.

Deep cerebral veins: The medullary veins originate 1–2 cm below the cortex and course centrally toward subependymal veins which surround the lateral ventricles. The thalamostriate vein and septal vein join near the foramen of Monro to form the internal cerebral vein (ICV). The two ICVs and basal veins of Rosenthal (BVR) join to form the vein of Galen which runs under the splenium of corpus callosum and unites with the inferior sagittal sinus to form the straight sinus which joins the SSS at the torcula.

The major veins draining the posterior fossa are anterior pontomesencephalic vein, precentral cerebellar vein, superior and inferior vermian veins and hemispheric veins.

CONCLUSION

The above chapter was a brief review of the basic anatomy and techniques for cerebral angiography. DSA is the gold standard for detection of vascular pathologies in the brain. Despite its invasive nature and the recent advances in CT, MR technology its importance has not diminished in the current clinical scenario.

REFERENCES

1. Doby T. Cerebral angiography and Egas Moniz. Am J Roentgenol. 1992;159(2):364-4.
2. Wojak JC, Abruzzo TA, Bello JA, et al. Quality Improvement Guidelines for Adult Diagnostic Cervicocerebral Angiography: Update Cooperative Study between the Society of Interventional Radiology (SIR), American Society of Neuroradiology (ASNR), and Society of NeuroInterventional Surgery (SNIS). J Vasc Interv Radiol. 2015;26(11):1596-608.
3. Ahn SH, Prince EA, Dubel GJ. Basic neuroangiography: review of technique and perioperative patient care. Semin Interv Radiol. 2013;30(3):225-33.
4. Bangalore S, Bhatt DL. Femoral arterial access and closure. Circulation. 2011;124(5):e147-56.
5. Kaufmann TJ, Huston J, Mandrekar JN, et al. Complications of diagnostic cerebral angiography: evaluation of 19826 consecutive patients. Radiology. 2007;243(3):812-9.
6. Bouthillier A, van Loveren HR, Keller JT. Segments of the internal carotid artery: a new classification. Neurosurgery. 1996;38(3):425-32; discussion 432-3.

JAYPEE BROTHERS

for detailed information on radiology books, visit our website www.jaypeebrothers.com, for detailed information on radiology books, visit

AIIMS-MAMC-PGI's Comprehensive Textbook of DIAGNOSTIC RADIOLOGY

Volume 1 of *AIIMS-MAMC-PGI's Comprehensive Textbook of Diagnostic Radiology* is a combination of two most important topics, Genitourinary Imaging & Advances in Imaging Technology. The recent technical advances in the field of radiology are progressing at a fabulous pace, making it fundamental for each radiologist to remain side by side with the most recent advancements. The technological advances have helped in taking the subject of radiology to a whole new level which has literally revolutionized the treatment of many pathologies.

Key Features

- Beneficial to residents, fellows of radiology, and practicing radiologists in their day-to-day work.
- Detailed content covering tremendous conditions, in this manner giving the reader a chunk of wealthy information of the subject.
- Most up-to-date information covering a wide range of maladies.
- Integrates fundamental concepts and updated logical as well as medical-related information of radiology.
- Includes high-quality figures, tables, flowcharts, and photos to make strides in the learning of the reader.
- Focuses on research by accentuating research articles from famous professionals.



Arun Kumar Gupta



Anju Garg



Manavjit Singh Sandhu

Printed in India

Available at all medical bookstores or buy online at www.jaypeebrothers.com

JAYPEE BROTHERS
Medical Publishers (P) Ltd.
EMCA House, 23/23-B, Ansari Road, Daryaganj, New Delhi - 110 002, INDIA
www.jaypeebrothers.com

Join us on facebook.com/JaypeeMedicalPublishers

Shelving Recommendation
RADIOLOGY

ISBN 978-93-90595-55-6

9 789390 595556