eebrothers.com, for detailed information on dermatology books, visit our website www.jaypeebrothers.com, for detailed information on dermatology books

Under the Aegis of IADVL Academy

IADVL Atlas of DERMOSCOPY





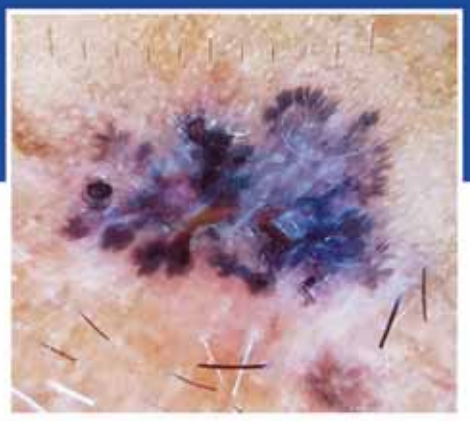

Editor-in-Chief
Balachandra S Ankad

Associate Editor
Yasmeen J Bhat

Assistant Editor
Kinjal D Rambhia

Foreword
Enzo Errichetti

JAYPEE

CONTENTS

1. **Introduction to Dermoscopy** 1
Smitha Prabhu S, Sanjeev Gupta, Shishira R Jartarkar

2. **Basic Principles of Dermoscopy** 6
Shekhar Neema, Sharmila Patil, Devayani Pol

3. **Parts and Types of Dermoscopes** 19
Shital Poojary, Atul Bothra

4. **Dermoscopic-Histopathological Correlation** 25
Biswanath Behera, Kinjal D Rambhia, Tejas Vishwanath

5. **Papulosquamous Disorders** 37
Sunanda Mahajan, Vidya Kharkar, Sushrut Save, Muhammed Razmi T, Tishya Singh

6. **Granulomatous Disorders** 68
Vinay Keshavamurthy, Balachandra S Ankad, Soumil Khare

7. **Infectious Diseases** 85
Manas Chatterjee, Kinjal D Rambhia, Debjit Kar

8. **Hyperpigmented Dermatoses** 102
Niti Khunger, Anuradha Bishnoi, Anuradha Jindal, Aswath Rajan

9. **Hypopigmentary Disorders** 127
Nirmal B, Vishal Gupta, Savitha L Beergouder, Ashwini PK

10. **Facial Dermatoses** 140
Shagufta Rather, Mansi Kansal

11. **Connective Tissue Disorders** 152
Kumudhini Subramanian, Shazia Jeelani

12. **Erythemas** 160
Malcom Noronha, Dilip Kumar NR

13. **Benign Tumors** 165
Balachandra S Ankad, Tejinder Kaur, Priyanka Jaju

JAYPEE BROTHERS

14. Premalignant and Malignant Tumors 184
Yasmeen J Bhat, Usha N Khemani, Dincy Peter CV

15. Nevi and Nevoid Disorders 202
Kinjal D Rambhia, Balachandra S Ankad, Yasmeen J Bhat

16. Trichoscopy 213
Part 1: Noncicatricial Alopecia *213*
Rachita Dhurat, Samipa S Mukherjee, Harshit Ranpara
Part 2: Cicatricial Alopecias *223*
Yasmeen J Bhat, Vrutika Hasmukh Shah

17. Onychoscopy 232
Chander Grover, Dipali Rathod

18. Miscellaneous Uses of Dermoscopy 245
Ishmeet Kaur, Faizan Younus Shah, Suman Patra

19. Oral Mucoscopy 252
Abhijeet Kumar Jha, Deepak Jakhar

Index **259**

JAYPEE BROTHERS

14 CHAPTER

Premalignant and Malignant Tumors

Yasmeen J Bhat, Usha N Khemani, Dincy Peter CV

JAYPEE BROTHERS

INTRODUCTION

Dermoscopy is a noninvasive tool which helps in the early diagnosis of premalignant and malignant tumors and to differentiate them from benign tumors of the skin.

PREMALIGNANT LESIONS OF THE SKIN

Actinic Keratosis

Clinical Features

Actinic keratosis (AK) is an ultraviolet light induced most common premalignant lesion, 0.1–10% may subsequently progress to cutaneous squamous cell carcinoma.[1] Clinically, AK appears as erythematous, skin-colored or pigmented, scaly lesions with a rough, sandpaper-like texture, often easier to feel than to see (**Fig. 1A, Fig. 2A**, and **Fig. 3A**).

Dermoscopic Features

The features of nonpigmented AKs are graded as I–IV: I—red pseudonetwork; II—strawberry pattern; III—structureless, white to yellow areas, keratotic follicular openings; and IV—structureless, white to yellow keratotic areas.[2] The "strawberry pattern" is characterized by background erythema with unfocused, large, straight or wavy vessels located between hair follicles associated with prominent follicular openings surrounded by a white halo (**Figs. 1B** and **C**).[3] In skin of color, the vessels may not be prominent hence the typical strawberry pattern cannot be seen. Pigmented AKs demonstrate slate gray to brown dots and globules around follicular ostia, annular granular

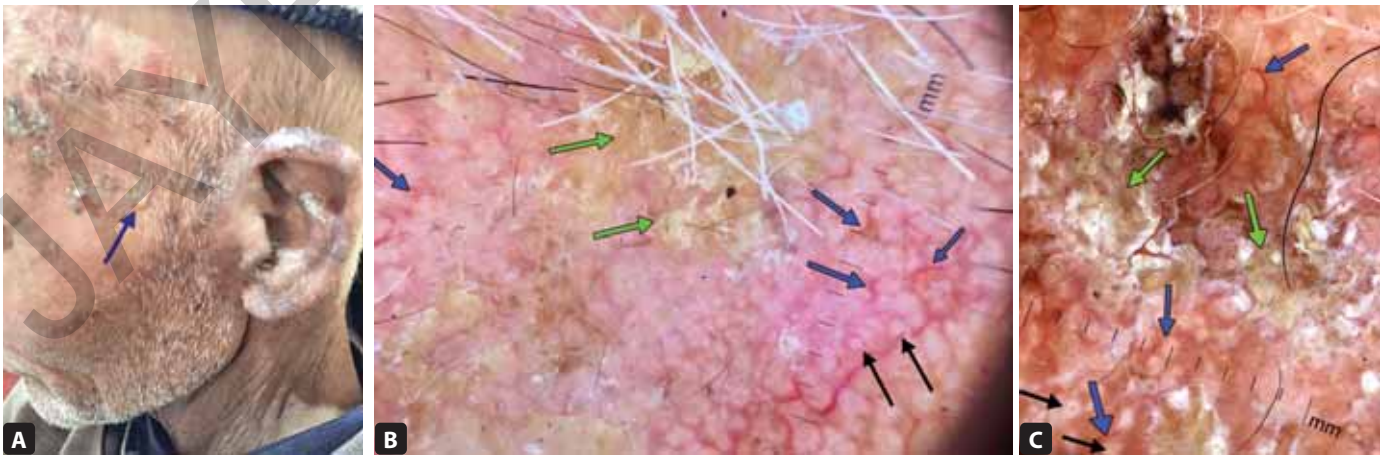

FIGS. 1A TO C: (A) Clinical image of actinic keratosis (blue arrow) on the face; (B and C) Dermoscopy showing scales and crusts on the surface (green arrows), rosettes and white circles (black arrows), perifollicular dilated unfocused vessels (blue arrows) (polarized, DermLite DL3N, 10×).

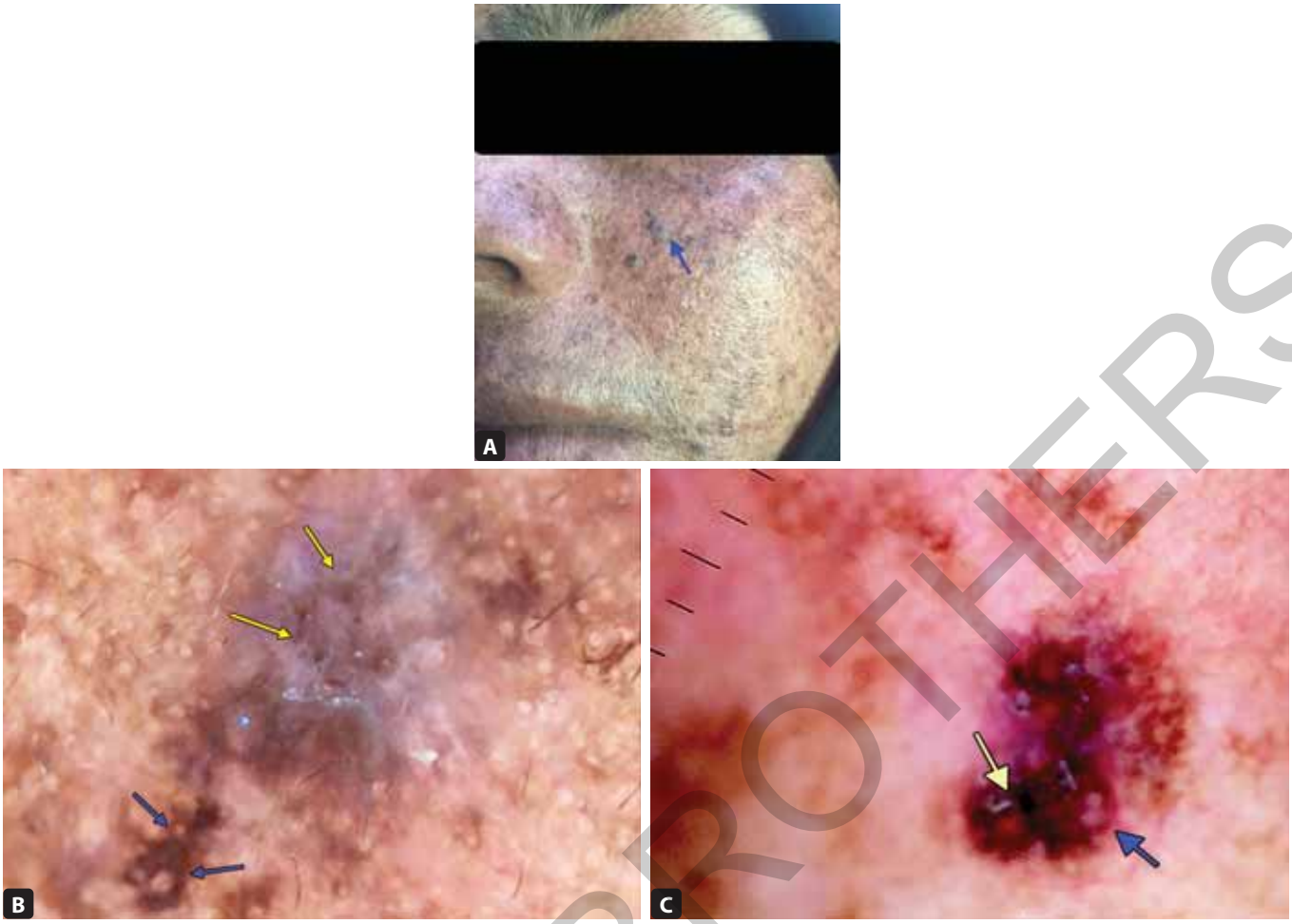

FIGS. 2A TO C: (A) Clinical image of actinic keratosis showing diffuse freckling with multiple erythematous to hyperpigmented macules over face. Blue arrow shows the lesion scoped; (B) Discrete whitish veil (yellow arrows), pigmented pseudonetwork with asymmetric dots and faint coiled vessels around the dilated follicles (blue arrows) (polarized, DermLite DL3N, 10×); (C) Pigmented pseudonetwork with asymmetric pigmented clods around dilated hair follicles (yellow arrow) with vessels surrounding them (blue arrow). Erythematous background intermingled with white to yellow, keratotic, and enlarged follicular openings giving strawberry appearance (polarized, DermLite DL3N, 10×).

and rhomboid structures, jelly sign, star-like appearance in periphery (**Figs. 2B** and **C**).[4] The follicles may have inner gray halo, white circle sign, rosettes, double white clods, dermoscopic horn (**Figs. 3B** to **E**).[5]

Key Points

- Strawberry pattern
- Rosettes
- Slate gray to brown dots and globules around follicular ostia

Bowen's Disease

Clinical Features

Bowen's disease (BD), a squamous cell carcinoma in situ with a 3–5% risk of developing into invasive squamous cell carcinoma, presents clinically as asymptomatic, slowly enlarging, erythematous, scaly plaques which may become hyperkeratotic, crusted, or ulcerated (**Fig. 4A, Fig. 5A**, and **Fig. 6A**).

Dermoscopic Features

It typically demonstrates glomerular and dot vessels grouped in clusters, surrounded by a white halo (sign of keratinization) and surface scales.[6] Pigmented BD shows brown globules or linear array of black dots regularly packed in a patchy distribution (melanophages in the dermoepidermal junction) and also gray to brown homogeneous pigmentation or brown structureless areas (acanthosis), white rosettes, double edge sign (two parallel pigmented edges at the periphery) (**Figs. 4B** and **C, Fig. 5B**, and **Figs. 6B** and **C**).[7,8]

JAYPEE BROTHERS

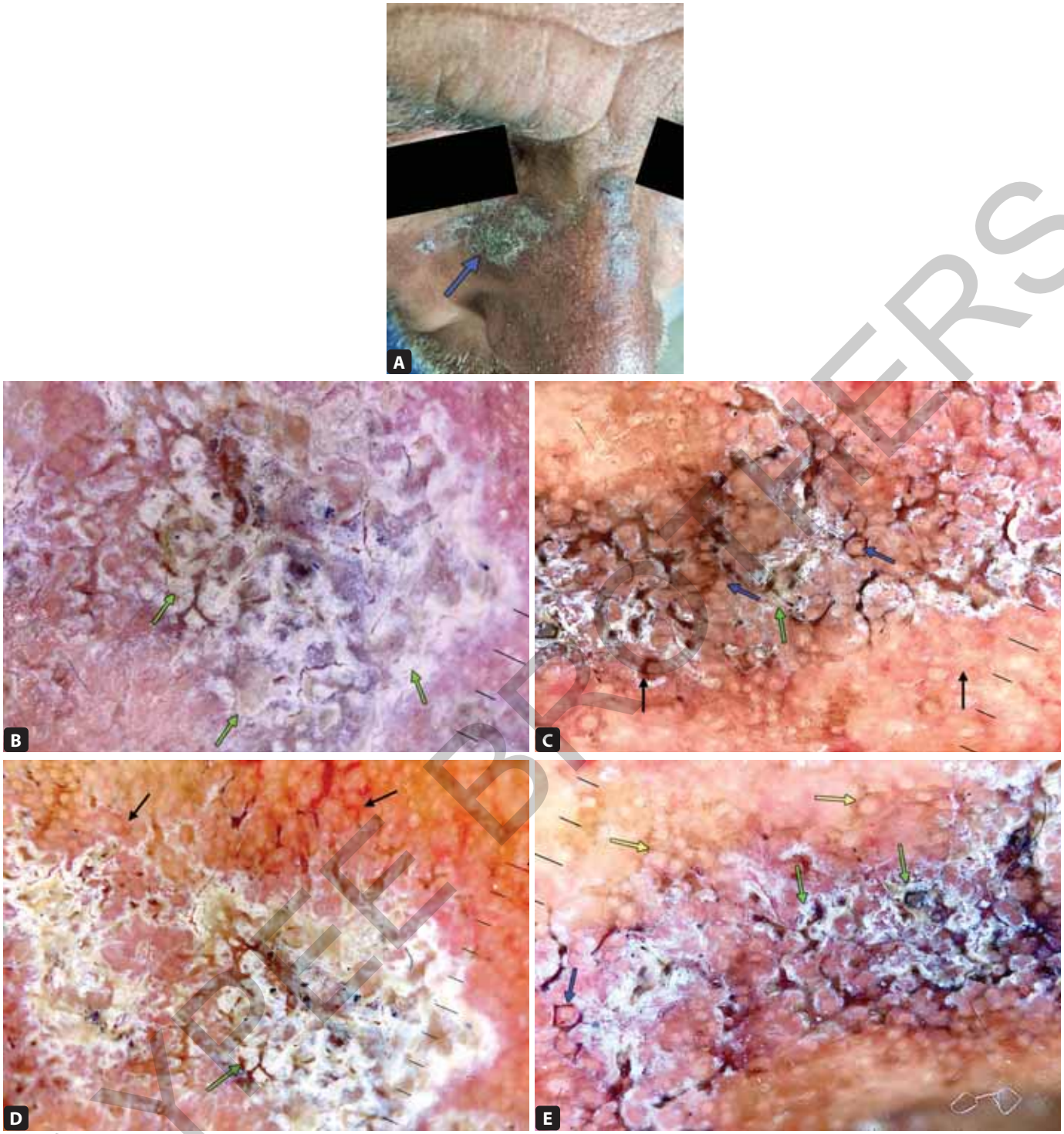

FIGS. 3A TO E: (A) Actinic keratosis on face (blue arrow); (B to E) Scales and crusts on the surface (green arrows), rosettes and white circles (blue arrows), perifollicular dilated unfocused vessels (black arrows), annular granular dots (yellow arrows) (polarized, DermLite DL3N, 10×).

JAYPEE BROTHERS

Key Points

- Glomerular and dot vessels grouped in clusters
- White halo (sign of keratinization) and surface scales
- White rosettes
- Gray to brown homogeneous pigmentation or brown structureless areas

Keratoacanthoma

Clinical Features

Keratoacanthoma (KA) is a cutaneous squamoproliferative tumor with the potential for spontaneous resolution and needs to be treated due to its resemblance to cutaneous squamous cell carcinoma (**Fig. 7A** and **Fig. 8A**).

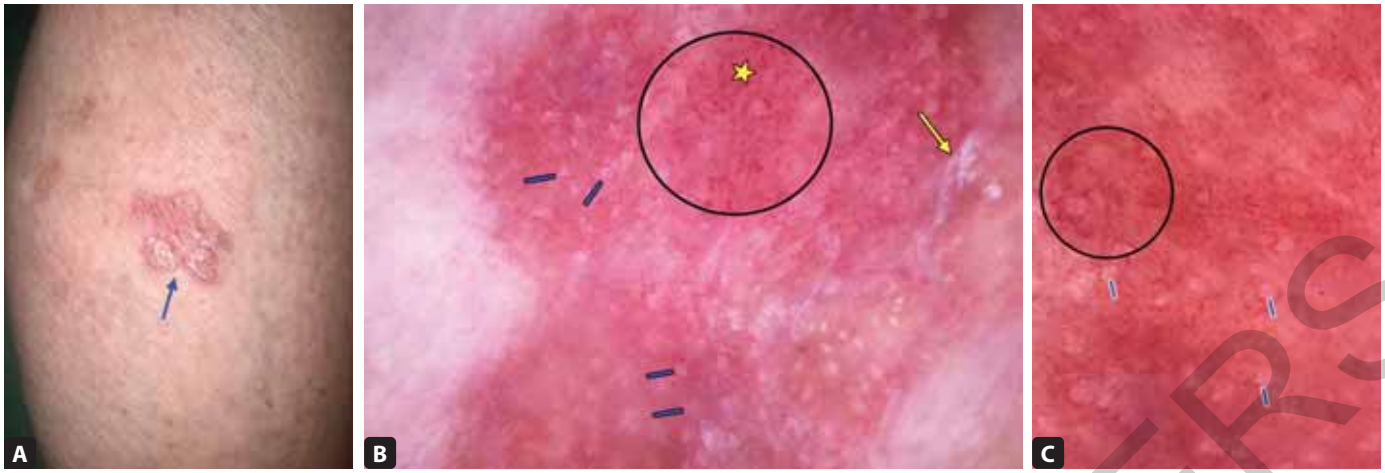

FIGS. 4A TO C: (A) Clinical image of Bowen's disease on leg; (B and C) Clusters of red dots and glomerular capillaries (black circle, yellow star), white rosettes (blue lines), white surface scales (yellow arrow) (polarized, DermLite DL3N, 10×).

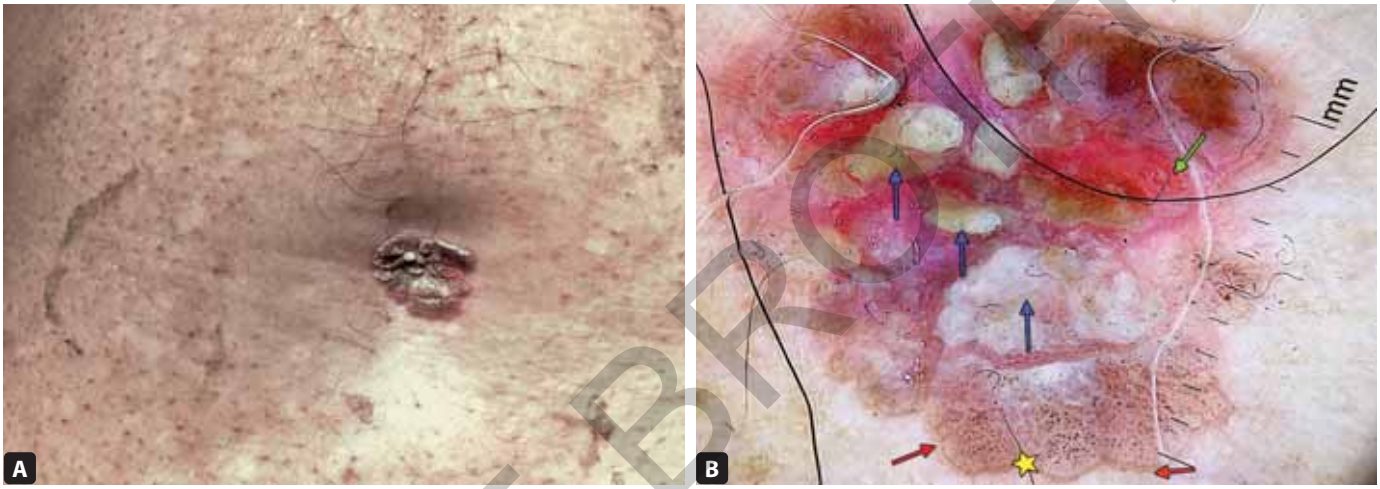

FIGS. 5A AND B: (A) Pigmented Bowen's disease on the abdomen; (B) Pigmented dots (yellow star), two parallel pigmented edges at the periphery (red arrows), whitish-brown structureless areas (blue arrows), and adherent fabric sign (green arrow) (polarized, DermLite DL3N, 10×).

Dermoscopic Features

It reveals concentric circles of central crater with blood spots, an ivory whitish area, adjacent peripheral vessels, dotted vessels, most outer circle of whitish halo. Surface scales and white structureless zones can be seen.[9,10] Keratin and white circles differ from other amelanotic tumors like amelanotic melanoma, AK, and BD. White circles are due to acanthosis and hypergranulosis of infundibular epidermis (**Figs. 7B** and **C**, and **Fig. 8B**).

Key Points

- Central crater with blood spots
- Surface scales with white structureless zones
- Whitish halos
- Peripheral vessels—short linear, curved, or dotted

MALIGNANT LESIONS OF THE SKIN

Squamous Cell Carcinoma

Clinical Features

Cutaneous squamous cell carcinoma is a common type of keratinocytic or nonmelanoma skin cancer with cumulative ultraviolet ray exposure being the main risk factor, involving face, neck, dorsum of hands, lower lip, and extremities. The typical lesion is an indurated, firm, papulonodular, plaque-like, papillomatous or exophytic growth with ulceration (**Fig. 9A, Fig. 10A**, and **Fig. 11A**).

JAYPEE BROTHERS



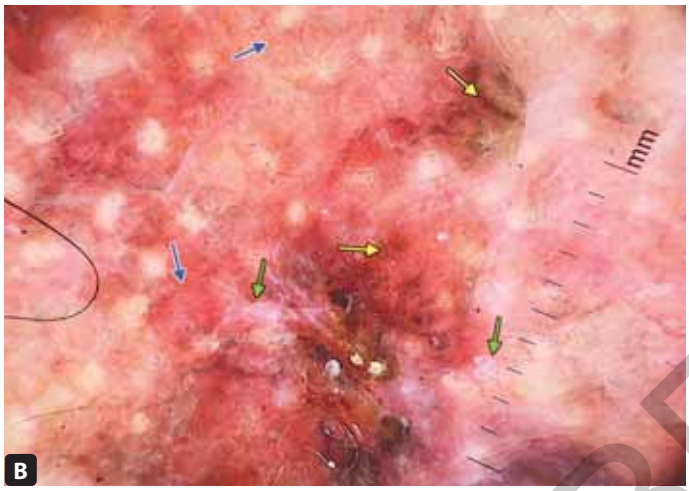

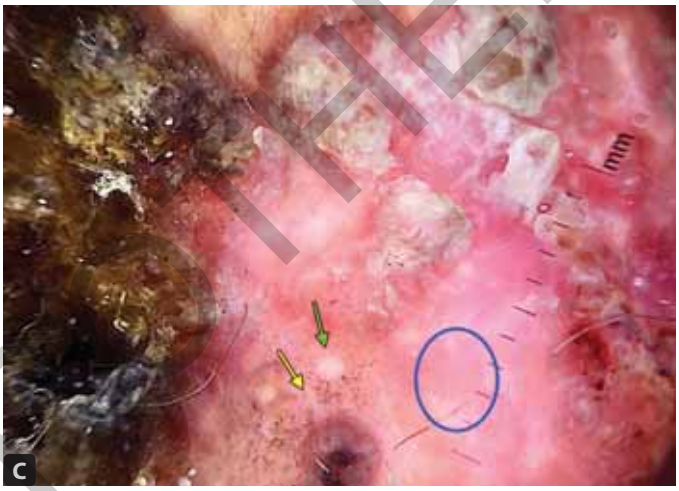

FIGS. 6A TO C: (A) Pigmented Bowen's disease on the chest; (B) Brown structureless areas (yellow arrows), clusters of glomerular capillaries (blue arrows), white scales (green arrows) (polarized, DermLite DL3N, 10×); (C) Reddish-white structureless areas (blue circle), pigmented dots (yellow arrow), nonpigmented follicles (green arrow) (polarized, DermLite DL3N, 10×).

Dermoscopic Features

Nonpigmented invasive squamous cell carcinoma frequently reveals linear, serpentine, irregular, hairpin, or dotted vessels, or combination of these vascular elements which is called as polymorphous or atypical vascular pattern. Typically, these vessels are surrounded by a whitish halo, which is a dermoscopic hallmark of all keratinizing tumors.

Pigmented invasive squamous cell carcinoma shows scales, keratin crust, keratin masses, white circles, and white structureless areas, diffuse or homogeneous blue pigmentation and/or irregularly distributed, blue-gray granular structures. A four-clover leaf pattern—"rosettes" with four bright white clods or dots arranged in two by two pattern may be seen. If ulcerated, dark-brown to black blood spots are visible. Due to pigmentation, vessels may not be appreciated, and if present are polymorphous vessels (serpentine, dotted or linear or looped, irregular or hairpin-like) with perivascular white halos.[11-14]

The dermoscopic structures differ among the clinical variants reflecting the different grades of differentiation (well differentiated, moderately differentiated or low differentiation) (**Fig. 9B, Figs. 10B** to **D**, and **Figs. 11B** and **C**).[15,16]

Key Points

- Keratin crusts or masses
- White circles/clods
- White structureless areas
- Perivascular white halos
- Polymorphous vessels

Basal Cell Carcinoma

Clinical Features

Basal cell carcinoma (BCC) is a nonmelanoma slow growing skin cancer and locally invasive. Clinical types—nodular, superficial, pigmented, morpheaform, fibroepithelioma of Pinkus, giant BCC, and subcutaneous (**Fig. 12A, Fig. 13A,** and **Fig. 14A**).[17]

JAYPEE BROTHERS



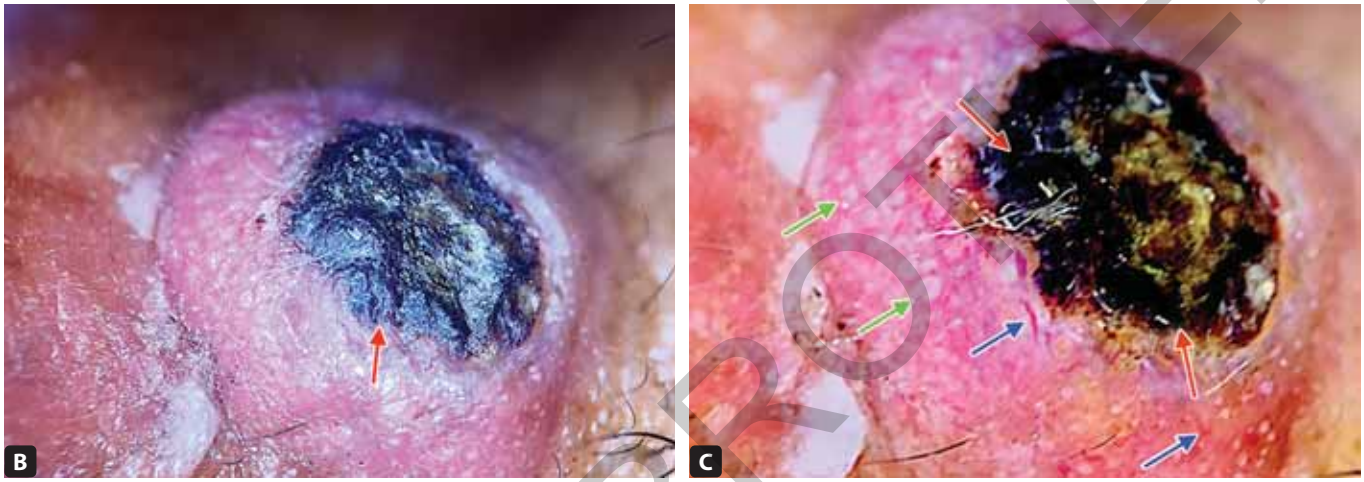

FIGS. 7A TO C: (A) Clinical image of keratoacanthoma on face; (B) Central crater with blackish areas (hemorrhage) (red arrow) (nonpolarized, DermLite DL3N, 10×); (C) Central crater with blackish areas (hemorrhage) (red arrows), whitish circles (green arrows), short linear and curved vessels (blue arrows) (polarized, DermLite DL3N, 10×).

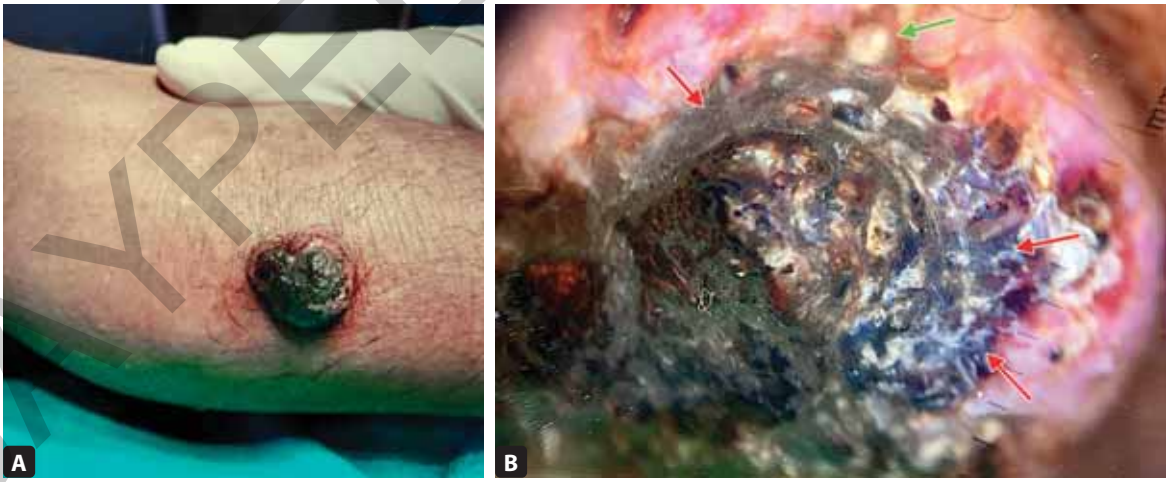

FIGS. 8A AND B: (A) Clinical image of keratoacanthoma on leg; (B) Central crater with blackish areas (hemorrhage) (red arrows), whitish circles (green arrow) (polarized, DermLite DL3N, 10×).

JAYPEE BROTHERS

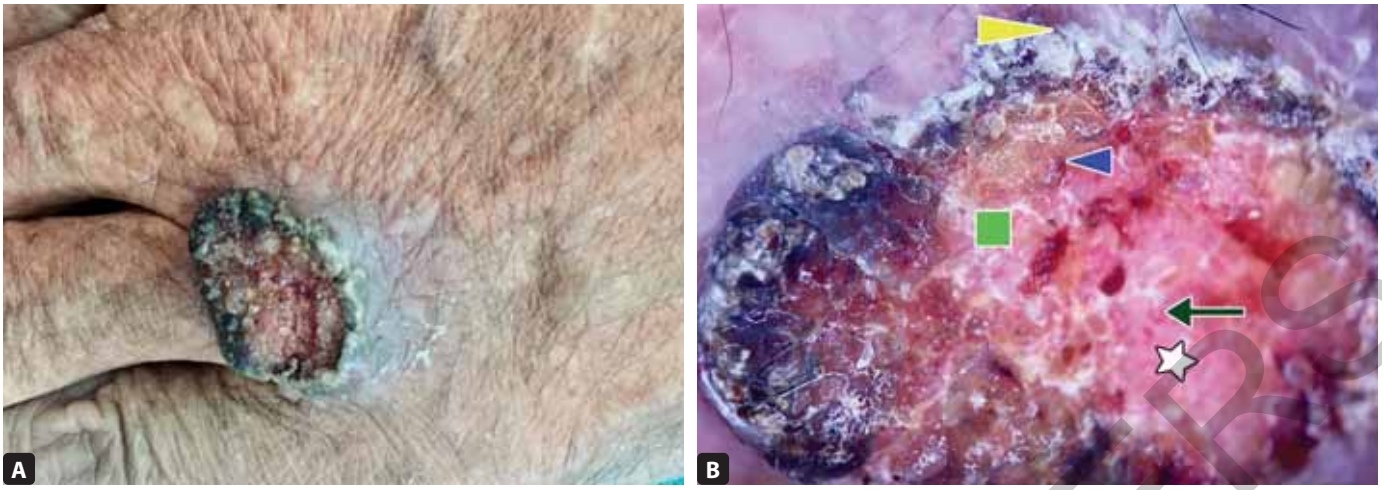

FIGS. 9A AND B: (A) Clinical image of ulcerated squamous cell carcinoma on the dorsum of the hand on photodamaged skin; (B) Dermoscopy showing keratin masses as white scales (yellow arrowhead), blood spots on keratin scale (blue arrowhead), fine white scales (green square), milky-red areas (white star) and polymorphous vessels such as coiled and glomerular (dark green arrow) (polarized, DermLite DL3N, 10×).

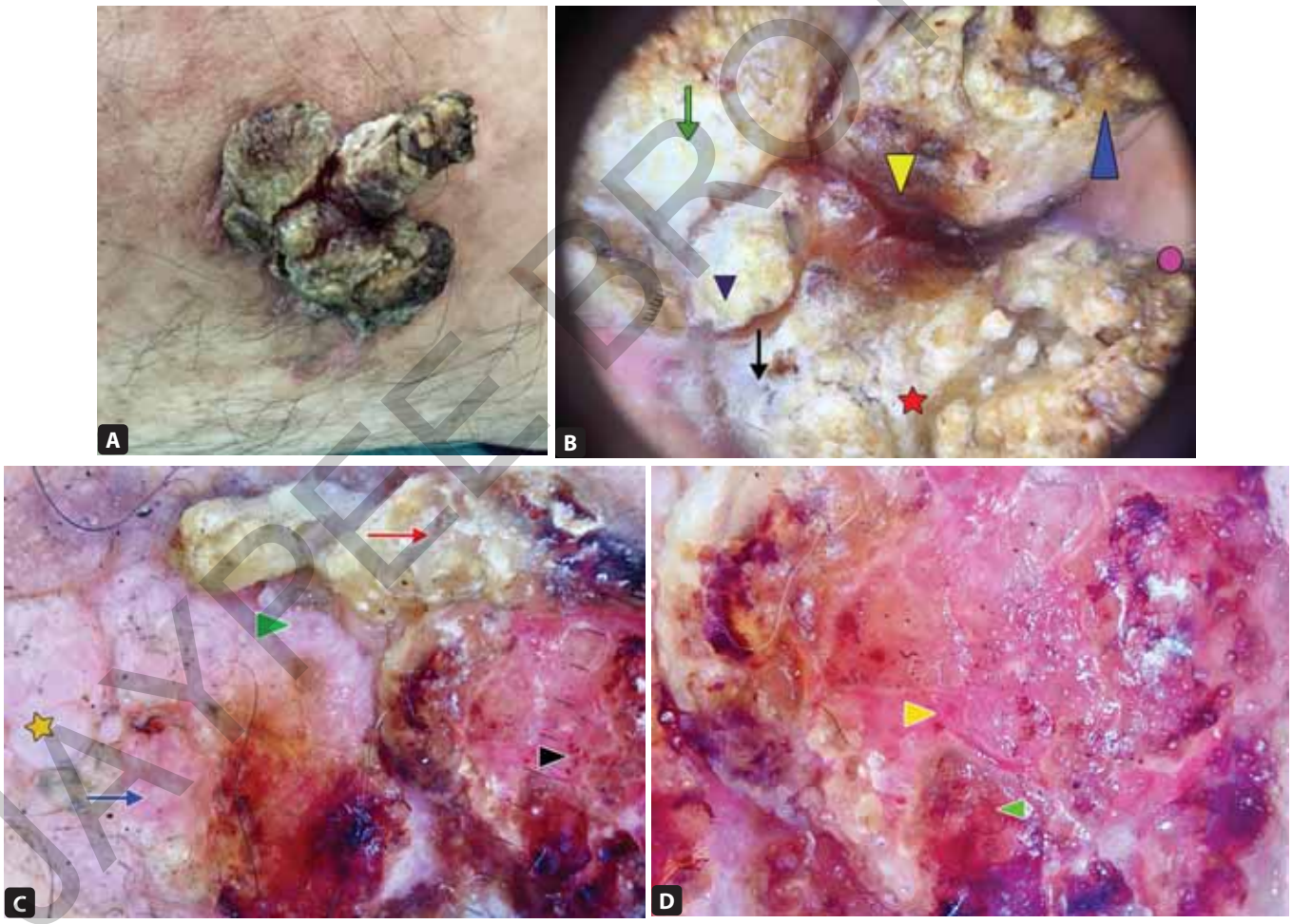

FIGS. 10A TO D: (A) Clinical image showing an exophytic squamous cell carcinoma with cutaneous horn with actinic keratosis at a distant site; (B) Dermoscopy displaying a combination color white being predominant color, white scales (green arrow), yellowish keratin with blood spots (blue arrowhead) and central hemorrhage (yellow arrowhead), white circles (purple arrowhead) and clod (red star) and brownish (pink circle) and white structureless areas (black arrow) (polarized, DermLite DL3N, 10×); (C) Dermoscopy showing yellowish keratin masses (red arrow), white circle with yellowish center (green arrowhead), perivascular white halo around vessels (blue arrow), white clod (yellow star), and polymorphous vessels (coiled, hair pin, dotted) (black arrowhead) (polarized, DermLite DL3N, 10×); (D) Dermoscopy showing polymorphous vessels coiled and glomerular (yellow and green arrowhead) (polarized, DermLite DL3N, 10×).

JAYPEE BROTHERS



FIGS. 11A TO C: (A) Clinical image showing fungating mass verrucous squamous cell carcinoma (red arrowhead) overlying the middle toe of right foot with mitten toes and anonychia; (B) Dermoscopy showing white color predominantly with polymorphous vessels such as coiled (red arrow), dotted (purple arrow) and glomerular (green arrowhead) with a perivascular white halo (black stars), white circles with center yellowish plug (blue arrowhead) and rosettes, white structureless area (orange rectangle) with hemorrhage (polarized, DermLite DL3N, 10×); (C) Dermoscopy showing polymorphous vessels (blue star) with perivascular white halo around them (red arrowhead) white clods (purple arrow), amorphous white structures (green arrow) and white structureless areas at periphery (black arrowhead) (polarized, DermLite DL3N, 10×).

Dermoscopic Features

It helps as a screening technique in doubtful lesions and in the management of the tumor, since it provides valuable diagnostic information about it and the expansion of the tumor beyond clinically visible margins.[18,19]

The concept of the signature pattern of BCC as introduced by Zalaudek et al. indicates that multiple BCCs in an individual usually display a repetitive dermatoscopic pattern (**Tables 1** and **2**).[20-23] According to the degree of dermoscopic pigmentation, lesions are categorized as:[19]

- Nonpigmented BCCs—only red and/or white structureless areas
- Lightly pigmented BCCs—pigmented areas <30% of lesion
- Pigmented BCCs—pigmented areas 30–70% of lesion
- Heavily pigmented BCCs—presence of pigmentation >70%

TABLE 1: Dermoscopic features of basal cell carcinoma.[23]

Vascular structures	Pigmented structures	Nonvascular, nonpigmented structures
Arborizing vessels Thin arborizing Short fine telangiectasias	Globules	Milky-red area
Other vessels	Blue-gray ovoid nests	Ulceration
Serpentine	Dots	Crusts
Helical	Maple leaf	Scale
Polymorphous	Spoke wheel	Erosions
Linear	Concentric globules	Blue-white veil
Looped		Shiny white structures

Source: Wozniak-Rito A, Zalaudek I, Rudnicka L. Dermoscopy of basal cell carcinoma. Clin Exp Dermatol. 2018;43:241-7.

UNCORRECTED PROOFS

for detailed information on dermatology books, visit our website www.jaypeebrothers.com, for detailed information on dermatology books, visit our websit

IADVL Atlas of DERMOSCOPY

Salient Features

- High-quality dermoscopic and clinical images.
- Differences in dermoscopic features in skin of color from fair skin types.
- Accurate markings of all dermoscopic features.
- Relevant dermoscopy and histopathology correlation.
- Coverage of almost all common dermatological conditions including hair and nail disorders.



Balachandra S Ankad, Professor and Head, Department of Dermatology, S Nijalingappa Medical College, Bagalkot, Karnataka, India, is an eminent personality working in the field of Dermatology and has over two decades of experience in the same field. His areas of expertise are dermoscopy of skin, nail, and hair. He has published more than 80 papers in various national and international journals and has written 19 chapters pertaining to dermoscopy. He has edited a book entitled "Dermoscopy-Histopathology Correlation" by Springer. He has given more than 100 presentations over various topics of his research in dermatology. He is the recipient of the famous WCD scholarship and has been a Member of Board of Directors of International Dermoscopy Society (2018–2020). He is also the Coordinator of SIG Dermoscopy, IADVL Academy (2020–2021).



Yasmeen J Bhat, Associate Professor, Department of Dermatology, Venereology, and Leprosy, Government Medical College, Srinagar, Jammu and Kashmir, India, is the recipient of International Fellowship Exchange Program award by the American College of Physicians, IADVL Presidential award, Prof G Senthamil Selvi award, and WCD 2019 scholarship. She has to her credit Fellowships in Skin cancers and Lasers, 25 chapters, 115 indexed publications, and 70 invited faculty presentations. She has been the Section Editor of IADVL Textbook of Trichology, Associate Editor of 2nd edition of IADVL Textbook of Recent Advances, past IADVL and present ACSI Academy Member, and Vice President of IADVL, Jammu and Kashmir, India. She is the Convener of SIG Dermoscopy (2020–2021), Section (Dermoscopy), Editor of IJDVL, and member of Board of Directors of International Dermoscopic Society (2021–2024) and is on the Editorial board and Reviewer of many national and international journals.



Kinjal D Rambhia, Assistant Professor, Department of Dermatology, HBT Medical College and Dr RN Cooper Hospital, Mumbai, Maharashtra, India, has a vast experience in the field of Dermatology and Diagnostic Dermatology including Dermoscopy and Dermatopathology. She has to her credit more than 50 publications and is a reviewer for several national and international journals. She has authored many chapters in various textbooks such as International Textbook of Leprosy, IADVL Textbook of Geriatric Dermatology, IADVL Textbook of Recent Advances, and Acne Scars and MCQ's in Dermatology. She is also the Assistant Editor of the Indian Journal of Drugs in Dermatology, IJDVL, Handbook of Drug Therapy in Dermatology, and editorial board member of Indian Dermatology Online Journal. She is the recipient of the Rising Star award from the World Congress of Dermatology, Milan, 2019, and scholarship award from International Summer Academy, Munich, 2017.

Printed in India

Available at all medical bookstores
or buy online at www.jaypeebrothers.com

JAYPEE BROTHERS
Medical Publishers (P) Ltd.
EMCA House, 23/23-B, Ansari Road,
Daryaganj, New Delhi - 110 002, INDIA
www.jaypeebrothers.com

Join us on facebook.com/JaypeeMedicalPublishers

Shelving Recommendation
DERMATOLOGY

ISBN 978-93-90595-64-8

9 789390 595648