medicine books, visit our website www.jaypeebrothers.com, for detailed information on medicine books

Celebrating 50 Passion, Quality and Innovation in Healthcare Publishing

Handbook on Clinical Approach to Respiratory Medicine

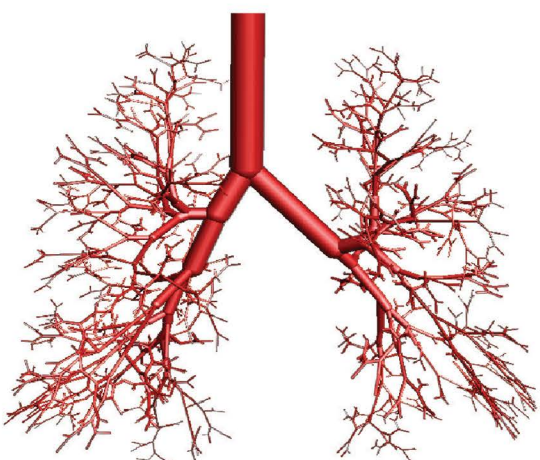

2nd Edition

K Surendra Menon
R Pajanivel

JAYPEE

Contents

1. Anatomical Principles **1**
Important Anatomical Landmarks 1

2. Symptomatology **17**
Cardinal Rule to History Taking 17
Symptoms of Respiratory Diseases 19
History Taking 32
Making Provisional Diagnosis from History Obtained 34

3. Examination of Respiratory System **37**
Vital Signs 37
General Physical Examination 38
Examination of Respiratory System 47

4. Common Investigations in Respiratory Evaluation **81**
Diagnostic Tests 81
Certain Important Tests (Not Commonly Done) 84

5. Roentgenography: "A Step-by-step Approach to Reading of Chest X-ray" **89**
Posteroanterior View 90
Anteroposterior View 91
Lateral View of X-ray (Right Lateral and Left Lateral) 91
Lateral Decubitus View 93
Lordotic View 93
Oblique View 95
Common Terms 95
Systematic Reading of Chest X-ray 96
Pitfalls of Chest X-ray Interpretation 121
Reading Chest X-rays: Tips 122

6. Management of Pulmonary Emergencies **123**
Acute Exacerbation of Bronchial Asthma 123
Acute Exacerbation of Chronic Obstructive Pulmonary Disease 130
Tension Pneumothorax 132
Hemoptysis 134
Respiratory Failure 136

7. Viva Voce Questions and Bedside Questions **139**
Viva Voce Questions 139
Clinical Examination Questions 145

Index **149**

CHAPTER 4

Common Investigations in Respiratory Evaluation

JAYPEE BROTHERS

INTRODUCTION

The main aim of supporting and relevant investigations is to confirm the diagnosis we have already made from detailed history taking and clinical examination.

At present day scenario, we have to depend more on these investigations, in case if there is medical litigation to protect ourselves. In a tertiary care center, opinion can be sought from other specialty departments, e.g., cardiothoracic surgery, ear, nose, and throat (ENT), etc. Various strains and culture methods are available in microbiology to identify various pathogens. In pathology also, various strains are used. The main investigation support is from the radiology department for confirming various diagnoses.

As medical tests are becoming exorbitantly expensive, basic and cost-effective investigations should be ordered. In future, more supportive tests may be available.

DIAGNOSTIC TESTS

- *Blood routine*—hemoglobin, total leukocyte count, differential count (especially eosinophils, lymphocytes), erythrocyte sedimentation rate (ESR), tests for human

immunodeficiency virus (HIV) (if history of high-risk behavior), and also in all presumptive tuberculosis (TB) patients.

- *Sputum collection*—by expectoration, laryngeal swabs, gastric aspiration, pharyngeal or tonsillar swabs, tracheobronchial aspiration, bronchoalveolar lavage (BAL), and induced sputum through inhaled mucolytics (if difficult to expectorate due to thick viscid sputum).
  With the sputum, following tests can be performed:
  - Acid-fast bacilli (AFB) staining—two samples; direct smear by Ziehl–Neelsen (ZN) stain, light-emitting diode (LED) microscope, cartridge-based nucleic acid amplification test (CBNAAT), and line probe assay (LPA).
  - Acid-fast bacilli culture and sensitivity—if drug resistance suspected along with the other modern techniques [e.g., polymerase chain reaction (PCR)].
  - In bacterial infections—culture and sensitivity
  - Fungal hyphae, fungal staining, and culture
  - Bronchial asthma—eosinophils, plugs, casts, creola bodies, Curschmann's spirals, and Charcot–Leyden crystals [also in allergic bronchopulmonary aspergillosis (ABPA)].
  - Asbestos bodies—asbestosis
  - Hooklets—hydatid cyst, entamoeba histolytica—hepatopulmonary amebiasis
  - Sputum malignant cytology—carcinoma bronchus
- Urine examination tests for COVID-19 (if indicated).
- *Tests for COVID-19*—commonly performed tests for antigen detection in India – Nasopharyngeal or throat swab and RT-PCR. More tests are being tried.
- X-ray of chest [preferably posteroanterior (PA) view or anteroposterior (AP), lateral, lateral decubitus, lordotic view, etc., as the condition demands].

JAYPEE BROTHERS

- Ultrasonography (USG) (thorax and abdomen)
- Fasting and postprandial blood sugar (FBS and PPBS)—preferably for all the patients above the age of 30 years.
- Paracentesis thoracis in pleural effusion (with all relevant investigations).
- Pleural biopsy
- Lymph node—fine-needle aspiration cytology (FNAC) and biopsy.
- Liver function testing (LFT)—if indicated.
- Renal function testing (RFT)—if indicated.
- Pulmonary function testing (PFT) [spirometry, diffusing capacity of the lungs for carbon monoxide (DLCO), and body plethysmography].
- Peak flow meter—measure peak expiratory flow rate.
- Electrocardiogram (ECG) and echocardiogram
- Computed tomography—high-resolution computed tomography (HRCT) or with contrast as the situation demands.
- Arterial blood gas (ABG)
- Tuberculin testing—mantoux test (indicates tuberculous infection and not the disease).
- Other diagnostic skin testing—hydatid, sarcoidosis, histoplasmosis, blastomycosis, etc.
- Allergy testing—intradermal and sublingual immunotherapy (SLIT)
- Magnetic resonance imaging (MRI)—if necessary.
- Barium swallow—in case of dysphagia, but it can be visualized in CT.
- Bronchoscopy—rigid and fiberoptic bronchoscopy: BAL, biopsy, bronchial brushing, transbronchial biopsy, and transbronchial needle aspiration.
- Endobronchial ultrasound (EBUS)
- Percutaneous or open lung biopsy

JAYPEE BROTHERS

- Immunological tests, if indicated—immunoglobulin G (IgG), immunoglobulin M (IgM), and immunoglobulin E (IgE).
- Pleuroscopy
- Video-assisted thoracoscopy (VATS)
- Mediastinoscopy (not popular now)
- Pulmonary angiography
- Ventilation-perfusion scan
- Positron emission tomography (PET) scan
- Polysomnography for sleep-related breathing disorders.
- *Inflammometry:* Fractional exhaled nitric oxide (FeNO) (bronchial asthma, cystic fibrosis, and primary ciliary dyskinetic syndromes) and exhaled breath condensate analysis.
- Transmission electron microscopy (TEM)—primary ciliary dyskinesia.

CERTAIN IMPORTANT TESTS (NOT COMMONLY DONE) (TABLE 1)

TABLE 1: Certain important tests (Not commonly done).

Suspected condition	Suggested test
Pulmonary embolism	D-dimer
Inherited emphysema	α1-antitrypsin
Cystic fibrosis	Specific genetic tests
Lung cancer	Tumor markers (CEA and SCC)
Malignant mesothelioma (mesothelin and fibrillin)	Tumor markers
Pneumonia	Serum procalcitonin
Latent tuberculosis infection	IGRAs
Sarcoidosis	SACE and serum calcium levels
Hypersensitive pneumonitis	Specific precipitating antibodies

Continued

JAYPEE BROTHERS

Continued

Suspected condition	Suggested test
Connective tissue disorders	Rheumatoid factor, ANA, etc.
Unexplained dyspnea (to rule out cardiac cause)	NT-proBNP—increase in heart failure.

(ANA: antinuclear antibody; CEA: carcinoembryonic antigen; SACE: serum angiotensin-converting enzyme; SCC: squamous cell carcinoma; NT- proBNP: N-terminal pro-brain natriuretic peptide; IGRAs: Interferon-gamma release assays)

Now that we have done the physical examination, we will get back to the three sample case studies illustrated in Chapter 2 and try to come to a diagnosis.

CASE STUDY 1

General Examination

- On general examination, there was no pallor, icterus, lymphadenopathy, and pedal edema. Clubbing grade 2 was present and body mass index (BMI) was 18 kg/m^2.
- *Upper respiratory tract:* Normal
- *Lower respiratory tract:* Trachea and apex beat appear shifted showing mediastinal shift on inspection.
- *Palpation:* Movements reduced with reduction in chest expansion in the right infraclavicular area. Vocal fremitus was increased in the above area.
- *Percussion:* Note impaired.
- *Auscultation:* Bronchial breathing was present with coarse crackles with absence of wheeze. Vocal resonance was increased.

Provisional diagnosis from history and examination can be:

- Pulmonary tuberculosis (can be reactivation or fibrosis of right upper lobe).

JAYPEE BROTHERS

- Bronchogenic carcinoma (smoker and scar carcinoma).
- Bronchiectasis

To come to a final diagnosis, following investigations can be done:

- Blood—hemoglobin, total count—differential blood count, and ESR.
- Fasting blood sugar and PPBS (considering the age factor and suspicion of pulmonary TB).
- Sputum for AFB for 2 days.
- Sputum culture and sensitivity (especially in bronchiectasis).
- X-ray of chest—posterior-anterior view.
- High-resolution computed tomography to rule out bronchiectasis and malignancy.
- Fiberoptic bronchoscopy in case of malignancy.

If sputum is positive for AFB, then invasive or expensive investigations can be avoided.

CASE STUDY 2

- *On general examination:* Clubbing was present (grade 3) and BMI was 22 kg/m^2.
- *Inspection:* Tracheal shift to left and apex beat shifted 2 inches lateral to the midclavicular line toward the axilla.
- *On palpation:* Increased vocal fremitus on the left supraclavicular and infraclavicular areas.
- *Percussion:* Impaired note in the above areas.
- *Auscultation:* Bronchial breathing in the above areas, but normal breath sounds in other areas. Crackles were heard over the left supraclavicular and infraclavicular areas which are conducted to the mouth.

All the earlier mentioned differential diagnoses (page no. 35) may be applicable in this case. So, the battery of laboratory investigations may be extensive.

JAYPEE BROTHERS

Investigations

- Blood—hemoglobin, total count—differential blood count, and ESR.
- Fasting blood sugar and PPBS (considering the age factor and suspicion of pulmonary TB).
- Sputum for AFB for 2 days (if sputum is negative for AFB), the following tests to be done:
  - Sputum culture and sensitivity (especially in bronchiectasis).
- X-ray of chest—posterior-anterior view
- Liver function test
- High-resolution computed tomography to rule out bronchiectasis and malignancy.
- Spirometry
- Fiberoptic bronchoscopy in case of malignancy.

CASE STUDY 3

- Patient was tachypneic with accessory muscles acting, but cooperative in giving detailed history. No cyanosis or dehydration and oxygen saturation (SpO_2) was 96%.
- *Percussion:* Bilateral hyper-resonant note.
- *Auscultation:* Normal breath sounds with bilateral wheeze. Probable diagnosis—acute severe asthma probably exacerbated by secondary infection.
- Patient has to be nebulized immediately and intravenous (IV) steroids may be given (detailed treatment of asthma is given later).

When the patient improves, following investigations should be done:

- X-ray of chest—posterior-anterior view
- Blood—hemoglobin, total count—differential blood count, and ESR.

JAYPEE BROTHERS

- Fasting blood sugar and PPBS (family history of diabetes mellitus and probably prolonged steroid intake).
- Sputum for AFB for 2 days.
- Sputum culture and sensitivity
- Once the patient settles, spirometry can be done, if sputum for AFB is negative.

JAYPEE BROTHERS

for detailed information on medicine books, visit our website www.jaypeebrothers.com, for detailed info

Handbook on Clinical Approach to

Respiratory Medicine

Salient Features

- A handy book on the subject
- Presents a systematic approach toward the patients of respiratory diseases
- Deals with proper history taking, examination and investigation, and management
- Includes appropriate photographs demonstrating clinical signs to make the text easy to understand
- An exclusive, well illustrated chapter on approach to interpretation of chest X-ray.
- Comprehensive list of most frequently repeated questions in clinical examinations
- Useful for undergraduate and postgraduate students of pulmonary medicine and general medicine, interns, general practitioners, and paramedics.

K Surendra Menon MD is a Former Professor and Head, Department of Pulmonary Medicine at Medical Education Service, Government of Kerala. He is an experienced postgraduate examiner to various universities across India, has published research papers in Various National and International Journals. He is also a speaker/chairperson for various national and regional conferences and takes active part in conducting CMEs and workshops.

R Pajanivel MD FRCP is a Professor and Head, Department of Pulmonary Medicine, Mahatma Gandhi Medical College and Research Institute (a constituent college of Sri Balaji Vidyapeeth), Puducherry, India. He has more than 10 years of experience in teaching undergraduates and postgraduates and as a Guide to postgraduates in pulmonary medicine and PhD students. He is the Chairperson of the South Zone 2 Task Force under National TB Elimination programme (NTEP) and also the Chairperson of the Puducherry State NTEP Operational Research Committee.

Printed in India

Available at all medical bookstores
or buy online at www.jaypeebrothers.com



JAYPEE BROTHERS
Medical Publishers (P) Ltd.
EMCA House, 23/23-B, Ansari Road,
Daryaganj, New Delhi - 110 002, INDIA
www.jaypeebrothers.com

Join us on facebook.com/JaypeeMedicalPublishers

Shelving Recommendation
MEDICINE

