ormation on dermatology books, visit our website www.jaypeebrothers.com, for detailed information on dermatology books, visit our website www.jaypeebrothers.com

Complimentary Online Access to e-book and Videos

ACS(I)

nation on dermatology books, visit our website www.jaypeebrothers.com, for detailed information on dermatology books, visit our website www.jaypeebrothers.com

Complimentary Online Access to e-book and Videos

ACS(I)

Textbook of Cutaneous & Aesthetic Surgery

3rd Edition

Volume One



Editor-in-Chief
Manas Chatterjee

Associate Editor
Biju Vasudevan

Emeritus Editor
Mysore Venkataram

JAYPEE

e Two

am

JAYPEE

Contents

Volume 1

Section 1: Basic Principles of Cutaneous Surgery

1. **Skin: Basic Aspects** 3
   Shashikumar BM, Savitha AS
2. **Applied Anatomy In Dermatosurgery** 10
   Madura C, AP Balaji, Aakash Gupta, Sonal Jain
3. **Applied Advanced Surgical Anatomy of Face** 45
   Mukta Sachdev, Suraj Sachidanand, Dinkar Sreekumar
4. **Wound Healing and Wound Management** 59
   Manas Chatterjee, GR Rajput, CR Srinivas, C Shanmuga Sekar
5. **Bandages in Dermatosurgery** 81
   Harish Prasad BR, Ruchi Hemdani
6. **Dermatosurgical Instruments** 94
   Anirudha Gulanikar, Ankan Gupta
7. **Wound Closure Materials and Techniques in Dermatosurgery** 108
   Govind S Mittal, Mysore Venkataram, Aneesh Kunnath Parambath
8. **Setting Up a Dermatosurgery Unit** 137
   HM Omprakash
9. **Disinfection and Sterilization** 147
   Uday Kelkar, Somodyuti Chandra
10. **Universal Precautions for a Dermatosurgeon** 165
    Yogesh S Marfatia, Smriti Naswa
11. **Topical Anesthesia** 189
    Gautam K Singh
12. **Infiltration Anesthesia** 193
    Sudarshan R, KC Nischal
13. **Tumescent Local Anesthesia** 208
    Mysore Venkataram, Aniketh Venkataram
14. **Nerve Blocks in Dermatosurgery and Aesthetic Procedures** 214
    Savitha AS
15. **Hemostasis in Dermatologic Surgery** 237
    T Salim
16. **Dermatosurgical Emergencies and Resuscitation** 248
    Murali Chakravarthy, Madura C
17. **Pharmacology of Analgesic and Anxiolytic Drugs Used in Dermatosurgery** 258
    Shyamanta Barua, Roshni Singh

Section 2: Standard Surgical Techniques

18. **Simple Excisions** 269
Vinay Saraf, Ragunatha S

19. **Skin Biopsy and Mole Surgery** 282
Dhanashree S Bhide

20. **Surgical Management of Cutaneous Cysts and Lipomas** 300
Vinay Saraf, Ragunatha S

21. **Keloids and Hypertrophic Scars** 308
Somesh Gupta

22. **Scar Revision** 329
R Raghunatha Reddy, Shashikumar BM, Savitha AS

23. **Flap Surgeries: A Dermatologist's Perspective** 345
Biju Vasudevan, Divya Gorur, Shilpa K

24. **Flaps for Facial Reconstruction** 352
Chintan Subhash Gujarathi, Vishwanath Jigjinni

25. **Surgical Dermabrasion and Curettage** 368
Satish S Savant, Sushil S Savant

Section 3: Heat and Cold Energy-based Procedures

26. **Radiofrequency Surgery and Electrocautery** 385
Bipin Deshpande

27. **Cryotherapy: In Noncosmetic Indications** 407
Avitus John Raakesh Prasad

Section 4: Needle-based Basic Procedures

28. **Microneedling** 423
Pradeep Kumari

29. **Platelet-rich Plasma Therapy: Principles and Preparation** 431
Gautam K Singh, Swapnil Shah, Pankaj Das

30. **Platelet-rich Plasma Therapy: Indications and Procedures** 438
Gautam K Singh, Nagendra Singh Beniwal, Swapnil Shah

31. **Microdermabrasion** 448
Silonie Sachdeva

32. **Sclerotherapy** 457
S Sacchidanand, TS Nagesh, Sujala S Aradhya

33. **Sclerotherapy for Vascular Malformations** 467
Sujay Khandpur, Tanvi Dev

Section 5: Vitiligo Surgery

34. **Overview of Vitiligo Surgery** 481
Davinder Prasad

35. **Minigrafting for Vitiligo** 488
Koushik Lahiri

36. **Suction Blister Epidermal Grafting** 498
Shyamanta Barua, Seujee Das

37. Thin Split-thickness Skin Grafting for Vitiligo 506
Niti Khunger, Rajat Kandhari

38. Epidermal Noncultured Cell Suspension in Vitiligo Including Megasessions 514
Munish Paul

39. Noncultured Extracted Hair Follicle Outer Root Sheath Cell Suspension 531
Rashi Pangti, Savita Yadav, Sanjay Singh, Somesh Gupta

40. Cultured Melanocyte Transplantation 536
Debdeep Mitra, Davinder Parsad, Krishna Talukdar

41. Vitiligo: Other Modalities of Treatment 542
Dilip Kachhawa

42. Surgical Management of Non-Vitiligo Leukoderma 548
Sanjeev Mulekar, Madhulika Mhatre

43. Complications of Vitiligo Surgery 555
Niti Khunger, Alka Goel

44. Innovations in Vitiligo Surgeries 564
Somesh Gupta, Sanjeev Gupta, Dilip Kachhawa, Ashique KT, Neha Taneja

Section 6: Procedural Management of Acne Scars

45. Acne Scars: An Overview 577
Rajat Kandhari, Jyoti Gupta

46. Surgical Management of Acne Scars 583
T Salim, Ragini Ghiya

47. Acne Scars: Treatment with Lasers 597
Imran Majid

48. Approach to Management of Acne Scars 603
BS Chandrashekar, Kumudhini S, Mysore Venkataram

Section 7: Nail Surgery

49. Basic Surgery of Nails 619
Sushil Tahiliani, Harsh Tahiliani, Manjit Sandhu Tahiliani

50. Advanced Nail Surgery 631
Chander Grover

51. Innovations in Nail Surgery 644
Sanjeev Gupta, Deepak Jakhar

Section 8: Regional Dermatosurgery

52. Eyelid Surgery 655
Manas Chatterjee, Dipali Rathod, Ruchi Hemdani, Harish Prasad BR

53. Blepharoplasty, Brow Lift, and Ptosis Surgery 670
Milind N Naik, Ruchi Hemdani

54. Dermatologic Surgery of the Lips 685
R Raghunatha Reddy, Shashikumar BM, Savitha AS

55. Surgery on the Ear 697
R Raghunatha Reddy, Savitha AS, Shashikumar BM

56. Hidradenitis Suppurativa....717
Kumaresan M, Eswari L

57. Surgery of Male Genitalia: Circumcision....727
Eswari L

Section 9: Miscellaneous Surgical Procedures

58. Chemosurgery....737
Niti Khunger, Ridhima Lakhani, Gulshant Panesar

59. Leg Ulcers....745
Reena Rai, R Jayashree, CR Srinivas

60. Nerve Biopsy: Technique and Role in Dermatology....757
Shekhar Neema, Sunmeet Sandhu

61. Leprosy Surgery....765
Sanjay Bhalchandra Sane

62. Dimple Creation Surgery....772
T Salim, Laila Arif

63. Mohs Micrographic Surgery....777
Nicholas J Collier, Venura Samarasinghe, Vishal Madan

Volume 2

Section 10: Hair Transplantation Surgery

64. The History of Hair Transplantation....791
Aniketh Venkataram, Mysore Venkataram

65. Applied Aspects and Approach to a Patient of Androgenetic Alopecia for Hair Transplantation....794
BS Chandrashekar, Madura C, Atul Bothra

66. Basic Principles of Hair Transplantation....809
Aniketh Venkataram, Mysore Venkataram

67. Counseling and Case Selection for Hair Restoration Surgery....813
Vaishalee Kirane

68. Design of Anterior Hairline in Male Pattern Baldness....820
Pradeep Sethi

69. Donor Area Strip Dissection....825
Anil K Garg, Seema Garg

70. Donor Area: Follicular Unit Extraction....840
Aman Dua, Nirav V Desai

71. Hair Transplantation: Recipient Area....850
Mysore Venkataram, Aniketh Venkataram

72. Complications of Hair Restoration Surgery....860
Narendra Patwardhan, Vaishalee Kirane

73. Body Hair Transplantation....866
Arvind Poswal

74. Scalp Micropigmentation....890
Rachita Dhurat, Sujit Shanshanwal, Ameet Dandale

75. Hair Transplant Repair 901
Nirav V Desai, Tushar D Kshirsagar

76. Hair Transplantation for Other Indications 914
Kavish Chauhan, Gillian Roga

77. Innovations in Hair Restoration 921
Kapil Dua, Shrenik Balegar

78. Ethics of Hair Transplantation 930
Mysore Venkataram

79. Setting Up a Hair Clinic 935
Aseem Sharma, Ravina Surve, Madhulika Mhatre, Amit Kerure

Section 11: Aesthetic Procedures: Basics

80. Basics of Aging Skin 945
Manjot Marwah, Shashikumar BM

81. Cosmeceuticals and Systemic Nutraceuticals 956
Ankur Talwar, Rajetha Damisetty, TS Vidya

82. Approach to Management of Aging Skin 974
Shital Poojary, Madhuri Agarwal

Section 12: Chemical Peels

83. Basics of Chemical Peels and Glycolic Acid Peels 985
Niti Khunger, Jyoti Gupta

84. Salicylic Acid and Trichloroacetic Acid Peel 995
Abhishek De, Aarti Sarda

85. Newer Superficial Peels 1003
Rashmi Sarkar, Pallavi Ailawadi

Section 13: Injectables

86. Botulinum Toxin: Pharmacology 1009
Rasya Dixit

87. Botulinum Toxin for the Upper Face 1014
Pradeep Kumari

88. Botulinum Toxin for the Midface, Lower Face, and Neck 1023
Shehnaz Arsiwala, Rajat Kandhari, Nazneen Arsiwala

89. Non-cosmetic Indications of Botulinum Toxin 1035
Mukta Sachdev, Rachana Shilpakar

90. General Principles of Soft-tissue Augmentation 1050
Shehnaz Arsiwala, Sadhana Deshmukh, Nazneen Arsiwala

91. Soft-tissue Augmentation: Hyaluronic Acid Dermal Fillers 1062
Maya Vedamurthy

92. Nonhyaluronic Acid Fillers 1073
Jaishree Sharad

93. Tear Trough Correction with Fillers 1082
Amit Luthra

94. Lip Augmentation 1094
Malavika Kohli, Banani Choudhury

95. Hand Rejuvenation 1108
Maya Vedamurthy

96. Complications of Botulinum Toxin and Fillers 1115
Madhuri Agarwal

97. Skin Boosters....1124
Malavika Kohli, Ayushi Bothra

Section 14: Liposuction

98. Dermatologic Liposuction Surgery....1129
Nilesh N Goyal

99. Powered Liposuction and Specific Aspects of Liposuction....1140
Jayashree Venkataram, Aniketh Venkataram, Mysore Venkataram

100. Laser Lipolysis 1146
Jayashree Venkataram, Mysore Venkataram

101. Injection Lipolysis and Cryolipolysis 1151
Anjali Pal, Harvinder S Marwah

102. Autologous Fat Transplantation....1161
Milind S Wagh, Lakshyajit D Dhami

103. Stromal Vascular Fat and Nanofat Grafting....1189
Aniketh Venkataram

Section 15: Lasers

104. History and Evolution of Energy-based Dermatosurgical Devices, Laser–Tissue Interactions, and their Clinical Relevance 1195
Kabir Sardana, Afreen Ayub

105. Establishing a Laser Theater....1223
Niteen V Dhepe, Debdeep Mitra

106. Laser Hair Reduction: Basic Principles Including Principles of Diode Laser 1230
Sandeep Arora, Gulhima Arora, Pankaj Das

107. Different Wavelengths for Hair Removal 1246
Anurag Tiwari, GR Rajput

108. Nd:YAG Laser: Basic Laser Principles and Indications 1252
Anuj Pall, Richa Kumar

109. Lasers for Pigmented Lesions 1266
Sanjeev J Aurangabadkar

110. Lasers for Tattoo Removal 1286
Sanjeev J Aurangabadkar

111. Lasers for Vascular Lesions 1301
Sujay Khandpur, Sindhuja T

112. Conventional Carbon Dioxide Laser: Indications and Use 1316
Manas Chatterjee, Surbhi Rajput

113. Er:YAG Laser....1323
Subodh Jane, Mysore Venkataram

114. **Fractional Lasers** 1328
Anil Ganjoo

115. **Nonablative Lasers and Lights Inclusive of Excimer Laser and Intense Pulse Light** 1338
BS Chandrashekar

116. **Microneedle Radiofrequency** 1348
Swapnil Shah, Siddharth Mani

117. **Noninvasive Body Contouring** 1357
Sachin Dhawan, Naina Jain

118. **Picosecond Lasers** 1368
Ganesh S Pai, Anusha H Pai

119. **Complications of Lasers** 1376
Apratim Goel, Zeba Chhapra

Section 16: Procedures for Pigmentation

120. **Periocular and Perioral Melanosis** 1391
Manas Chatterjee, Ruchi Hemdani

121. **Melasma and Its Aesthetic Management** 1411
Biju Vasudevan, Indrashis Podder

122. **Approach to Diffuse Facial Pigmentation** 1421
Senkadhir Vendhan, Pankaj Das, Biju Vasudevan

Section 17: Miscellaneous Topics in Aesthetics

123. **Aesthetics of Nail** 1429
Soni Nanda, Sonal Bansal

124. **Threads** 1438
Gulhima Arora, Ishmeet Kaur

125. **Microblading** 1449
Aseem Sharma, Madhulika Mhatre, Trupti Agrawal, Gunjan Shah

126. **Stretch Marks** 1459
Vikas Pathania, Reetu Agarwal, Siddharth Mani

Section 18: Interface of Dermatosurgery and Cosmetology with Patents, Legality, Academics, and Market

127. **Patient Satisfaction** 1469
Bhanu Prakash

128. **Psychological Issues in Aesthetics and Dermatosurgery** 1476
Abdul Latheef EN

129. **Accreditation** 1487
Manish Gautam

130. **Medicolegal Issues in Aesthetic Surgery** 1491
KH Satyanarayana Rao

131. **Clinical Photography in Surgical and Aesthetic Dermatology** 1500
Ashique KT, Feroze Kaliyadan

132. **Teledermatology Consultation in Cutaneous and Aesthetic Surgery** 1511
Garehatty Rudrappa Kanthraj, Jayadev B Betkerur

133. Social Media and Aesthetics....1526
Rohit Batra, Nitika Nijhara

134. Establishing and Setting Up a Dermatoaesthetic Practice and Related Marketing....1533
D Dinesh Kumar

135. Documentation and Electronic Medical Record, Consent and Counseling....1540
Pradyumna Vaidya, Nitika Deshmukh

136. Evidence-based Medicine in Cutaneous and Aesthetic Surgery....1549
Rashmi Sarkar, Suvarna Samudrala, Mysore Venkatram

137. Training Opportunities in Dermatologic Surgery....1554
Kanika Sahni, Nikhil Mehta

138. Suppliers' Details for Laser Machines, Dermatosurgical, and Aesthetic Equipment/Products....1560
Ankur Talwar, Kshama Talwar, Suresh Talwar, Rachita Talwar

139. Dermatologic and Cosmetic Procedures in Pregnancy....1566
Adit Mohan Garg, Mysore Venkataram

140. Dermatosurgery in Pediatric Population....1575
Shristi Shrestha, Arpita Arghya, Mysore Venkataram

Index....1587

CHAPTER 3

Applied Advanced Surgical Anatomy of Face

Mukta Sachdev, Suraj Sachidanand, Dinkar Sreekumar

KEY MESSAGES

- Facial anatomy is complex but can be understood better when resolved into a layered arrangement of planes.
- Aging is a combination of volume loss and tissue laxity contributing to descent of fat pads and development of rhytids.
- Layers of the face are continuous with the scalp and the neck, with discrete layers changing into different structures as they pass craniocaudally.
- Injection of fillers must respect the relative position of vasculature to avoid untoward complication.

INTRODUCTION

Aging is a multifactorial process. Physiological and morphological changes occur in both skeletal and soft tissue composites—the bones, ligaments, muscles, fascia, fat, and skin. The onset and rate of these structural changes varies between individuals of different genders and ethnicities. Due to the heterogeneity of the effects of each of the structures, it is difficult to ascertain which is the key player in the clinical changes that occur as the face ages. Thus, it is challenging to modify a specific structure with rejuvenation procedures, especially as limited treatment options are available to target bone, muscle, or ligaments.[1]

LAYERS OF THE FACE

With increasing interest in the anatomy of the face, surgeons and clinical anatomists have turned their attention toward the gross anatomy of the face. In the last decade, new findings and concepts regarding facial anatomy have been introduced, of which the most influential is probably the layered arrangement of the face.[1] These layers are arranged as follows: Layer 1—skin; layer 2—subcutaneous fat including the retinacula cutis, composed of fibrous connective tissue; layer 3—superficial musculoaponeurotic system (SMAS); layer 4—deep fat, and layer 5—periosteum or deep fascia. However, this general concept has to be adapted for each facial region, since there are regions where more layers (e.g., the temple with 10 layers) or fewer layers (e.g., the tear trough with three layers) can be identified. Moreover, the understanding of a parallel arrangement of layers has to be altered when considering the line of ligaments. The line of ligaments separates the medial mimetic face from the lateral face (predominantly static, concerned with mastication). In the medial midface there is no distinct parallel arrangement of the layers; here the muscles of facial expression course obliquely from bone to skin, whereas in the lateral midface the layers are in parallel and continuous with each other while extending from the neck to the scalp.[2]

THE LINE OF LIGAMENTS

Facial ligaments are well as they are released during face-lifting procedures to achieve the desired effects. Of the described ligaments, the zygomatic ligament (also called McGregor's patch) is the strongest, resisting the greatest force before ultimate failure during biomechanical testing. Interestingly, all major facial ligaments (irrespective of whether they are true or false) can be arranged into a single line located immediately lateral to the lateral orbital rim and extending from the temporal crest to the mandible.

From superior to inferior, the ligaments are the temporal ligamentous adhesions, lateral orbital thickening, zygomatic ligament, and mandibular ligament.[1]

In the medial midface (i.e., medial to the line of ligaments) are the midfacial deep fat compartments; surgically relevant spaces are found in the lateral midface, e.g., premasseteric spaces. It is of some clinical importance that injections medial to the line of ligaments will result in projection of the overlying soft tissues, whereas injections lateral to this line lead to a lifting effect in more inferiorly located regions. This is a result of the oblique arrangement of the medial midface versus the parallel arrangement of the lateral midface.[2]

DEEP AND SUPERFICIAL FAT COMPARTMENTS OF THE FOREHEAD

Therapeutic options for the forehead mostly include neuromodulator applications in order to temporarily reduce the contractile activity of the frontalis, corrugator supercilii, depressor supercilii, and orbicularis oculi muscles. The treatment approach has changed from rigid injection schemes

JAYPEE BROTHERS

to more individualized treatments based on each person's individual anatomy. A recent trend includes restoration of the volume loss of the frontal soft tissue. This is due to fact that the frontal bone undergoes age-related changes, similar to those of the midfacial bones. As the covering soft tissues are thinner than those of the midface and fat is redistributed from superficial to abdominal or ectopic locations (liver, bone marrow), frontal hollowing can result. This contributes significantly to a more skeletal appearance of the face. Volume can be restored in the superficial and deep compartments of the forehead using soft tissue filler. Three superficial fat compartments are present and located in layer 2 between the skin (layer 1) and the frontalis muscle. As the frontalis muscle is a continuation of the galea aponeurotica, it can be regarded as layer 4 (if the thin sheet covering the muscle is regarded as layer 3). Between the frontalis muscle (layer 4) and its underlying fascia (layer 6), a thin layer of fat can be identified—the subfrontal fat (layer 5). Inside this fat, the supraorbital and supratrochlear vessels travel superiorly after they emerge from their respective foramina. The subfrontal fat lies between the inferior and middle frontal septa, which are formed by the transition of the vasculature from deeper to superficial layers and extend from the periosteum to the fascia covering the underside of the frontalis muscle.[2]

Deep to the frontalis muscle and its fascia (layer 6) the three deep forehead compartments can be found. These compartments are located in layer 7 and are bounded inferiorly by the middle frontal septum and superiorly by the superior frontal septum and are located between the frontalis muscle complex and the periosteum.[2]

Located between the inferior frontal septum (superior boundary) and the orbicularis retaining ligament (inferior boundary) **(Fig. 1)** and lateral to the emergence of the supraorbital neurovascular bundle from the supraorbital foramen, the retro-orbicularis fat (ROOF) is located. This fat is located deep to the orbicularis oculi muscles (layer 3) and superficial to the periosteum of the frontal bone; it is connected with the lower temporal compartment via the superior interval.[2]

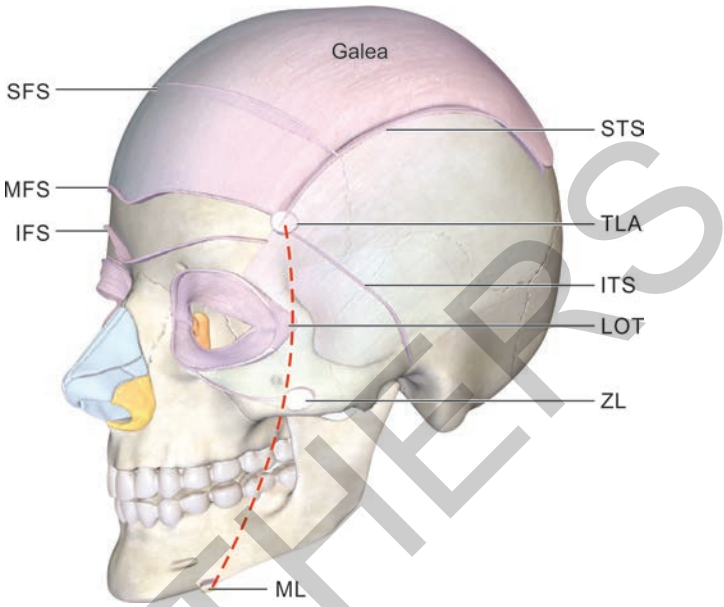

Fig. 1: Virtual model of the face showing the major facial ligaments. Note how the ligaments are arranged as a single line located immediately lateral to the lateral orbital rim and extending from the temporal crest to the mandible. (IFS: inferior frontal septum; ITS: inferior temporal septum; LOT: lateral orbital thickening; MFS: middle frontal septum; ML: mandibular ligament; SFS: superior frontal septum; STS: superior temporal septum; TLA: temporal ligamentous adhesion; ZL: zygomatic ligament)
Source: Cotofana S, Lachman N. Anatomy of the facial fat compartments and their relevance in aesthetic surgery. J Dtsch Dermatol Ges. 2019;17(4):399-413.

TEMPORAL FAT PADS

Volumizing procedures of the temple are used to restore volume loss, which may be due to changes of the bony skeleton and/or to reduce volume of the temporalis muscle or temporal fat pads. As the fat pads are related to the respective layers, the layered anatomy of the temple should be kept in mind. The layers of the temple are directly contiguous with the five layers of the SCALP: Skin; Connective tissue (here subcutaneous fat); Aponeurosis (here galea aponeurotica); Loose connective tissue, and Periosteum. These five layers are continuous into the temple, although they change their names after passing the superior temporal septum **(Fig. 1)**. The galea aponeurotica becomes superficial temporal fascia, while the periosteum is now the deep temporal fascia. The anterior and posterior branches of the superficial temporal artery can be found within the superficial temporal fascia. Application of soft tissue fillers using the superficial technique places the product into the subcutaneous fat, i.e., into layer 2, which is, thus, superficial to the superficial temporal artery. Two compartments are located between the superficial and deep temporal fascia in layer 4—the upper and lower temporal compartments. The upper temporal compartment is located between the superior and inferior temporal septa and contains no relevant neurovascular structures, whereas the lower temporal compartment is located between the inferior temporal septum and the adhesions of the zygomatic arch, and contains the frontal branches of the facial nerve (motor), the zygomaticotemporal branches (sensory), and the temporal part of the sentinel vein. Between 2–5 cm cranial to the zygomatic arch, the deep temporal fascia divides into a superficial lamina (layer 5) and a deep lamina (layer 7) of the deep temporal fascia, and encloses the superficial temporal fat pad and the proximal part of the sentinel vein (layer 6), which is here termed the medial zygomaticotemporal vein. The superficial lamina is continuous in the midface with the parotideomasseteric (PM) fascia (layer 5) and extends into the neck as the investing layer of the deep cervical fascia.[1] The deep lamina of the deep temporal fascia travels deep to the zygomatic arch into the masticatory space and is connected

JAYPEE BROTHERS

there to the parotido-temporal fascia.[1] Deep to the deep temporal fascia, the temporal extension of the buccal fat pad (of Bichat) is located; here it is referred to as the deep temporal fat pad and is located in layer 8. The temporalis muscle is located in layer 9 and receives its arterial blood supply from branches of the internal maxillary artery, the anterior and posterior deep temporal arteries, which travel superficial to the periosteum (layer 10). Soft tissue fillers applied with the deep technique are in contact with the bone and should be placed in proximity to the temporal crest in order to avoid contact with the deep temporal arteries.[1]

INFRAORBITAL REGION: TEAR TROUGH AND SUBORBICULARIS OCULI FAT

The infraorbital region is one of the most difficult areas to treat, although the layering is less complex than that of the temple or the forehead. Clinically, dark circles in the medial infraorbital area (i.e., tear troughs) as well as palpebromalar grooves (i.e., lateral depressions between the lower eye lid and the cheek eminence) are of concern. The depression immediately inferior to the tear trough is called the nasojugal groove and is continuous with the midcheek groove (also referred to as a mediojugal fold). Together, the nasojugal groove and the palpebromalar groove form the so called "V-frame" deformity, which is a sign of facial aging and can be related to the loss of subcutaneous fat from the superficial nasolabial, and superficial medial cheek fat compartments. The infraorbital area can be separated into medial and lateral parts by a vertical line through the medial margin of the pupil. In the medial part (area of the tear trough) only three layers can be identified—skin (layer 1), orbicularis oculi muscle (orbital part) (layer 2), and periosteum (layer 3). The angular artery is located in the groove between the cheek and the lateral aspect of the nose, running vertically deep to the orbicularis oculi muscle, whereas the angular vein is located in the depth of the nasojugal groove, 4.2 ± 0.7 mm inferior to the inferior orbital rim and running obliquely from inferolateral to superomedial deep to the orbital part of the orbicularis oculi muscle. Several layers are present in the lateral infraorbital part. Deep to the orbital part of the orbicularis oculi muscle (layer 3) the suborbicularis oculi fat (SOOF) is located; this usually has separate medial and lateral parts.[1] This fat is separated by the superficial lamina of the deep temporal fascia (layer 5) from the fat within the prezygomatic space (layer 6) overlying the periosteum (layer 7). The inferior boundary of both the SOOF and of the prezygomatic space is the zygomatico-cutaneous ligament and the superior boundary is the bilaminar orbicularis retaining ligament. The SOOF is connected via the temporal tunnel to the lower temporal compartment, since both are located in layer 4 and reside on top of the superficial lamina of the deep temporal fascia. Along the medial wall of the zygomatico-cutaneous ligament, the angular vein can be identified after it emerges deep to the zygomaticus major muscle; it has a variable course superficial or deep to the zygomaticus minor muscle. The zygomatico-cutaneous ligament fuses with the orbicularis retaining ligament where it crosses the vertical medial pupillary line just before reaching the tear trough—in other words, the tear trough is the superficial landmark for the medial end of the SOOF. Treatment of malar mounds can be challenging due to the multi-layered arrangement in the lateral infraorbital area.[2]

Midface: Parotideomasseteric (lateral midface), buccal (lateral midface), and central midface (medial midface) regions.

The midface has three craniocaudal subdivisions—upper, middle, and lower with reference to the horizontal. However, an additional subdivision of the midface should be made when incorporating functional anatomy and its relation to the line of ligaments 2.

PAROTIDEOMASSETERIC REGION LOCATED IN THE LATERAL MIDFACE

The PM region contains the masseter muscle and the parotid gland. It extends from the auricle to a vertical line at the lateral margin of the bony orbit (when viewed from lateral). Its layers are parallel and include the following structures: Skin (layer 1), subcutaneous fat, i.e., middle and lateral superficial fat compartments (layer 2), SMAS (layer 3), deep (sub-SMAS) spaces (layer 4), and PM fascia (layer 5). Deep to layer 5 are the branches of the facial nerve, the parotid gland, the parotid duct, and the variable accessory parotid gland. The marginal mandibular, buccal, and zygomatic branches of the facial nerve travel within fibrous connective tissue sheets that connect the PM fascia to the SMAS, which encloses surgical access spaces that are used in face-lifting procedures. These spaces are the lower, middle, and upper premasseter spaces. The transverse facial artery runs in the superior premasseter space and gives off a branch that runs within the zygomatic ligament (McGregor's patch) to provide axial blood supply to the overlying SMAS. Deep to the masseter muscle is the buccal fat pad with its four extensions, of which the temporal extension is called the deep temporal fat pad. The buccal fat pad is located in a separate spaces called the masticatory space, and is separated from the premasseter spaces by the masseter muscle, and from the buccal spaces by the facial vein within the facial vein canal.[1]

BUCCAL REGION OF THE LATERAL MIDFACE

The buccal region is less well defined as it can be assigned to both the medial and lateral midface. However, with respect to the underlying anatomy, this area covers the most mobile area of the face, specifically the cheek and its contents, which are dominated by the buccinator muscle in layer 6. The layers in this region are parallel, and it contains the following structures: Skin (layer 1); subcutaneous fat

JAYPEE BROTHERS

(i.e., jowls fat compartment) (layer 2); SMAS in its superior part and the horizontal, modiolar part of the platysma (layer 3); buccal space (layer 4); buccopharyngeal fascia (layer 5), and buccinator muscle (layer 6). The facial artery travels inside the buccal space, whereas the facial vein runs inside the facial vein canal, which forms the posterior boundary of the buccal space and is not considered as a content of the buccal space. The buccal fat pad is located in the masticatory space, which is posterior to the buccal space within the masticatory space.[1]

The jowl deformity is caused by the gliding of the platysma against the mandible, since between the mandibular ligament and the masseter muscle the facial artery and facial vein cross the mandible and are covered in deep fat here. This fat is not connected to the fat within the buccal space or to the buccal fat pad in the masticatory space. With age-related facial changes, the platysma glides and the overlying (subcutaneous) jowl fat compartment glides inferiorly and causes the appearance of jowls.[2]

CENTRAL MIDFACE LOCATED IN THE MEDIAL MIDFACE

The central midface is the facial region where the majority of minimally invasive aesthetic injections are performed. The deep and superficial midfacial fat compartments are located here and this area is prone to age-related changes as the underlying bone undergoes remodeling, with a corresponding change in the maxillary angle. If this angle changes, the position of the fat compartments changes too and the clinical signs of facial aging become visible.[2]

The layers are arranged differently because the deep fat compartments are bound by the muscles of facial expression; these originate from the bone and insert into the nasolabial sulcus, the orbicularis oris muscle complex or the modiolus. Thus, it is most important for a practitioner to understand the two- and three-dimensional anatomy of this region for safe and effective results following surgical and non-surgical procedures: Skin (layer 1); subcutaneous fat, i.e., the superficial nasolabial and the superficial medial cheek fat compartment (layer 2); SMAS and orbital part of orbicularis oculi muscle (layer 3); deep nasolabial fat compartment (located within the premaxillary space) (layer 4); levator labii superioris alaeque nasi muscle (layer 5); deep pyriform space (medial to the infraorbital foramen) (layer 6); and deep medial cheek fat compartment (between the infraorbital foramen and the angular vein) (layer 6) and deep lateral cheek fat compartment (between the angular vein and the zygomaticus major muscle (layer 4); and periosteum (layer 7 medial to the angular vein; layer 5 lateral to the angular vein). Next to the origin of the zygomaticus major muscle, the zygomatic ligament (McGregor's patch) is located; this is included in the line of ligaments and forms the boundary between the medial and lateral midface. The presence of the zygomaticus minor muscle is variable; it follows the course of the zygomatico-cutaneous ligament, which forms the superior boundary of the deep medial and lateral cheek fat compartments, whereas the constant zygomaticus major muscle is connected via a broad fascial membrane (the transverse facial septum) to the underlying maxilla. The transverse facial septum forms the inferior boundary of the deep lateral cheek fat and thus the superior boundary of the buccal space. It is the leading cause of "apple-cheeks" when smiling.[2]

FAT DISTRIBUTION AROUND THE PERIORAL REGION AND THE CHIN

The boundaries of the perioral region are the nasolabial sulci, the nose, the modiolus, the labiomandibular sulci, and inferiorly the submental septum. The major difference between this region and all other facial regions is that there is no clear layered arrangement and there are no subcutaneous fat compartments. The subcutaneous fat is dispersed, since the underlying muscles of facial expression and the collagenous fibers form a strong network that connects the skin firmly to the underlying muscular layer. This makes precise movements of the overlying skin possible; these are needed for various facial expressions and for food intake. The layers can be best summarized as follows: Skin (layer 1), subcutaneous fat (layer 2), musculature (e.g., orbicularis oris muscle) (layer 3), deep fat (deep chin fat in the midline and the (deep) labiomandibular fat located around the mental foramen), and periosteum (layer 5). The fat located between the periosteum and the musculature is an important gliding space that protects the neurovascular bundle as it emerges from the mental foramen.[2]

The change in subcutaneous arrangement between the firm perioral attachment and the loose and layered arrangement of the remainder of the facial regions where a clear subcutaneous layer is present underlies the formation of the nasolabial as well as the labiomandibular sulcus.[2]

CONCLUSION

The concept of the layered arrangement of the face is an effective way to understand the spatial relationship and the functional interplay of the soft tissues of the face. Understanding the layers, the compartments, and their contents is crucial for safe and effective minimally invasive rejuvenation procedures. Since each structure (bone, ligaments, fascia, muscles, fat compartments, and skin) exhibits specific contributions to the process of facial aging, it is important to determine which structure is the key player in the presenting clinical scenario. Injection of soft tissue fillers should thus be performed with caution and with a precise anatomical understanding of the facial fat compartments, as one must target a specific fat compartment in order to achieve the desired effect. Applying the product in the wrong fat compartment might yield an aesthetically undesirable result.[2]

JAYPEE BROTHERS

ANATOMY OF THE FACIAL DANGER ZONES

Knowledge of the facial anatomy is essential. As evidenced by numerous studies, the facial vasculature has many variations and can be found in various tissue planes, depending on location within the face. Anticipating the depth and course of vessels allows practitioners to develop techniques to avoid intravascular injection, vascular injury, and/or compression.[3]

BROW AND GLABELLAR REGION

Pertinent Anatomy

The corrugators originate along the nasal process of the frontal bone, coursing superolateral under the frontalis, inserting dermally at the brow. Over time, contraction of this muscle creates vertical rhytides at the brow level. Likewise, procerus muscle activity leads to horizontal nasal rhytides, also referred to as "bunny lines".[3]

The supratrochlear artery, a branch of the ophthalmic artery, exits the superomedial orbit 17–22 mm lateral to midline, piercing or passing superficial to the corrugator, deep to the orbicularis and frontalis **(Fig. 2)**. Approximately 15–25 mm above the orbital rim, the artery traverses the frontalis and orbicularis to enter the subcutaneous plane. It continues running superiorly in the subcutaneous plane 15–20 mm from midline in a paramedian position.[3] At the level of the brow, the supratrochlear artery runs vertically in line with the medial canthus ± 3 mm. Another study demonstrated the artery within the glabellar frown line in 50% of cases and an average of 3.2 mm lateral in the remaining cases. The supratrochlear artery branches anastomose with the angular, supraorbital, and dorsal nasal arteries.[3]

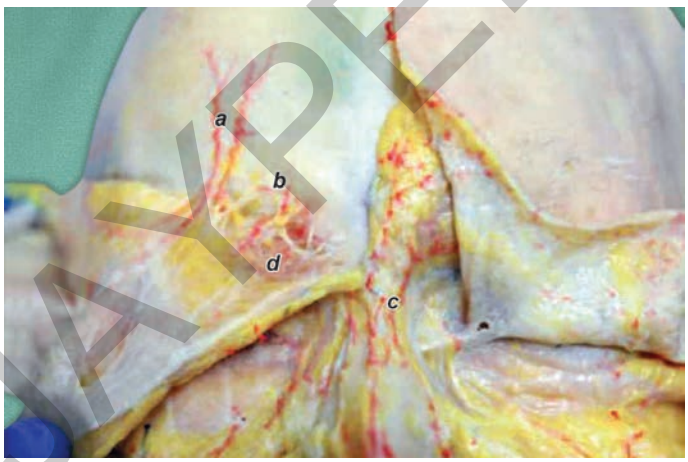

Fig. 2: The supraorbital artery (a) is shown exiting above the brow, ramifying a periosteal branch before traversing the subgaleal plane. The supratrochlear artery (b) lies medial, piercing the corrugator muscle (d), and anastomosing with the dorsal nasal artery (c) and the supraorbital artery (a).
Source: Scheuer JF 3rd, Sieber DA, Pezeshk RA, Campbell CF, Gassman AA, Rohrich RJ. Anatomy of the facial danger zones: maximizing safety during soft-tissue filler injections. Plast Reconstr Surg. 2017;139(1):50e-8e.

The supraorbital artery, also a branch of the ophthalmic artery, exits the orbit through the supraorbital notch approximately 32 mm lateral to midline, generally corresponding to a vertical line intersecting the medial limbus of the cornea. Erdogmus and Govsa found that the artery most commonly pierced the frontalis 20–40 mm above the orbital rim, and then surfaced in the subcutaneous tissue between 40 and 60 mm. However, Kleintjes observed the supraorbital artery sending vertical branches entering the subcutaneous tissue as low as 15–20 mm above the rim after a short intramuscular course. In addition to the dorsal nasal, supratrochlear, and angular arteries, the supraorbital artery sends branches that anastomose with the frontal branch of the superficial temporal artery most often at the junction of the transverse inferior and middle thirds of the forehead.[3]

Maximizing Safety

In the brow and glabella area, the vasculature is initially deep, quickly transitioning to the intramuscular and subcutaneous level. Therefore, we recommend using a low-G' filler injected intradermally to fill glabellar frown lines and bunny lines, in the brow and glabellar area. Apply digital pressure at the supraorbital rim during injection to occlude vessels. Intravascular injection at this level can travel retrograde through the anastomoses between the supraorbital, supratrochlear, and ophthalmic arteries, leading to blindness and tissue loss **(Fig. 3)**. In multiple reviews, the glabella was the most common filler injection site leading to visual loss.[3]

TEMPORAL REGION

Pertinent Anatomy

Within the temporal fossa, the frontal branch of the superficial temporal artery and temporal branch of the facial nerve run within the temporoparietal fascia. In a recently published cadaver study, the origin of the frontal branch from the superficial temporal artery was on average located 17.2 mm anterior and 36.9 mm superior to the tip of the tragus. Typically, the frontal branch of the superficial temporal artery can be located coursing over the frontalis 15.8 mm superior and 14.8 mm posterior to the peak of the brow. A line connecting these two points delineates the most common course of the artery, although variations do exist. In the study, the authors defined their danger zone as the area starting 2.5 mm lateral and 3.0 mm superior to the peak of the brow, and thus recommended digital pressure to this area when injecting the temporal hollow. Trussler et al. histologically observed the frontal branch artery running in the temporoparietal fascia in close proximity to the temporal branch of the facial nerve 2 cm above the zygomatic arch.

JAYPEE BROTHERS

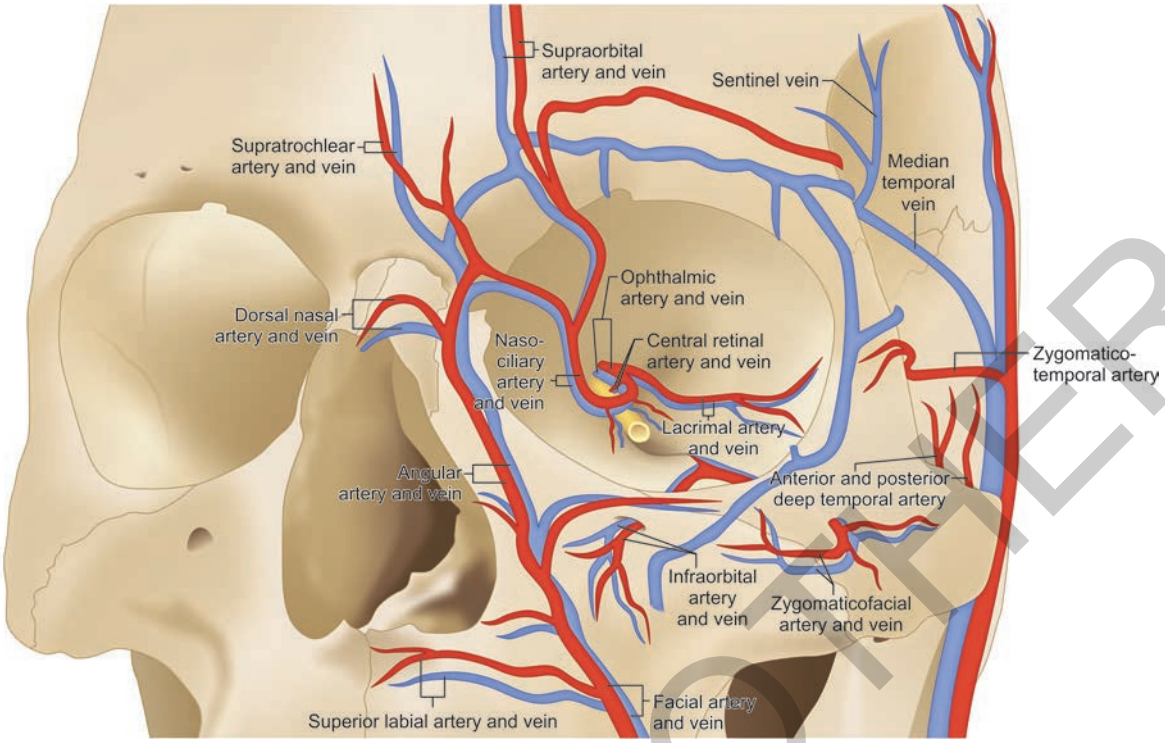

Fig. 3: Potential routes for retrograde embolization to the ophthalmic vessels.
Source: Carruthers JD, Fagien S, Rohrich RJ, Weinkle S, Carruthers A. Blindness caused by cosmetic filler injection: a review of cause and therapy. Plast Reconstr Surg. 2014;134:1197-1201.

In our dissection, we observed similar findings; the frontal branch of the superficial temporal artery ran within the temporoparietal fascia 2 cm above the arch, transitioning to become completely subcutaneous just superior to the brow near the border of the frontalis. The frontal branch of the superficial temporal artery arborized with the supraorbital arterial system in the deep and superficial planes **(Fig. 4)**. This presents another pathway of retrograde embolization to the arterial supply of the globe. In a cadaver study, dye injected into the superficial temporal artery was found within the ipsilateral globe, and even bilaterally in certain specimens.[3]

Of additional concern, the middle temporal vein runs approximately 20 mm above and parallel to the zygomatic arch within the superficial temporal fat pad. Given its average size of 5.1 mm (range, 2.0–9.1 mm) and its connection to the cavernous sinus, Jung et al. recommended injecting within a fingerbreadth of the zygomatic arch in the preperiosteal plane. Although extremely rare, there have been reports of fatal nonthrombotic pulmonary embolism during fat injections when the middle temporal vein was cannulated. Hyaluronic acid (HA) facial injections have also been implicated as a cause of nonthrombotic pulmonary embolism. Tansatit et al. recommend pressing the pretragal area during filler injection to prevent a nonthrombotic pulmonary embolism through inadvertent cannulation of the middle temporal vein. In their cadaveric study, retrograde injections of the middle temporal vein did not fill the supraorbital, supratrochlear, or any of the medial orbital veins.[4] However, anterograde injections drained into the internal jugular vein. Thus, middle temporal vein injections are less likely a mechanism for ocular embolism, although it has been postulated.[3]

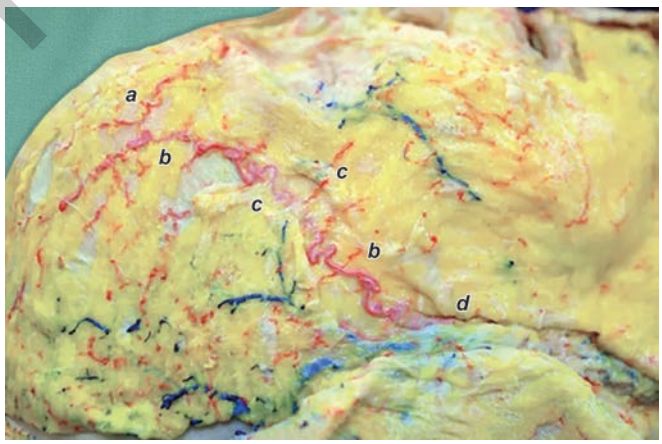

Fig. 4: The superficial temporal artery (d) is demonstrated ramifying its frontal branch (b). The subcutaneous tissue (c) has been reflected anteriorly and posteriorly to delineate the course of the frontal branch artery within the superficial temporal fascia. The frontal branch artery (b) can be clearly seen anastomosing with the supraorbital artery (a) superficial to the frontalis muscle after transitioning to the subcutaneous plane.
Source: Scheuer JF 3rd, Sieber DA, Pezeshk RA, Campbell CF, Gassman AA, Rohrich RJ. Anatomy of the facial danger zones: maximizing safety during soft-tissue filler injections. Plast Reconstr Surg. 2017;139(1):50e-8e.

Despite efforts to place filler in the subcutaneous anatomical plane, cadaver studies have shown unintended deeper location of filler in the superficial temporal fascia,

JAYPEE BROTHERS

temporalis muscle, and encompassing a superficial muscular artery. In an attempt to obtain uniform results, some authors have heavily diluted the fillers, injecting them in the deep subcutaneous plane adjacent to the superficial temporal fascia.[3]

Maximizing Safety

In the temporal region, fillers should be injected deeply or superficially. Deep filler injections in the temporal fossa should be in the preperiosteal plane. They should be injected within a fingerbreadth of the arch and/or >25 mm above it to avoid the middle temporal vein. In the preperiosteal plane, a high-G' filler in greater amounts will be needed to translate results superficially. Therefore, we choose to inject filler in the superficial subcutaneous tissue, staying just below the dermis while applying pressure just superior to the peak of the brow. The frontal branch of the superficial temporal artery runs one layer deeper in the temporoparietal fascia and therefore is at less risk. As the artery approaches the temporal fusion line, it transitions to the subcutaneous plane. Embolic phenomena occur when the cannulated artery propagates filler into the supraorbital system, or filler travels retrograde into the main superficial temporal artery system. Either can lead to blindness. We caution against injecting at intermediate depths because it becomes nearly impossible to discern which layer is being injected.[3]

INFRAORBITAL REGION

Pertinent Anatomy

Midface filler injections allow augmentation without the need for an alloplastic implant. Within this region, the infraorbital artery and nerve typically exit the infraorbital foramen. If the artery is inadvertently cannulated, this again provides another route for filler embolization. Likewise, injury to the nerve can lead to hyperesthesia/hypoesthesia and pain. Basic anatomical knowledge of the infraorbital foramen allows practitioners to better predict its location and avoid its contents.[3]

There is great variation in the literature regarding anatomical landmarks for the vertical plane of the infraorbital foramen. It has been documented in-line with the first premolar, second premolar, and the canine teeth. Likewise, a minority of patients have multiple foramina. The average distance between the infraorbital foramen and the inferior orbital rim is 6.3–10.9 mm. The average distance of the infraorbital foramen from facial midline is 25.7–27.1 mm in men and 24.2–26.8 mm in women. Other authors have described it being approximately 33–41% of the total distance when measuring from the medial to the lateral canthus. Approximately 50% of the time, Aziz et al. found the infraorbital foramen in the same vertical plane as the supraorbital foramen.[3]

Maximizing Safety

Overall, when injecting deep into the midface, the above measurements should be kept in mind to avoid intravascular cannulation or vascular injury. Generally, the infraorbital foramen will be located approximately one-third of the distance between the medial and lateral canthi up to 11 mm below the infraorbital rim. Clinically, the infraorbital foramen lies slightly less than a fingerbreadth below the infraorbital rim in the vertical plane of the medial limbus, or immediately lateral to it. We avoid direct deep injections into this area, choosing to inject just lateral. Injections more medial approaching the medial canthus should be avoided completely. If filler is needed in this area, it can be injected laterally and pushed medially.[3]

LIPS/COMMISSURE

Pertinent Anatomy (Upper Lip)

Perioral filler injections are becoming more common as patients frequently request more full and voluptuous lips. The goals for the patient must be determined before injection—volume versus vermilion-cutaneous enhancement, or both. Young patients generally have adequate volume but desire enhancement of the vermillion-cutaneous border. Volume is often required in older patients and those with thin lips, occasionally along with vermilion-cutaneous enhancement.[3]

Although many variations of the perioral vasculature are documented in the literature, a general concept of the most common anatomy increases the reproducibility of safe results. The takeoff of the superior labial artery off the facial artery is on average 10.4–12.1 mm lateral and approximately 43° superior to the corner of the mouth, or 5–9 mm above this landmark. However, the origin can at times be inferior to the commissure. The superior labial artery then usually runs superior to the vermillion border, then coursing inferior to the border just before approaching Cupid's bow. In the upper lip, the superior labial artery is 3–7.6 mm deep to skin, running usually between the orbicularis and the oral mucosa, or less often within the orbicularis. In two separate studies, the superior labial artery was found 4.5–7.6, 2.6–3.2, and 5.6–6.7 mm deep as measured from the skin, oral mucosa, and lower margin of the lip, respectively. Throughout its course, the superior labial artery gives off small-caliber deep (between the mucosa and muscle, or through the muscle), and superficial (between the skin and muscle) ascending branches. These can travel superiorly to anastomose with the inferior alar, columellar, and anterior septal branches.[3]

Maximizing Safety

Injections into the upper lip should be <3 mm deep, with an intermediate or low-G' filler either at the vermillion-cutaneous border or within the dry vermillion. The superior

JAYPEE BROTHERS

labial artery is typically posterior at the mucosal-muscular interface and several millimeters above the inferior border of the lip. Intravascular injection can lead to tissue necrosis.[3]

Pertinent Anatomy (Commissure)

Along with other authors, we observed the facial artery lying deep to the risorius and zygomaticus major and 12–15.5 mm lateral to the commissure. However, there are cases where the artery can be running through separate muscle bands of the zygomaticus major. Clinically, the area encompassing the facial artery and the superior labial artery origin can be estimated by placing a thumb beside the corner of the mouth.[3]

Maximizing Safety

Because the facial artery and the origin of the superior labial artery generally lie deep to or within the muscle, superficial subcutaneous injections in a linear crosshatching fashion safely address volume deficiency and laxity in this area.[3]

Pertinent Anatomy (Lower Lip)

There have been attempts to categorize all of the origins and variants of the inferior labial artery. To recapitulate each is beyond the scope of this article. However, the inferior labial artery has been observed running horizontally at the level of the vermillion-cutaneous level, and at the height of the labiomental fold perfusing the lower lip with vertically oriented branches. At the level of the vermillion-cutaneous border, the inferior labial artery lies 6.4–7.1, 5.9–9.4, and 4.4–4.8 mm from the anterior, superior, and posterior borders of the lower lip, respectively **(Fig. 5)**. As the inferior labial artery branches from the facial artery, it enters the lower lip and travels between the mucosa and muscle. The numerous patterns of the inferior labial artery and its varied origins may lie in the fact that there are no universally accepted definitions distinguishing between the inferior labial artery and the labiomental artery. Although the inferior labial artery has numerous variations ranging from a common trunk with the superior labial artery to its complete absence, these patterns may overall not be as important as ascertaining the correct depth of the artery when injecting fillers. In an attempt to clarify, Lee et al. classified an artery traveling in the middle of the lower lip as a horizontal labiomental artery, regardless of the final trajectory toward the lower lip; an artery traveling along the level of the lower lip vermillion-cutaneous border with an origin near the commissure was called an inferior labial artery. When this distinction is not made, the origin of the inferior labial artery varies in the literature between just superior to the corner of the mouth, all the way to the lower margin of the mandible.[3]

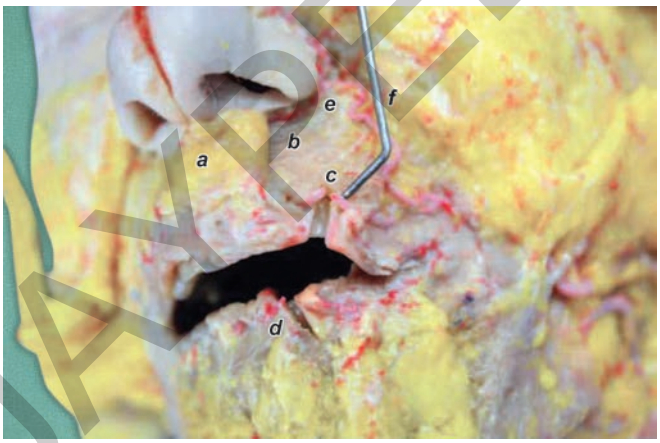

Fig. 5: The subcutaneous tissue (a) has been reflected, revealing the orbicularis oris muscle (b). The superior labial artery (c) can be seen running deep to the orbicularis on the labial mucosa, superior to the inferior lip border. The inferior labial artery (d) is demonstrated running in a similar fashion in the lower lip. The facial artery (f) is seen ramifying the inferior alar artery (e) in the upper third of the nasolabial fold.
Source: Scheuer JF 3rd, Sieber DA, Pezeshk RA, Campbell CF, Gassman AA, Rohrich RJ. Anatomy of the facial danger zones: maximizing safety during soft-tissue filler injections. Plast Reconstr Surg. 2017;139(1):50e-8e.

Maximizing Safety

Lower lip injections should be with an intermediate- or low-G' filler either at the vermillion-cutaneous border or within the dry vermillion, no >3 mm deep. The inferior labial artery is typically posterior at the mucosal-muscular interface and below the superior border of the lip. Intravascular injection in the area leads to tissue necrosis.[3]

NASOLABIAL FOLD

Pertinent Anatomy

Filling a deep nasolabial fold instantly gives the face a rejuvenated appearance. As for other areas of the face, the various naming schema and classification systems of the facial artery and its superior course have led to confusion in the literature. For our purposes, the arterial portion running from the cheilion to the alar base is referred to as the facial artery until the takeoff of the lateral nasal artery. Thereafter, it is referred to as the angular artery.[3]

After giving off the superior labial artery near the commissure, the facial artery continues superiorly adjacent to the nasolabial fold. In the cadaver study by Yang et al., the facial artery was observed in close proximity to the nasolabial fold, with its entire course being medial (42.9%), lateral (23.2%), or crossing the nasolabial fold (33.9%). At the transition between the upper middle third and the middle lower third of the nasolabial fold, the facial artery was on average 1.7 mm medial and 0.3 mm medial to the nasolabial fold, respectively. At the level of the ala, the facial artery branches to yield the inferior alar artery and the lateral nasal artery immediately above. It then continues as the angular artery when present. There are also "duplex" or "detouring" patterns, where an ipsilateral duplicate facial artery may branch low in the face, traveling to the infraorbital area and then crossing medially

JAYPEE BROTHERS

at the nasojugal groove to become the angular artery. Lastly, there are patterns where the angular artery is absent or arises in a retrograde fashion from the ophthalmic artery. This is not a comprehensive review of every branching pattern of the facial artery, but instead an illustration of the variability.[3]

When injecting in the region of the nasolabial fold, the depth of the artery becomes all the more pertinent to avoid an intravascular injury. Lee et al. described the relationship of the facial artery with regard to the facial muscles in a cadaver dissection series. In 85.2% of cadavers, the facial artery was superficial to the mimetic muscles at some point between the alar base and the modiolus **(Figs. 6 and 7)**. In 16.7%, the artery was completely subcutaneous from the modiolus to the alar base. In only 14.8% of cadavers did the facial artery remain completely beneath the mimetic muscle all the way to the alar base. In our dissection, the artery became very superficial in the upper third of the nasolabial fold as it ramified the inferior alar artery and the lateral nasal artery. It is in this area that it becomes most prone to injury during subcutaneous filler injections.[3]

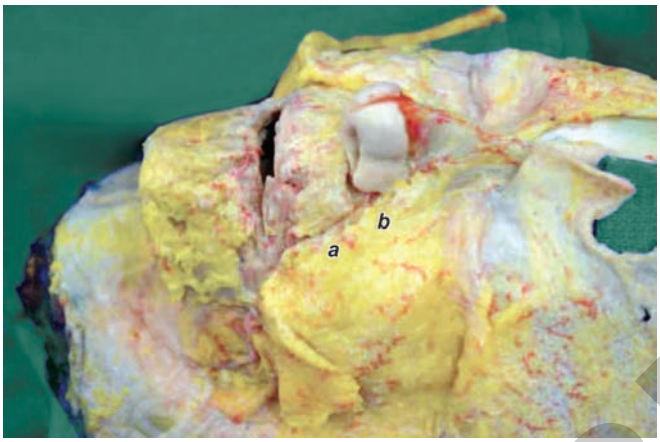

Fig. 6: The nasolabial portion of the facial artery is seen running beneath subcutaneous tissue (a) until its upper third, where it becomes more superficial (b) and at greater risk for injury during injections.
Source: Scheuer JF 3rd, Sieber DA, Pezeshk RA, Campbell CF, Gassman AA, Rohrich RJ. Anatomy of the facial danger zones: maximizing safety during soft-tissue filler injections. Plast Reconstr Surg. 2017;139(1):50e-8e.

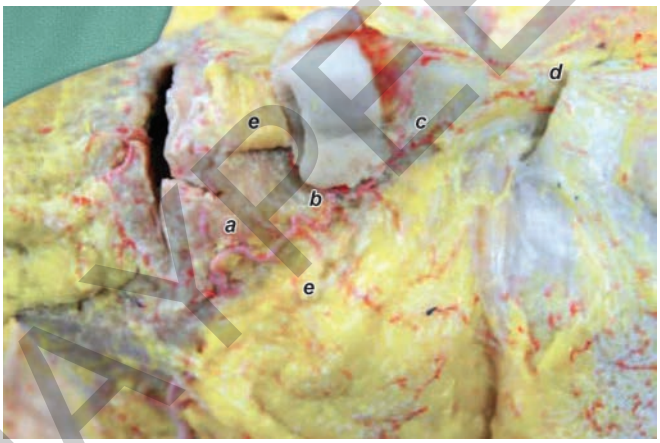

Fig. 7: With the subcutaneous tissue (e) reflected, the facial artery (a) is seen running in the nasolabial fold sporadically within the muscle but mostly in the plane between the subcutaneous tissue and muscle. The artery becomes superficial (b) in the upper third of the nasolabial fold and is at risk during superficial injections. The transition of the facial artery into the angular artery (c), and its anastomosis with the dorsal nasal artery (d) is demonstrated. Of note, the facial artery lies approximately 1.5 cm lateral to the commissure.
Source: Scheuer JF 3rd, Sieber DA, Pezeshk RA, Campbell CF, Gassman AA, Rohrich RJ. Anatomy of the facial danger zones: maximizing safety during soft-tissue filler injections. Plast Reconstr Surg. 2017;139(1):50e-8e.

Maximizing Safety

In the lower two-thirds of the nasolabial fold, injections into the deep dermal and superficial subcutaneous plane are generally safe because most of the facial artery course lies beneath muscle and/or above it but in deeper planes; however, in the upper one-third, the artery can become very superficial. Near the alar base, we recommend injecting either intradermally or in the preperiosteal plane. Subcutaneous injections in this area can lead to alar and cheek necrosis if the facial artery or its branches are cannulated or injured. This is also a pathway for ocular embolism through propagation in the angular artery and its anastomoses with dorsal nasal branches. In one review, the nasolabial fold was the second most common injection site leading to tissue necrosis, and, in another study, the third most common site leading to visual loss[3] **(Fig. 7)**.

NOSE

Pertinent Anatomy

In general, the layers of the nose are as follows—epidermis, dermis, subcutaneous fat, muscle and fascia (musculoaponeurotic layer), areolar tissue, perichondrium/periosteum, and cartilage/bone. As discussed previously, the facial artery gives rise to the lateral nasal artery and angular artery through a variety of patterns. The facial artery is on average 3.2 mm lateral to the most lateral point of the ala. More importantly, the facial artery gives rise to the inferior alar branch traveling along the inferior margin of the nostril and lateral nasal artery, which runs in the subdermal plexus 2–3 mm superior to the alar groove over the cephalic margin of the lower lateral cartilage. After this branching point, the facial artery now continues toward the medial canthus as the angular artery while anastomosing with the dorsal nasal arterial system running over the nasal dorsum **(Fig. 8)**. Toriumi et al. illustrated a subdermal vascular plexus that was most prominent in the nasal tip and a larger arterial and venous system of the nasal skin found superficial to the nasal musculature (superficial musculoaponeurotic system layer) in the subcutaneous plane. There is sparse vasculature within the areolar layer beneath the muscular layer aside from what they termed the "deep" or "lateral nasal veins" running cephalic to the lateral crura. Saban et al. described a "marginal artery" coursing over the lower lateral cartilage caudal border

JAYPEE BROTHERS

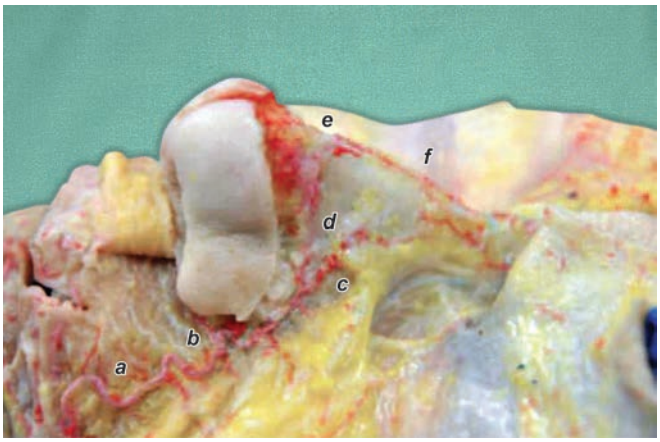

Fig. 8: The facial artery (a) ramifies the inferior alar branch (b) and the lateral nasal artery (d) before becoming the angular artery (c). The dorsal nasal artery (f), lateral nasal arteries (d), and columellar artery (not pictured) form a rich vascular network at the nasal tip in the subdermal layer (e). *Source:* Scheuer JF 3rd, Sieber DA, Pezeshk RA, Campbell CF, Gassman AA, Rohrich RJ. Anatomy of the facial danger zones: maximizing safety during soft-tissue filler injections. Plast Reconstr Surg. 2017;139(1):50e-8e.

toward the tip after branching from either the facial artery or the lateral nasal artery. The dorsal nasal artery (a terminal branch of the ophthalmic artery) emerges from the medial obit and courses over the dorsum above the muscular layer to contribute to the subdermal plexus at the tip.[3]

Maximizing Safety

Given the shallow nature of the vasculature located within the nose, a misplaced injection can lead to disastrous results. Superficial injections compressing or injuring the superficial vasculature in the tip and alar facial groove can lead to blood pressure (BP) and alar necrosis, respectively. Likewise, given the BP, dorsal, and sidewall vessel anastomoses with the ophthalmic artery, intravascular injections in these areas can cause retrograde propagation of filler, leading to ocular ischemia and blindness. Therefore, all lateral injections should be >3 mm above the alar groove and deep. Injections to the BP and dorsum should be deep in the preperichondrial and preperiosteal planes. In several reviews analyzing facial danger zones, nasal filler injections were documented as the leading cause of tissue necrosis and the second leading cause of visual loss after the glabella.[3]

Conclusion

Despite detailed published descriptions of the facial vasculature, the anatomy can be quite variable, and vascular injuries can occur even after the best precautions are taken. Likewise, actual needle depth can be difficult to track and at times unpredictable. Most importantly, practitioners need to recognize complications in a timely manner and take the appropriate measures to minimize what can be a devastating result.[3]

PERIORBITAL REGION

Looking bright and youthful in today's culture impacts quality of life in many patients. Facial aging is a complex and dynamic process. All people age differently as a result of imbalance, disharmony, and disproportion of the aging process between the overlying soft tissue and the underlying bony frameworks. The upper periorbital subunit is one of the first facial regions to show signs of aging, and even minor changes in its structure and volume can distort the perceived emotions and health of patients. An aesthetic and youthful upper periorbital subunit is characterized by a well-defined brow of appropriate height and shape, fullness of the upper periorbit, a crisp and well-defined upper eyelid crease, minimal skin excess, and good skin quality.[5]

In the aging process of this facial area, one group of patients displays signs of aging due predominantly to soft tissue ptosis of the upper eyelid, requiring surgical excision. Another group presents with volume depletion of the soft tissue and bony resorption of the orbit. The loss of septal support, leading to brow prolapse and an exacerbation of upper eyelid fullness and congestion, can also contribute to the aging process. This appearance is characterized by deflation of the upper eyelid as well as hollowing and visibility of the supraorbital bony rim, leading to a sunken, hollow, and skeletonized orbit, which can make the patient appear sickly, anorexic, and old. In recent years, modern facial rejuvenation surgery has evolved toward volume restoration in addition to tissue suspension.[5]

Comprehensive analysis of both soft tissue and bony structural changes is essential for the periorbital rejuvenation. Surgical procedures and office-based nonsurgical procedures form an important basis for periorbital rejuvenation, including cosmeceuticals, chemical peels, laser and light treatments, neurotoxins, and fillers. Improved understanding of the pathophysiology of aging and technical advancements in nonsurgical techniques has enabled us to achieve better and more comprehensive improvement for patients.[5]

The eyes are probably the most important aesthetic unit in the human body. When the eye region appears bright and fresh, the whole person has an aura of health, vitality, and youthfulness. There is a marked transition from the thin eyelid skin to the thicker skin of the eyebrow and cheek. Eyelid skin is the thinnest in the body, often <1 mm thick, and unique in having no subcutaneous fat.[5]

The orbicularis oculi muscle, the sphincter muscle of the eyelids, is arbitrarily divided into three portions—pretarsal, preseptal, and orbital. The pretarsal portion of the muscle is thin, overlies the tarsal plates, and is essential for eyelid position and reflexive blinking. Weakening this portion of the muscle will change the eyelid shape and contour. The preseptal portion courses in concentric curves, anterior to the orbital septum. The muscle is involved in involuntary and voluntary eyelid closure. The orbital orbicularis muscle fibers interdigitate with the frontalis and are primarily

JAYPEE BROTHERS

responsible for forced eyelid closure and depression of the eyebrow.[5]

The blood supply of the eyelids is derived from the facial system, which arises from the external carotid artery, and the orbital system, which originates from the internal carotid artery along branches of the ophthalmic artery. The superficial and deep plexuses of arteries provide a vast blood supply to the upper and lower eyelids. The venous drainage of the eyelids can be divided into two portions—a superficial, or preseptal, system that drains into the internal and external jugular veins, and a deep, or posttarsal, system that flows into the cavernous sinus.[5]

Branches of the ophthalmic and maxillary divisions of the trigeminal nerve provide the sensory innervations of the eyelids. The upper eyelid is innervated by the supraorbital, supratrochlear, and lacrimal nerves. The medial aspect of the upper and lower eyelids is supplied by the infratrochlear nerve. The lateral aspect of the upper eyelid and temple is supplied by the zygomaticotemporal branch of the maxillary nerve. The central aspect of the lower eyelid is supplied by infraorbital nerve, a branch of the maxillary nerve, and the lateral aspect of the lower eyelid is supplied by the zygomaticofacial branch of the maxillary nerve. Facial motor function is provided by the facial nerve and the oculomotor nerve. The superior division of the face innervates the upper eyelids via its temporal (frontal) branches and the lower lids via zygomatic and buccal branches.[5]

Hyaluronic Acid

The ideal substance to treat the periorbital region should be biocompatible, nonimmunogenic, stable, and secure, and should offer good cosmetic results, having long-term duration obtained with minimal complication. Of the available fillers, HA is the one that most approximates all of these characteristics. When used as an injectable filler agent, HA consists of repeating polymer chains of the polysaccharide with internal crosslinks of agents that bind the polymer together. By varying the type of cross-linking material and the amount, the characteristics of the gel can vary in the degree of hardness, amount of lift, duration of survival, and resistance of degradation by heat or enzymes. The use of hyaluronic acid with low viscosity, low concentrations, and high malleability is recommended for this area.[5]

Technique

When treating the periorbital region with HA, the authors perform asepsis and antisepsis with three passes of alcoholic chlorhexidine using sterile gloves and gauzes. They mark a point in the hemipupilar line in the upper eyelid crease and a lateral point at the end of the crease. The use of anesthetic lidocaine and an adrenaline button aims vasoconstriction in the area. The anesthetic effect is not necessary because the caliber of the needles and cannulas are extremely small. 27 G × 50 mm or 30 G × 25 mm cannulas are used. One orifice is made with a needle of the same gauge of the cannula with an inclination in the direction that will be introduced the cannula with an angle of approximately 45°. In this way, the entire dermis is transfixed, reaching the subcutaneous. The application is made by slow retroinjection. A small amount of HA with a concentration of 15 mg/mL (Juvederm Volbella, Allergan) with high flexibility is used, ranging from 0.1 to 0.2 mL per point.[5]

The filling technique for rejuvenation of the lower periorbicular region is held by the authors at deeper levels when compared to the upper region. For this reason, larger volumes of hyaluronic acid are often used. Tracing a point about 2 cm below the lower edge of the orbit in intersection with the lateral line of limbo, a micropuncture is made with the needle toward the lower corner of the eye up to the submuscular plane. An angle of approximately 60° is used for the insertion of the cannula below the orbicularis muscle of the eye. One application with the fanning technique is performed until the direction of hemipupillary line. Volumes ranging from 0.3 to 08 mL of AH are applied in this region. A fourth point is held at a distance of 1.5 cm from the horizontal line from the outer corner of the eye where it meets the malar groove. Strong pressure is applied toward the bone ground at the end of the procedure so that the product can be regularly distributed.[5]

AESTHETICS OF THE PERIORBITAL REGION

The periorbital region is an area where hyperfunction of muscles results in a tired and aged appearance and increased rhytids. Hyperdynamic glabellar musculature can create an angry appearance, while overuse of the lateral eyelid muscles can narrow the eyelid aperture.[6] Treatment with botulinum toxin can lessen the contraction of hyperdynamic periorbital muscles, improve the eyelid aperture and brow position, and decrease periorbital rhytids.[6]

The position and orientation of the eyebrow is related to the relative strength and contraction of the brow depressors versus the brow elevators. The main elevators of the eyebrow are the paired frontalis muscles. The temporoparietalis muscle is a rarely described and highly variable muscle. In conjunction with the frontalis, it raises the eyebrows, widens the eyes, and wrinkles the skin of the forehead. This muscle may display a greater mass in younger individuals. Depression of the eyebrow is accomplished by contraction of the midline procerus muscles and the paired corrugator and orbicularis oculi muscles.[6] Correct placement of appropriate amounts of toxin to minimize rhytids, without negatively affecting eyebrow position, is important.[6]

ANATOMY OF THE PERIORBITAL MUSCLES

Frontalis

The frontalis muscle is a large, vertically oriented, fan-shaped muscle that covers the majority of the forehead

JAYPEE BROTHERS

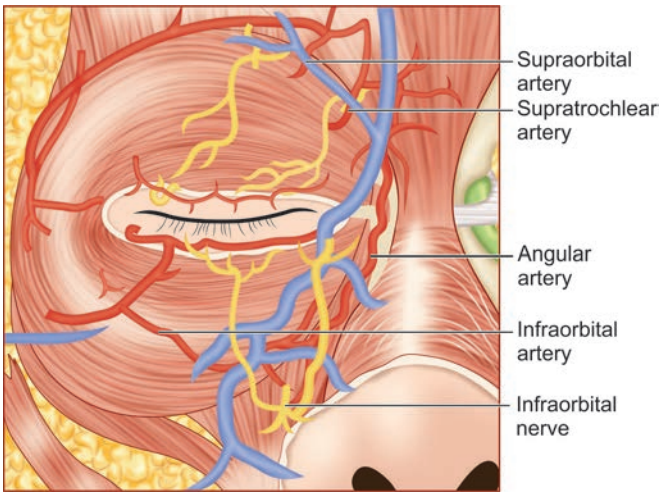

Fig. 9: Main branches of the blood supply of the periorbital region. *Source:* Bravo BS, Rocha CR, Bastos JT, Silva PM. Comprehensive treatment of periorbital region with hyaluronic acid. J Clin Aesthet Dermatol. 2015;8(6):30-5.

and is located within the sheaths of the galea aponeurosis **(Fig. 9)**. It originates from the galea aponeurosis near the anterior hairline and inserts into the forehead skin near the eyebrow. There is no bony origin or insertion for the frontalis muscles. The inferior fibers of the frontalis muscle interdigitate with the procerus and orbicularis muscles. Medially, the two halves of the frontalis muscle have a variable relationship, with some right and left frontalis muscles having no connection, while others interdigitate and even overlap in the lower half of the forehead. The motor innervation to the frontalis muscle is the temporal branch of the facial nerve. Contractions of the superior and inferior portions of the muscle have different actions, with the superior portion causing descent of the anterior hairline and the inferior portion causing elevation of the brow. For this reason, injection of toxin into the superior frontalis muscle can decrease forehead rhytids, without creating brow ptosis.[6]

Corrugator Supercilii

The paired corrugator supercilii muscles are obliquely oriented and are located in the inferomedial brow deep to the inferior portion of the frontalis muscles. These are the only periorbital muscles with a bony connection, with the medial head originating from the frontal bone at the superomedial orbit and the insertion being into the skin of the middle portion of the eyebrow and into the fascia on the deep surface of the frontalis muscle. As the muscle courses laterally, it becomes superficial, with its ending point being at a variable location in the eyebrow skin. The muscle is pierced by the supraorbital and supratrochlear neurovascular bundles. These nerves exit a notch or foramen in the supraorbital rim, pierce the corrugator muscles, and then pierce the frontalis muscles and branches of the nerve travel on the superficial aspect of the frontalis. The motor innervation to the corrugator muscles is from two separate branches of the facial nerve and may present a variable pattern of contralateral or cross-innervation. The medial head of the muscle is supplied by the zygomatic branch of the facial nerve, whereas the lateral portion is supplied by the temporal branch of the nerve. Contraction of the muscle causes vertical grooves in the glabellar skin and imparts an angry expression. Contraction also causes an inferomedial descent of the medial clubhead of the brow. Injection of toxin into the corrugators decreases the vertical glabellar rhytids and causes slight lateralization of the medial brow.[6]

Procerus

The procerus is a midline flat and pyramidally shaped muscle. It is located at the root of the nose and contributes to nasal contour of the upper half of the nose. The procerus originates from the periosteum and perichondrium of the nasal bones and upper lateral cartilages and from the fascia of the nasal superficial musculoaponeurotic system. It inserts into the midline skin overlying the nasal root and thus has no bony attachments. The procerus interdigitates superiorly with the frontalis muscle, inferiorly with the nasalis muscle, and laterally with the depressor supercilii, orbicularis oculi, and deeper corrugator muscles.[1] The motor innervation to the procerus muscle is supplied by the zygomatic branch of the facial nerve. Contraction of the midline muscle is responsible for horizontal glabellar rhytids, descent of the medial brow, and transverse midline nasal rhytids. These are different from the so called bunny lines or lateral nasal rhytids, which appear on the lateral aspect of the nasal dorsum and occur from contraction of the levator labii superioris alaeque nasi muscle. Injection of botulinum toxin into the procerus can decrease the transverse folds at the medial nasal root and can slightly elevate the medial brow.[6]

Orbicularis Oculi

The orbicularis oculi are paired sphincteric muscles that are protractors of the eyelids and depressors of the eyebrows. The muscles are located beneath the thin eyelid and thicker eyebrow skin. The muscles are separated into pretarsal (superficial to the tarsal plates), preseptal (superficial to the orbital septum), and orbital (more peripheral) portions. These designations are not true anatomic separations of muscle but rather names that identify the muscle location. In fact, there are no true separations or septa distinguishing these muscle segments.[6]

The origins and insertions of the orbicularis muscles as well as its anatomical relationships with adjacent structures are complex. The muscle primarily travels in the soft tissues of the eyelids but is fixed medially and laterally to the bony orbital wall by the orbital retaining ligaments.[1] The orbital retaining ligament medially to the midpupillary line is termed the tear trough ligament and is responsible in some individuals for adding to the concavity just inferior to the convex medial orbital fat, also known as the tear trough

JAYPEE BROTHERS

deformity. The orbicularis muscles interdigitate with the corrugator and frontalis superiorly.[6]

Laterally, the orbicularis muscles travel superficial to the temporalis fascia; medially, the muscle covers the depressor supercilii; and inferiorly, the muscles travel between the superficial and deep (suborbicularis oculi fat) fat pads of the cheek. The inferomedial extent of the lower eyelid orbicularis muscles covers the levator labii superioris and the levator labii superioris alaeque nasi muscles.[6]

The motor innervation of the orbicularis oculi muscles is innervated by multiple nerves and has multiple motor endplates. The medial and inferior portions of the muscle are innervated by the zygomatic branch, and the lateral and central portions of the muscle are innervated by the anterior portion of the temporal branch of the facial nerve.[1] Contraction of the orbicularis muscles causes closure of the eyelids and descent of the eyebrows. Contraction of the palpebral marginal portion of the orbicularis causes an involuntary weak eye closure (blink), and contraction of the orbital more peripheral component of the muscle creates a voluntary, sphincteric, and potentially stronger eye closure (squint). The orbital component is responsible for most eyelid wrinkles and for descent of the lateral brow. Injection of the orbicularis oris muscles can decrease dynamic lateral canthal lines, decrease rhytids of the lower eyelid, and elevate the lateral or tail of the brow.[6]

PERIORBITAL INJECTION OF BOTULINUM TOXIN (BOXES 1 AND 2)

Injection of botulinum toxin in the periorbital region can be performed to decrease rhytids, to increase the eyelid aperture, to change the eyebrow position or shape, or to create a combination of these effects. The injection of toxin should affect a diminished muscular contraction of the desired muscle, while not negatively decreasing adjacent muscle contraction.[6]

The relative contraction of the brow elevator (frontalis muscle) and the brow depressors (corrugators, procerus, and orbicularis oculi muscle) affects the position and shape of the eyebrow. The purpose of frontalis muscle injection is usually to diminish transverse forehead rhytids. Toxin injections are usually performed in the superior half of the muscle. Overinjection of toxin, especially in the inferior portion of the frontalis muscle, may result in brow ptosis.[6]

Injection of the corrugator and procerus muscle decreases the vertical and transverse folds at the root of the nose. These injections can also affect medial brow elevation. In that, the medial portion of the corrugator originates from the superomedial orbit, and injection in this region should be deep to treat this part of the muscle. As the muscle travels laterally, it becomes more superficial. For this reason, injection of the lateral portion of the muscle should be more superficial. If the injections are placed too inferiorly, if there is diffusion of toxin, or if there is an anatomical dehiscence in the septum orbitale, toxin can affect the levator aponeurosis of the upper eyelid, causing ptosis of the lid.[6]

Injection of the orbicularis oculi at the lateral canthus can decrease dynamic lateral canthal lines, elevate the lateral

BOX 1: Soft tissue landmarks used as anthropometric reference points.

Beginning superiorly:

- *Vertex (v):* The highest seen point on the head with the head in Frankfort horizontal
- *Trichion (tr):* The junction of the hairline and the forehead in the midline
- *Glabella (g):* The most prominent point of the forehead in the midline between the eyebrows
- *Nasion (n):* The midline point of the junction of the frontonasal suture and the superior nasal bones. Externally, nasion often corresponds to the point of greatest concavity of the nasal dorsum near a line level with the upper lid lash line
- *Orbitale (or):* The palpable point of the lowest margin of the inferior orbital rim
- *Porion (po):* The most superior point of the external auditory meatus.
- *Frankfurt horizontal:* The line connecting porion and orbitale. This line is parallel to the floor for horizontal (FH) anthropometric measurements. It is an approximation of neutral head position in straight gaze
- *Endocanthion (en):* The point of the medial canthus where the upper and lower lids join
- *Pronasale (prn):* The most prominent point of the nasal tip
- *Subnasale (sn):* The deepest point at the junction of the base of the columella and the upper lip in the midline
- *Stomion (sto):* The midline point where the upper lip touches the lower lip
- *Sublabial (sl):* The midline point at the junction of the lower border of the cutaneous lower lip and the superior border of the chin. It is the deepest point of the labiomental groove
- *Pogonion (pg):* The most prominent point of the chin in the midline
- *Gnathion (gn):* The most inferior point of the lower border of the mandible; also called menton (me). In cephalometric analysis, gnathion and menton are two different points on the mandible

Source: Grabb and Smith's Plastic Surgery, 6th edition.

BOX 2: The neoclassical canons frequently used for facial analysis.

- The height of vertex to endocanthion is equal to the height of endocanthion to gnathion (two-section canon)
- The heights of trichion to nasion, nasion to subnasale, and subnasale to gnathion are equal (three-section canon)
- The heights of vertex to trichion, trichion to glabella, glabella to subnasale, and subnasale to gnathion are equal (four-section canon).
- The width of the ala equals one-fourth the width of the distance between the zygomas (nasofacial proportion canon)
- The length of the nose is equal to the height of the ear (nasoaural proportion canon)
- The inclination of the nasal dorsum is equal to the inclination of the ear (nasoaural inclination canon)
- The distance between the medial canthi is equal to the width of the eye fissure (medial to lateral canthus of the eye) (orbital proportion canon)
- The distance between the medial canthi equals the width of the ala (orbitonasal proportion canon)
- The width of the mouth equals 1% the width of the ala (naso-oral proportion canon)

Source: Grabb and Smith's Plastic Surgery, 6th edition

JAYPEE BROTHERS

brow, and increase the eyelid aperture. The orbicularis muscle near the lateral aspect of the lower eyelid is quite superficial, and injections should therefore approximate the superficial location of this muscle. Care should be taken to avoid superficial veins that course through the immediate subcutaneous tissue in the lateral canthal region. It is also important to avoid an injection in this region which is too inferior on the upper cheek. If toxin diffuses too inferiorly, the origin of the zygomaticus major muscle can be affected causing asymmetry of the smile.[6]

Injection of botulinum toxin in the periorbital muscles can significantly improve periorbital aging. The ability to modulate eyebrow position and eyelid aperture, as well as decrease periorbital rhytids and folds, provides an important adjunct to periorbital rejuvenation. A thorough knowledge of muscular anatomy and the position of important anatomical landmarks are necessary to assure efficient injection and minimize complications.[6,7]

CONCLUSION

Although there is heterogeneity of structural changes among individuals, facial anatomy and facial aging follow a regular pattern. This enables the clinician empowered with knowledge of facial anatomy to appropriately modify the effects in a safe manner, respecting any anatomical structures that traverse the region.

REFERENCES

1. Neligan PC. Plastic Surgery. Volume 3: Craniofacial and Pediatric Plastic Surgery, Anatomy of the Head & Neck, 4th edition; 2018. pp. 1,3,5,7,9,10,14.
2. Cotofana S, Lachman N. Anatomy of the facial fat compartments and their relevance in aesthetic surgery. J Dtsch Dermatol Gets. 2019;17(4):399-413.
3. Scheuer JF 3rd, Sieber DA, Pezeshk RA, Campbell CF, Gassman AA, Rohrich RJ. Anatomy of the facial danger zones: maximizing safety during soft-tissue filler injections. Plast Reconstr Surg. 2017;139(1):50e-8e.
4. Lee SH, Lee HJ, Kim YS, Tansatit T, Kim HJ. Novel Anatomic Description of the Course of the Inferior Palpebral Vein for Minimally Invasive Aesthetic Treatments. Dermatol Surg. 2016;42:618-23.
5. Bravo BS, Rocha CR, Bastos JT, Silva PM. Comprehensive treatment of periorbital region with hyaluronic acid. J Clin Aesthet Dermatol. 2015;8(6):30-5.
6. Sykes JM, Trevidic P, Suárez GA, Criollo-Lamilla G. Newer understanding of specific anatomic targets in the aging face as applied to injectables: facial muscles—identifying optimal targets for neuromodulators. Plast Reconstr Surg. 2015;136(5 Suppl):56S-61S.
7. Mathes SJ. Plastic Surgery: The Head and Neck. 2nd edition. W B Saunders Co Ltd; 2006. p. 1000.

JAYPEE BROTHERS

for detailed information on dermatology books, visit our website www.jaypeebrothers.com, for detailed information on dermatology books, visit our website www.jay

ACS(I)
Textbook of
Cutaneous & Aesthetic Surgery

ACS(I) Textbook of Cutaneous and Aesthetic Surgery is the official textbook of the Association of Cutaneous Surgeons (I). It is a comprehensive and major textbook on the subspecialty, with specific reference to its applications in Indian and South Asian skin. In its third edition, all procedures, both basic and advanced, are covered extensively by authors who are experts in the field. An important feature is the inclusion of basic topics related to the practice of dermatosurgery and aesthetic dermatology. Major highlights are sections dealing with heat and cold energy-based procedures, needle-based procedures, and procedures for pigmentation. Another unique feature is the last section on interface of dermatosurgery and cosmetology with patents, legality, academics, and market, which covers several chapters related to training and practical day-to-day aspects of the necessities that a clinic dealing with procedural dermatology has to encounter.

Highlights

- *Three thrust areas:* aesthetics, lasers, and dermatosurgery
- Eighteen sections, each dealing with a specific aspect of procedural dermatology
- A total of 140 main chapters
- Uniformity in the approach to various disorders managed by surgical and aesthetic procedures
- Tips and pearls for performing the procedures effectively and safely and obtaining best results in Indian and South Asian skin.

Manas Chatterjee MD DNB (Dermatology and Venereology) is a Brigadier, Armed Forces Medical Services and Consultant Dermatologist, Base Hospital Delhi Cantt, New Delhi, India. He did his MBBS and MD in Dermatology and Venereology from the Armed Forces Medical College, Pune, Maharashtra, India. He additionally completed his DNB from the National Board of Examinations. Having served in the Armed Forces Medical Services for 33 years, he has served in clinical and teaching appointments at all levels. In his current appointment, he is serving in the Directorate General Armed Forces Medical Services. He has more than 110 publications and 30 chapters to his credit and has edited 6 books. He is a frequent speaker on several subjects in the specialty within India and abroad, with more than 450 invited speaker assignments and counting. He is the current Chief Editor of the Indian Journal of Dermatology, Past Chairman of IADVL Academy, Past Co-Ordinator of IADVL SIG Dermoscopy, and Past President of Association of Cutaneous Surgeons of India among several appointments. He has been awarded Chief of Army Staff Commendation, Dr KN Saxena Memorial Lecture, IADVL President's Appreciation Award, IADVL Teacher par Excellence Award, ACS(I) Dr PN Behl Oration Award and Dr Amarkant Jha Oration, to name a few of his achievements. His areas of interest include Dermatosurgery, Pigmentary Disorders, Dermoscopy, and Immunodermatology.

Biju Vasudevan MD is a Professor and Head, Department of Dermatology, Armed Forces Medical College, Pune, Maharashtra, India. He did his MBBS and MD in Dermatology and Venereology from the Armed Forces Medical College, Pune, Maharashtra, India. He has done his Fellowship in Dermatosurgery from Bangalore Medical College, Bengaluru, Karnataka. He has more than 160 publications and 40 chapters to his credit and has edited 7 books. He is an avid quiz master having conducted about 30 quizzes. He is the current Chief Editor of the Medical Journal Armed Forces India and has been the Deputy Editor of the Indian Journal of Dermatology, Venereology, and Leprology, and Joint Secretary of IADVL, among several appointments. He has been awarded the Dr LN Sinha Memorial Award, The Young Dermatosurgeon Award, and the Systopic Oration at DERMACON 2022. His areas of interest include Dermatosurgery, Dermatopathology, Connective Tissue Disorders, and Psoriasis.

Printed in India

Available at all medical bookstores
or buy online at www.jaypeebrothers.com

JAYPEE BROTHERS
Medical Publishers (P) Ltd.
EMCA House, 23/23-B, Ansari Road,
Daryaganj, New Delhi - 110 002, INDIA
www.jaypeebrothers.com

Join us on facebook.com/JaypeeMedicalPublishers

Shelving Recommendation
DERMATOLOGY

ISBN 978-93-90595-83-9