our website www.jaypeebrothers.com, for detailed information on ophthalmology books, visit our website www.jaypeebrothers.com

JAYPEE

Recent Advances in OPHTHALMOLOGY

15

Editors
HV Nema
Nitin Nema

Contents

1. **COVID-19 and the Eye *(Critical Appraisal of Cause and Effect Relationship)*** *1*

   Lingam Gopal, Su Xinyi, Ivan Seah

   - The Eye as a Portal of Entry for the Virus *2*
   - Clinical Recommendations *3*
   - Ocular Manifestations in Patients with COVID-19 Systemic Infection *4*

2. **Artificial Intelligence in Ophthalmology** **16**

   David Benet, Oscar J Pellicer-Valero, Jorge L Alio

   - Artificial Intelligence Algorithms in Ophthalmology *18*
   - Application of Artificial Intelligence in Ocular Diseases *24*
   - *Discussion*: Potential Advantages, Limitations, and Risks of Artificial Intelligence in the Diagnosis and Treatment of Eye Disease *30*

3. **Robotic Surgery in Ophthalmology and Orbitofacial Surgery** **36**

   Marcus Tan CJ, Gangadhara Sundar

   - Principles and Concepts *37*
   - Current Applications in Ophthalmology *38*
   - Fifth Generation Wireless (5G) *43*
   - The Future *44*

4. **Advances in Corneal Crosslinking** **47**

   Chris HL Lim, Ray Manotosh

   - Proposed Mechanism of Action *48*
   - Indications *49*
   - Techniques and Reported Efficacy *51*
   - Contraindications *56*
   - Risks and Complications *56*

5. **Artificial Intelligence in the Diagnosis of Glaucoma** **61**

   Murali Ariga, Mohana Sinnasamy, Pratheeba Devi Nivean, Henry Henderson

   - Artificial Intelligence and its Subsets *62*
   - Optical Coherence Tomography *69*
   - Visual Field Analysis *70*
   - Current Limitations *71*

JAYPEE BROTHERS

6. Optical Coherence Tomography Angiography in Posterior Uveitis 78
Saba Ishrat, Panchmi Gupta, Jasmine Ge
- Interpretation of Angio-optical Coherence Tomography *79*
- Spectrum of Abnormal Vascular Changes in Uveitides *80*
- Optical Coherence Tomography Angiography versus Fluorescein Angiography in Uveitis *81*
- Optical Coherence Tomography Angiography versus Indocyanine Green Angiography in Uveitis *81*
- Applications of Optical Coherence Tomography Angiography in Ocular Inflammation *83*
- Optical Coherence Tomography Angiography Findings in Inflammatory Choroidal Neovascularization *94*
- Limitations of Optical Coherence Tomography Angiography *97*

7. Serpiginous Choroiditis 103
GVN Rama Kumar
- Epidemiology *104*
- Etiology *105*
- Clinical Features *106*
- Histopathology *107*
- Diagnosis *107*
- Complications *112*
- Management *113*
- Differential Diagnosis *115*

8. Pachychoroid: The Disease Spectrum 120
Anand Rajendran, Ritesh Chainani, Bhanu Pangtey, MY Vishal
Pachyvessels Morphology *121*

9. Glued Intrascleral Haptic Fixation of Intraocular Lens 129
Venkata Prabhakar G, Soosan Jacob
- Principle *130*
- Preoperative Evaluation *130*
- *Technique*: Step-by-Step Approach *130*
- Nuances *132*
- Complications *135*

10. Advances in Phacoemulsification 138
Shreesha Kumar Kodavoor, Tamilarasi S, Ramamurthy Dandapani
- Advances in Phacomachines *138*
- Femtosecond Laser Platforms *140*
- Advances in Microscopes *141*

JAYPEE BROTHERS

- Advances in Capsulorhexis *143*
- Other Technologies for Capsulotomy *145*
- Advances in Nucleus Management in Phacoemulsification *146*
- Advances in Toric Alignment during Phacoemulsification *147*
- Image-guided Cataract Surgery *147*
- Intraoperative Wavefront Aberrometry [Optiwave Refractive Analysis (ORA) System] *149*
- Intraoperative Optical Coherence Tomography *149*

11. Recent Trends in the Management of Diabetic Retinopathy 152

Rajiv Raman, Sudipta Das, Ramachandran Rajalakshmi

- Epidemiology *153*
- Classification and Clinical Features *155*
- Investigations *160*
- Treatment *164*
- Management of Proliferative Diabetic Retinopathy *170*
- Surgical Pathoanatomy *174*
- Surgical Techniques *175*
- Complications *177*
- Outcome *178*

12. Current Trends in the Management of Neovascular Age-related Macular Degeneration 187

Giridhar Anantharaman, Kiran Chandran, Akanksha Rai

- Timeline in the Management of Wet Age-related Macular Degeneration *187*
- Treatment Regimen for Neovascular Age-related Macular Degeneration using Antivascular Endothelial Growth Factor Monotherapy *190*

13. Newer Approaches to Management of Retinal Degenerative Disorders: Gene Therapy and Cell Replacement Therapy 204

Lingam Gopal, Su Xinyi, Mayuri Bhargava, Zeng Ping liu, Swathi Lingam

- **Gene Therapy** *205*
  - Polymorphisms and Mutations *205*
  - Gene Therapy Approaches *208*
- **Cell Therapy for Retinal Disorders** *213*
  - Stem Cells and Regeneration *213*
  - The Eye as a Target for Cell-based Therapy *213*
  - Cells Proposed to be Replaced *215*
  - Rationale for Cell-based Therapy *216*
  - Replacement versus Rejuvenation *222*
  - Immunogenicity of Retinal Progenitor Cells Transplantation *224*

JAYPEE BROTHERS

14. Ocular Myasthenia Gravis 229
Asmita Mahajan, Pradeep Sharma
- Pathophysiology *230*
- Clinical Features *230*
- Diagnosis *231*
- Electrophysiologic Testing *233*
- Imaging Studies *233*
- Treatment *234*

Index 239

JAYPEE BROTHERS

11

CHAPTER

Recent Trends in the Management of Diabetic Retinopathy

Rajiv Raman, Sudipta Das, Ramachandran Rajalakshmi

ABSTRACT

Diabetic retinopathy (DR) is a devastating ocular complication of diabetes mellitus and is one of the leading causes of preventable blindness among working-age group population around the world. Despite the increased understanding of this disease, identification of successful treatment still remains a significant risk to global blindness. In this chapter, we have tried to review the existing ophthalmologic literature on treatment of DR to provide perspective on the relative prioritization of the various treatments in the contexts seen in present clinical practice. The newest classification incorporating the state-of-the-art technologies has made a paradigm shift in DR management. In general, laser photocoagulation continues to have a role though pharmacotherapy with the intravitreal anti-vascular endothelial growth factor (anti-VEGF) molecules have revolutionized present day DR management. Surgical intervention is reserved for advanced proliferative stages and in those situations that fail to respond to pharmacotherapy, laser, or combination therapy. Recent developments involving newer retinal diagnostics, novel pharmaceutical agents, and ocular drug delivery methods are proving beneficial in optimizing both initiation and maintenance of DR management. From surgical perspective, newer instruments, cutters, operating microscopes, viewing systems, and vitrectomy machines have started providing adequate surgical control, more precision, less surgical time, and complications resulting in better anatomical and visual outcome.

Keywords: Diabetic retinopathy, blindness, classification, anti-vascular growth factor, midrovascular complication, vitrectomy.

INTRODUCTION

Diabetic retinopathy (DR) is the most common microvascular complication of diabetes, occurring in both type 1 and type 2 diabetes, caused by prolonged uncontrolled hyperglycemia and other risk factors. Cataract, glaucoma, ocular surface disorder (dry eye), ischemic optic neuropathy, cranial mononeuropathies/extraocular muscle palsy, retinal vascular disorders, and most importantly, DR are the common ocular associations of diabetes.

JAYPEE BROTHERS

Diabetic retinopathy is the one of the leading causes of blindness in developing countries like India.[1] It is the ocular manifestation of end organ damage in patients with diabetes mellitus. It is associated with endothelial dysfunction and vascular occlusion leading to retinal hemorrhages, edema, and upregulated levels of vascular endothelial growth factor (VEGF) leading to new vessel formation which leak profusely.[2] DR is clinically staged into various types ranging from mild, moderate, and severe nonproliferative diabetic retinopathy (NPDR) and the proliferative stage depending on the extent of vascular abnormalities. Diabetic macular edema (DME) is a vision threatening complication of DR develops as a result of focal or diffuse vascular leakage in the macula. New vessel formation which occurs in the advanced stage of DR (PDR) gives rise to complications like vitreous hemorrhage, neovascular glaucoma (NVG), and tractional retinal detachment (TRD) which severely compromise visual acuity. A variety of investigation modalities like the fundus imaging, fundus fluorescein angiography (FFA), and optical coherence tomography (OCT) guide the clinician in determining the extent of progression and staging of the disease. Control of the systemic parameters can help to halt the progression of the disease in the early stages. Treatment modalities like focal laser photocoagulation, intravitreal anti-VEGF, and steroid injections are useful modalities to preserve and improve the vision in DME.[3] Progression to PDR requires treatment intervention in the form of panretinal photocoagulation (PRP) or surgical intervention in case of complications like nonresolving vitreous hemorrhage, TRD, or premacular hemorrhage.

EPIDEMIOLOGY

Epidemiological studies have described the natural history of DR. Studies done in the Western population have shown that the prevalence of DR increases with duration of diabetes, and nearly all persons with type 1 diabetes and >60% of those with type 2 diabetes have some retinopathy after 20 years of diabetes.[4]

A recent systematic review of 35 population-based studies conducted worldwide has reported the prevalence of DR and PDR, among individuals with diabetes, as 34.6% and 7.0%, respectively.[5] Men are at a higher risk of developing DR as opposed to women as reported in several studies.[6]

In the Indian scenario, the prevalence of DR is lower when compared to other ethnic populations. Prevalence studies have been carried out mostly in The Southern India to assess the burden of DR on the urban and rural population.[6,7] A study carried out in Chennai by Raman et al. has reported a prevalence rate of 18% in people with diabetes and 3.5 % in the general urban population above 40 years.[7] Gadkari et al. in a Pan India screening study carried out in 2014 have reported the prevalence of DR as 21.7% in people with diabetes in a predominantly urban population.[8] This shows that approximately 1 out of 5 people with diabetes in India can have DR.

JAYPEE BROTHERS

Although urban Indian population-based studies suggest that the prevalence of DR is lower, given the large number people with diabetes in India (over 77 million) (IDF-2019 Atlas), even with the lower prevalence rates (18%), this would translate to over 14 million people with DR.[9]

Moreover, with the present change in lifestyle, diabetes strikes the Indians at a younger age.[10] Younger age of onset of diabetes implies that these people have a greater-risk of developing various complications due to diabetes during their prime productive life.[10,11]

Risk Factors

The onset and progression of DR may be influenced by many systemic factors. The major consistent risk factors for DR reported from various epidemiologic studies include the duration of diabetes, uncontrolled hyperglycemia, hypertension, dyslipidemia, diabetic kidney disease, anemia, and pregnancy. The most important nonmodifiable risk factor associated with DR is the duration of diabetes. Modifiable risk factors for DR include hyperglycemia, hypertension, and dyslipidemia. Other risk factors include ethnicity, genetic factors, etc.

The prevalence and incidence of retinopathy increase with increasing duration of diabetes. Duration of diabetes is the most important risk factor for development of DR. The proportion of persons with DR having more severe forms of retinopathy increases with increasing duration of diabetes. The Wisconsin Epidemiologic Study of Diabetic Retinopathy (WESDR) reported a high prevalence of DR of 50.3% and showed that a longer duration of diabetes is associated with an increasing 10-year incidence of any DR over duration up to 10 years in younger onset diabetes.[11] In the older onset diabetes taking insulin, longer duration of diabetes was associated with decreased risk of incidence of any DR, and progression of retinopathy.[11] Various studies report low prevalence of DR in South Asian Indians and Singapore Malay populations. Hispanic Caucasian populations have the highest reported prevalence across the world.[12] A few studies have reported that at the time of diagnosis of diabetes, prevalence rates of DR in type 2 are higher than in patients with type 1 diabetes.[13]

Studies report a higher incidence of DME in patients taking insulin.[14] However, this does not mean that there is an association between insulin and DR but it is due to the uncontrolled diabetes in patients that they require insulin. Prevalence of DME ranges from 0% in younger onset diabetes whose duration of diabetes is <5 years to 29% in patients whose duration of diabetes is 20 or more years.[14] Thus the occurrence of DME also depends on the duration of diabetes.[11,14]

The Singapore Eye Disease Study reported that Indian ethnicity, glycated hemoglobin (HbA1c), duration of diabetes, blood glucose, and systolic blood pressure are independent risk factors for any DR.[12] Blood sugar and blood pressure control are the key modifiable risk factors associated with the development of DR.[15] The American Diabetic Association recommends

JAYPEE BROTHERS

HbA1c of 7% or lower as the target for glycemic control in most patients.[16] Chiefari et al. have reported that patients with type 2 DM who are carriers of high-mobility group A1 (HMGA1) variant have a low-risk of PDR in comparison to DM patients who do not carry this mutation. This explains the role of genetic factors in determining the progression of the disease.[17]

Increased duration of DM is also associated with increased prevalence of progression to PDR. The highest 10-year incidence of progression to PDR (49%) is when the duration of diabetes is between 10 and 14 years whereas its 10% when the duration of diabetes is <4 years. Progression also depends on the type of clinical features noted wherein patients with intraretinal microvascular abnormalities (IRMA) have a higher chance of progression to PDR as compared to patients with venous beading.[18] The Diabetic Retinopathy Clinical Research Network (DRCR.net) protocol S study has reported that worse baseline levels of PDR were associated with an increased risk of PDR progression, irrespective of the treatment modality used in patients with PDR.[19]

CLASSIFICATION AND CLINICAL FEATURES

The International Classification of Diabetic Retinopathy (ICDR) and DME disease severity scales have been developed by Wilkinson et al.[20] **(Table 1)**. These are based on the findings on routine clinical ophthalmic examination. There are five scales with increasing risk of retinopathy. The first level is no apparent retinopathy, and second level is mild NPDR that includes only microaneurysms (MA). The third and fourth levels are moderate and severe NPDR. The level of severe NPDR carries with it the most risk for progression to the fifth level PDR.

Nonproliferative Diabetic Retinopathy

Nonproliferative diabetic retinopathy is characterized by presence of MA, dot and blot hemorrhages, hard exudates, cotton wool spots, and vascular

TABLE 1: Diabetic Retinopathy Disease Severity Scale.

Proposed disease severity level	*Findings observable on dilated ophthalmoscopy*
• No apparent retinopathy (No diabetic retinopathy)	• No abnormalities
• Mild nonproliferative diabetic retinopathy (NPDR)	• Microaneurysms only
• Moderate nonproliferative diabetic retinopathy (NPDR)	• More than just microaneurysms but less than severe nonproliferative diabetic retinopathy
• Severe nonproliferative diabetic retinopathy (NPDR)	• *Anyone of the following*: (4:2:1 rule) – More than 20 intraretinal hemorrhages in each of 4 quadrants; – Definite venous beading in 2+ quadrants; – Prominent intraretinal microvascular abnormalities (IRMA) in 1+ quadrant and no signs of PDR
• Proliferative diabetic retinopathy (PDR)	• *One or more of the following*: – Neovascularization – Vitreous/preretinal hemorrhage

JAYPEE BROTHERS

changes in the form of beading or looping, IRMA, and retinal edema in varying proportions. MA are the earliest detectable clinical signs in patients with DR. They are located in the inner nuclear layer of the retina but their presence can only be confirmed on FFA in which they appear as tiny hyperfluorescent spots mainly adjacent to the areas of capillary nonperfusion.[21] Retinal hemorrhages can either be of a flame shaped configuration in which they are located in the superficial nerve fiber layer or dot-blot hemorrhages in which case they are located in the middle retinal layers. Hard exudates are visible as yellowish white lesions located between the inner plexiform and inner nuclear layers. They occur secondary to chronic localized leakage from the retinal vessels. Progressive capillary nonperfusion is accompanied by development of cotton-wool spots, venous beading, and IRMA. IRMA are dilated micro vessels that seem to function as collateral channels mainly in areas of ischemia. Retinal edema is caused due to accumulation of fluid between the outer plexiform and the inner nuclear layers, which can later involve all layers of retina.[22] **Figure 1** shows the various stages of NPDR.

Proliferative Diabetic Retinopathy

Proliferative diabetic retinopathy that occurs with further retinal ischemia is characterized by the presence of new vessels either on the optic nerve head or within one disk diameter (DD) from it in which case its termed as neovascularization of the disk (NVD) or new vessel growth further than one DD away from disk along with the major vascular arcades termed as neovascularization elsewhere (NVE) **(Fig. 2)**. These fragile new vessels along with fibrous tissue grow along the posterior hyaloid and tend to rupture easily giving rise to vitreous hemorrhage or in case of a posterior vitreous detachment can get pulled anteriorly with the retina giving rise to tractional



Fig. 1: Nonproliferative diabetic retinopathy (NPDR).



Fig. 2: Proliferative diabetic retinopathy (PDR).
(NVD: neovascularization of the disk; NVE: neovascularization elsewhere)

JAYPEE BROTHERS

detachment of the retina.[21] If the neovascularization involves the anterior segment including angles of anterior chamber, it may lead to NVG, which may lead to severe unrelenting pain and irreversible blindness.

High-risk PDR is defined by the presence of one of the following:

- Neovascularization at the optic disk > 1/4–1/3 disk area
- Vitreous or preretinal hemorrhage, with less extensive NVD, or NVE-1/2 disk area or more in size
- Rubeosis iridis (abnormal blood vessels in the iris and the angles).

Diabetic Macular Edema

Diabetic macular edema is defined as retinal thickening at or within one DD of the center of the macula or the presence of definite hard exudates. DME occurs after breakdown of the inner blood-retinal barrier, resulting in accumulation of extracellular fluid in the macula.

Diabetic macular edema can be either being center involving DME (CIDME) or noncenter involving DME (NCIDME) based on OCT **(Table 2)**.[22] **Figure 3** shows the fundus images of CIDME and NCIDME.

TABLE 2: Classification of diabetic macular edema.

Diabetic macular edema (DME) classification by clinical appearance	
No apparent DME	No retinal thickening or hard exudates at macula
Mild DME	Some retinal thickening or hard exudates in posterior pole but distant from the center of the macula
Moderate DME	Retinal thickening or hard exudates approaching the center of the macula but not involving the center
Severe DME	Retinal thickening or hard exudates involving the center of the macula
DME classification by optical coherence tomography (OCT)	
Noncentral involving DME	Retinal thickening in the macula that does not involve central subfield zone in OCT (1 mm diameter)
Center involving DME	Retina thickening in the macula that involves the central subfield zone in OCT (1 mm diameter)

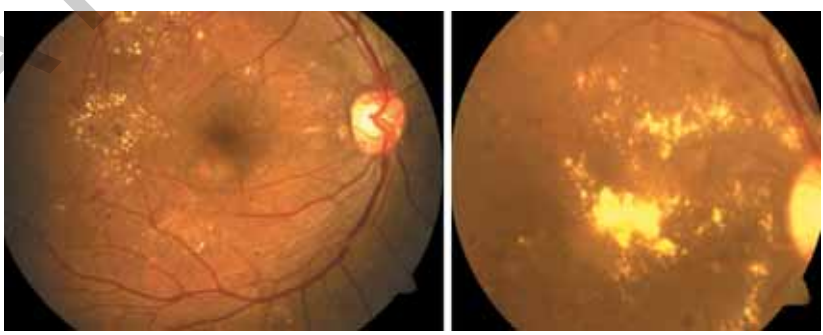

Noncenter involving DME **Center involving DME**

Fig. 3: Diabetic macular edema (DME).

JAYPEE BROTHERS

In CIDME, there is loss of foveal contour, cystic spaces involving center of fovea, neurosensory detachment involving the center of fovea, and retinal thickening in which the central subfield thickness on OCT >290 μm for women and >305 μm in men on spectral domain OCT (SD-OCT) (Zeiss Cirrus). In Heidelberg Spectralis, the central foveal thickness (CFT) parameters shows ≥305 μm in women and ≥320 μm in men.[23]

In NCIDME, there is definite retinal thickening within 3,000 μm of the center of the macula but not involving the center of the macula. On SD-OCT, it is seen as cystic spaces and/or retinal thickening in noncentral macular subfields.[24]

According to Wilkinson's classification, DME can be divided into mild, moderate, and severe based on the distance of the retinal thickening or hard exudates from the center of the macula. Tab earlier the term clinically significant macular edema (CSME) coined by Early Treatment of Diabetic Retinopathy Study (ETDRS) was used. CSME was defined based on slit lamp biomicroscopy as: "(1) thickening of the retina at or within 500 μm of the center of the macula; or (2) hard exudate at or within 500 μm of the center of the macula associated with thickening of adjacent retina; or (3) a zone of retinal thickening 1 disk area or larger, any part of which is within 1 DD of the center of the macula."[25] The ETDRS found that macular laser photocoagulation was effective in reducing visual loss from CSME.

In general, the type of leakage associated with DME can either be of a focal or a diffuse type. Focal diabetic edema is mainly caused due to leakage from MA and is associated with lipid exudates in a circinate pattern. Diffuse edema is the result of extensive capillary leakage.

Figures 4A and B demonstrates the stages and varying severity of nonsight threatening DR and sight-threatening DR (STDR).

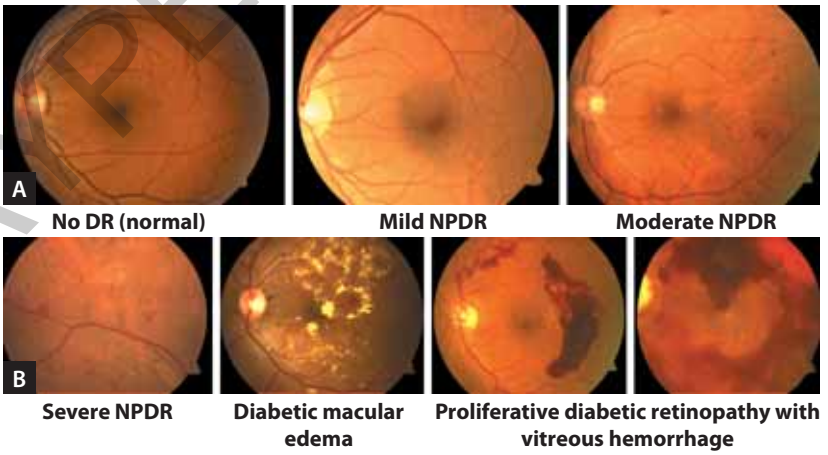

Figs. 4A and B: (A) Nonsight threatening diabetic retinopathy (DR); (B) Sight-threatening diabetic retinopathy (STDR).
(NPDR: nonproliferative diabetic retinopathy)

JAYPEE BROTHERS

TABLE 3: Screening schedule for eye examination in diabetes.

Patient classification	*Initial retinal examination*	*Follow-up retinal examination*
Type 1 diabetes	Within 3–5 year after diagnosis	Annually; more frequently if indicated by ophthalmologist
Type 2 diabetes	At time of diagnosis of diabetes	Annually; more frequently if indicated by ophthalmologist
Pregnancy in pre-existing diabetes (but not in GDM)	Prior to conception or early in the during first trimester	• No retinopathy prior to conception or in early first trimester; every 12 months • Every 3 months, if mild NPDR • Every 1–2 months, if severe NPDR or worse or as advised by ophthalmologist

(GDM: gestational diabetes mellitus; NPDR: nonproliferative diabetic retinopathy)

Screening for Diabetic Retinopathy

All patients with a history of diabetes mellitus, irrespective of the type of diabetes need regular repetitive retinal examinations. Despite advancements in the delivery of ophthalmological care, DR remains a major cause of preventable blindness throughout the world. As individuals with even STDR may not have any symptoms, life-long evaluation by retinal screening of diabetic individuals is a valuable and necessary strategy. **Table 3** shows the frequency of retinal examination schedule. Fundus examination for DR assessment is done by direct ophthalmoscopy, indirect ophthalmoscopy, and slit-lamp biomicroscopy. Retinal color photography with a fundus camera is helpful in documenting the retinal lesions in DR. A wide range of fundus cameras are available for screening.

Telemedicine for Diabetic Retinopathy Screening

An advantage of technological advancements and digital retinal photography is the ability to transmit images to a centralized reading center for grading. The Joslin Diabetes Center in Boston is the pioneer in teleophthalmology, developing the Joslin Vision Network (JVN). Teleophthalmology is a diagnostic evaluation, which includes a remote digital retinal imaging done by trained technicians, using a digital fundus camera, transmission of images through internet to the centralized grading center for grading of DR, assessment and advice by the ophthalmologist/retina specialist. Telemedicine screening for early detection of DR, particularly of the rural population is being done by many major organizations in India.

Artificial Intelligence in Diabetic Retinopathy Screening

In the recent past, there has been an increasing interest in the development of automated analysis software using computer machine learning/artificial intelligence (AI) or deep neuronal learning for analysis of retinal images

JAYPEE BROTHERS

in people with diabetes by companies such as Google, Eyenuk, IDx, Microsoft, etc. The machine after being exposed to a lot of annotated images learns to grade DR by itself. These algorithms can automatically provide DR severity and referral recommendation to meet ophthalmologists. IDx is the first AI software to get US Food and Drug Administration (US-FDA) approval for DR screening in 2018.

INVESTIGATIONS

Early detection of DR is a key intervention, which can prevent vision loss. DR lesions can be detected using color fundus imaging, OCT, and invasive modalities such as FFA and appropriate treatment can be started. Following are some of the modalities, which can be used for screening of DR and investigations for management of STDR.

Color Fundus Photography

Stereoscopic color fundus photography (CFP) in seven standard fields (30°) are a gold standard method for detection of DR changes as stated by the ETDRS group.[25] CFP is an effective tool in demonstrating clinical signs of DR such as hemorrhages, cotton wool spots, hard exudates, and early neovascular tufts. Standard CFP provides a 30–50° image which includes the macula and optic nerve.[26] Two or three-fields fundus photography are currently recommended for screening instead of single field fundus photography as they provide better sensitivity and specificity in comparison.[27]

Nonmydriatic fundus imaging has emerged as a popular tool for screening DR, but has limitations including a higher technical failure rate resulting from small pupils and media opacities. Mydriatic fundus imaging gives a sensitivity of at least 80% in the detection of any grade of DR but caution has to be applied as there have been instances of mydriatic-induced angle closure.[28] Many models of low cost sleek hand-held and smartphone-based fundus camera are also in use for DR screening.

Color fundus imaging includes various subtypes including stereoscopic imaging, digital fundus photography, and confocal scanning laser ophthalmoscopy (CSLO). Stereoscopic fundus imaging provides a pseudo three-dimensional (3D) image formation from an ordinary two-dimensional fundus photograph by simply shifting the fundus camera a few millimeters between sequential photographs.[29]

Digital fundus photography can provide up to 100–200° field of view of the retina. Advent of ultra-wide field imaging using newer cameras such as Pomerantzeff camera,[30] Retcam (Clarity Medical Systems, Inc., Pleasanton, CA, USA), Optos Daytona Plus camera (Optos PLC, Dunfermline, UK) **(Fig. 5)**, and the Staurenghi lens (Ocular Staurenghi 230 SLO Retina Lens; Ocular Instruments Inc., Bellevue, WA, USA) have made a radical change in the way we view fundus now-a-days compared to what we used to do before.[31] CSLO uses a laser light and forms an image by a detailed point-by-point

JAYPEE BROTHERS

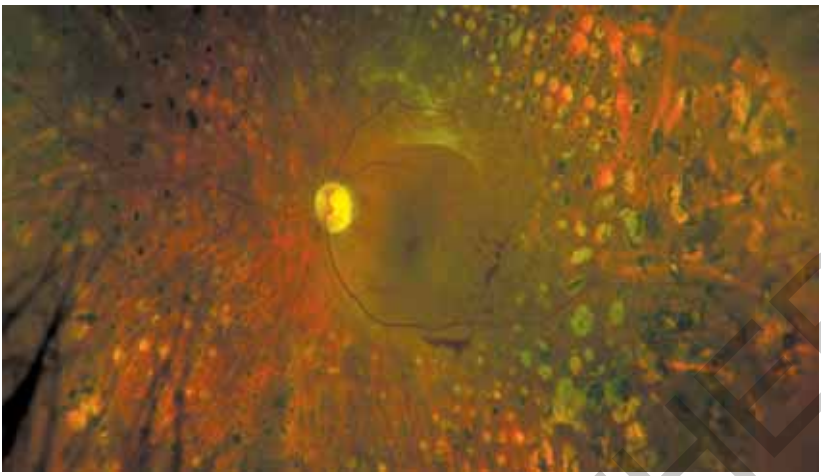

Fig. 5: Ultrawide fundus image of a post-PRP/PDR with fibrous proliferans with preretinal hemorrhage.
(PDR: proliferative diabetic retinopathy; PRP: panretinal photocoagulation)

scanning of the entire field and then capturing the reflected light through a small confocal pinhole, which in turn suppresses any scattered or reflected light outside the focal plane that could blur the image. The advantages include improved image quality, patient comfort, 3D imaging and video capability, and effective imaging of patients who do not dilate well.

Reports have shown that multicolor imaging of the fundus is superior to traditional color fundus photos in detecting and localizing foveal cysts, and helping in better delineation of clinical signs of DR.[32] Pece et al. have reported that DME eyes with higher fundus autofluorescence (FAF) at fovea had worse visual prognosis.[33] Multicolor imaging is thus a potential tool for screening DR in addition to CFP.

Fundus Fluorescein Angiography

Fundus fluorescein angiography (FFA) has been a major modality in detecting retinal ischemic changes and new vessel formation in various retinal vascular disorders including DR. It helps us to delineate areas of capillary nonperfusion and widening of foveal avascular zone (FAZ) in the macula. The landmark clinical trials of the DRS and ETDRS used fluorescein angiography (FA) in classifying disease severity, guiding laser therapy, and evaluating the response to therapy.[34,35] In DME, the macula on FFA shows MAs and IRMA interspersed between areas of focal or diffuse hyperfluorescence due to leakage from incompetent circulation. The ETDRS study used FFA as a guide for focal laser to leaking MAs and macular grid laser to areas of diffuse leakage and capillary nonperfusion with therapeutic benefit.[35,36] Wide field FFA is also critical in delineating peripheral ischemic areas as these areas have a role in central macular pathology due to liberation of growth factors and VEGF.[37] The European Society of Retina Specialists (EURETINA) recommend FFA to

JAYPEE BROTHERS

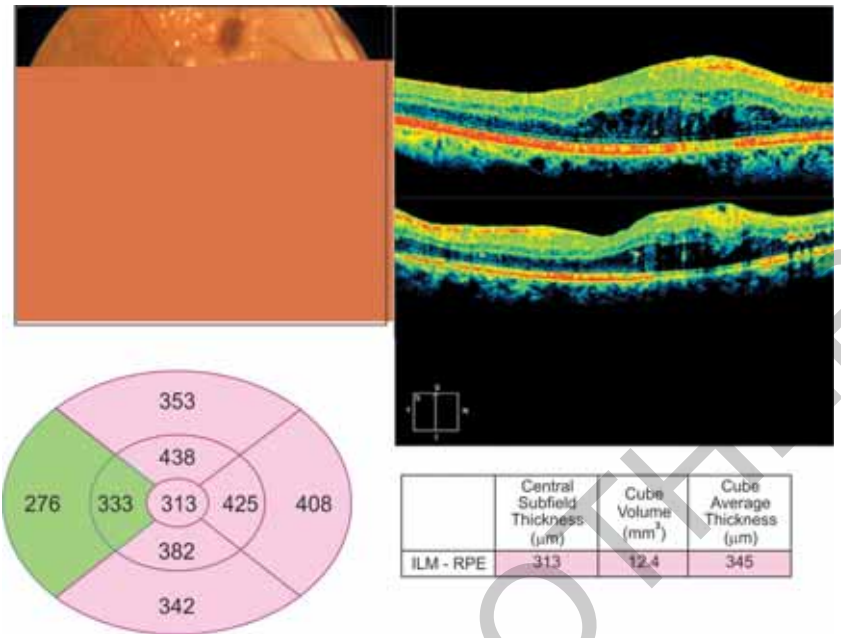

Fig. 6: Retinal color photography and optical coherence tomography (OCT) images of noncenter involving diabetic macular edema.
(ILM-RPE: internal limiting membrane-retinal pigment epithelium)

be an important diagnostic tool for assessing the function of the central and peripheral retina and it must be performed prior to the initiation of therapy to delineate and stage the DME and DR pathology.[3] FFA has contraindications such as renal failure, pregnancy, allergy to fluorescein dye, and must be used with caution in susceptible patients. A proper skin test of sodium fluorescein before FFA has become mandatory in almost all centers around the world.

Optical Coherence Tomography

Optical coherence tomography is used to obtain high-resolution cross-sectional images of the retina in a noninvasive manner. The use of SD-OCT has superseded the time domain OCT that was used in the past because of its faster scanning speed and improved axial and lateral scan resolution. OCT in DME has probably become the single most important tool as it helps in classification of DME and monitoring the progression and treatment evaluation in anti-VEGF for DME **(Fig. 6)**.[22] OCT also gives information regarding the CFT/central retinal thickness (CRT) which is affected by various parameters such as the presence or absence of subretinal fluid and intraretinal fluid. It also helps in prognosticating the disease severity by documenting the status of the inner retinal layers, external limiting membrane, and the ellipsoid zone. There are some landmark clinical trials based on OCT in DME. In RIDE/RISE studies, treatment was performed monthly

JAYPEE BROTHERS

with intravitreal anti-VEGF, but additional laser treatment was performed on as and when needed *pro-re-nata (*PRN) basis based on CRT in OCT.[38] CRT has also been used as the secondary efficacy end point in the VISTA/VIVID DME trials.[39] Along with best corrected visual acuity (BCVA), most major trials have considered increased CRT to be the re-treatment criteria. The finding that presence of subretinal fluid at baseline correlates with a better BCVA at the end of first year has been reported in the RESTORE study and has been confirmed by the RISE/RIDE trials.[38,40]

EURETINA guidelines recommend use of OCT in the diagnosis of DME along with a baseline FFA and fundus biomicroscopy.[3] Good baseline predictors for a good treatment response in terms of good BCVA are SRF and/or small intraretinal cysts and/or vitreomacular adhesion at baseline.[41,42] Factors that may predict worse visual gain after therapy include the disorganization or disruption of the inner retinal layers (DRIL), disruption of the inner and outer photoreceptor segments and/or ELM and subfoveal thin choroid at baseline.[42,43] EURETINA recommends that PRN (Pro-re-nata) treatment based only on CFT changes for the management of DME but individual OCT features have to be analyzed before making the retreatment decision.[3] **Table 4** provides the American Academy of Ophthalmology guidelines for the indication of use for FFA and OCT in DR management.[44]

Optical Coherence Tomography Angiography

Optical coherence tomography angiography (OCTA) is a noninvasive 3D imaging modality for visualization of the retinal and choroidal vascular networks at different depths **(Fig. 7)**. OCTA enables detection of areas of

TABLE 4: American Academy Guidelines for fundus fluorescein angiography (FFA) and optical coherence tomography (OCT).

Investigation	*Situation*	*Usually*	*Occasionally*	*Never*
FFA	Investigate unexplained vision loss	√	–	–
	Guide laser treatment for DME	√	–	–
	Identify clinically suspect NVE/NVD	√	–	–
	Identify area of capillary nonperfusion	–	√	–
	Screen for DR	–	–	√
OCT	Investigate unexplained vision loss	√	–	–
	Identify areas of vitreomacular traction	√	–	–
	Monitor response to treatment	√	–	–
	Evaluate patients difficult to examine	√	–	–
	Investigate other possible causes of macular edema	–	√	–
	Screen for DR	–	–	√

(DME: diabetic macular edema; DR: diabetic retinopathy; NVD: neovascularization of the disk; NVE: neovascularization elsewhere)

JAYPEE BROTHERS

for detailed information on ophthalmology books, visit our website www.jaypeebrothers.com, for detailed information on ophthalmology

Recent Advances in OPHTHALMOLOGY

15

Salient Features

- Contains 21 well-illustrated chapters on current topics in ophthalmology
- Describes causes and management of post-LASIK ectasia
- Many forms of lamellar keratoplasty have been introduced
- Describes step-by-step use of glaucoma drainage devices in management of intractable glaucoma
- Describes recent advances in calculation of IOL power for implantation
- Includes chapters on cataract surgery in challenging situations
- Discusses how to adopt the results of clinical trials in real-life situations
- Describes the role of optical coherence tomography-angiography in retinal diseases
- Students and ophthalmologists can upgrade their knowledge effectively for the better care of their patients.

HV Nema MS has a distinguished academic career and is well known for teaching, research and publications. Formerly, he was Professor and Head, Department of Ophthalmology, Institute of Medical Sciences, Banaras Hindu University, Varanasi, Uttar Pradesh, India. He has served as a Consultant Editor/Advisory Editor to Indian Journal of Ophthalmology, Afro–Asian Journal of Ophthalmology and Indian Journal of Optometry. He has published more than 6 dozen papers in the national and international journals. He is an established author in the field of ophthalmology. *Ophthalmic Syndromes* (Butterworth, London, UK, 1973) and *Textbook of Ophthalmology* (6th edition, 2012, Jaypee Brothers Medical Publishers, New Delhi, India) are some of his popular books. He has edited 14 volumes of *Recent Advances in Ophthalmology*, 3 editions of *Diagnostic Procedures in Ophthalmology, Eye in Systemic Disorders* (Wiley India), and books on *Cornea and Sclera, Diseases of Uvea, Glaucoma, Cataract Surgery* and *Retina* which were well received by readers and favorably reviewed in national and international journals. He has delivered guest-lectures in many universities.

Nitin Nema MS DNB is a Professor, Department of Ophthalmology, Sri Aurobindo Institute of Medical Sciences, Indore, Madhya Pradesh, India. He is an experienced Vitreoretinal Surgeon. He did his Fellowship from Aravind Eye Hospital and PG Institute, Madurai, Tamil Nadu. He gained clinical and research experience from the University of Illinois at Chicago, and the University of Wisconsin at Madison in the USA. He was awarded a Fellowship by the All India Ophthalmological Society to work on a Project on Uveitis at Sankara Nethralaya, Chennai. He was awarded Dr Mohan Lal Gold Medal for the best paper by UP State Ophthalmological Society. He had authored (in collaboration with Dr HV Nema) 2 textbooks: *Anatomy of the Eye and Adnexa* (3rd edition) and *Textbook of Ophthalmology* (6th edition), and edited 13 volumes of *Recent Advances in Ophthalmology*, 3 editions of *Diagnostic Procedures in Ophthalmology*, and books on *Cornea and Sclera, Diseases of Uvea, Glaucoma, Cataract Surgery* and *Retina*.

Printed in India

Available at all medical bookstores
or buy online at www.jaypeebrothers.com



JAYPEE BROTHERS
Medical Publishers (P) Ltd.
EMCA House, 23/23-B, Ansari Road,
Daryaganj, New Delhi - 110 002, INDIA
www.jaypeebrothers.com

Join us on facebook.com/JaypeeMedicalPublishers

Shelving Recommendation
OPHTHALMOLOGY

