website www.jaypeebrothers.com, for detailed information on surgery books, visit our website www.jaypeebrothers.com

YEARBOOK

Yearbook of Vascular and Endovascular Surgery-3

2021

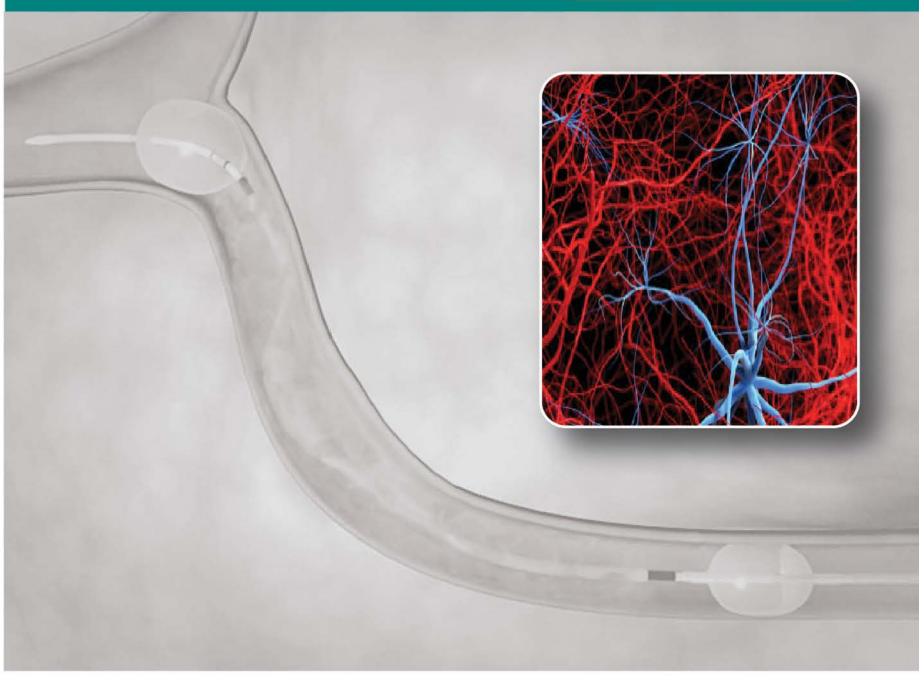

R Sekhar

JAYPEE

Contents

1. Current Evidence for Anticoagulation Following Infrainguinal Revascularization 1

Pinjala Ramakrishna

Endovascular and Antithrombotic Therapies *6*

Role of Low-molecular-weight Heparin in the Infrainguinal Revascularization *9*

Reocclusion/Restenosis after Infrainguinal Revascularization *9*

2. Surgical and Endovascular Interventions for Chronic Mesenteric Ischemia 15

Himanshu Verma, Ramesh K Tripathi

Anatomical Basis of Chronic Mesenteric Ischemia *15*

Natural History *16*

Open Surgical Treatment *17*

Endovascular Treatment *20*

Comparison Between Open and Endovascular Interventions in Mesenteric Revascularization *24*

3. Medical Management of Venous Insufficiency 28

Renuka Munshi, Chaitali Pilliwar

Incidence of Venous Insufficiency *30*

Pharmacological Treatment of Chronic Venous Disorders *30*

Medical Management of Chronic Venous Disorder *43*

4. Pelvic Congestion Syndrome 54

M Ayman Fakhry, Sohiel Nagib

Background *54*

Definition *54*

Prevalence *55*

Venous Drainage of the Pelvis *55*

Etiology *55*

Pathophysiology *56*

Hemodynamic Changes *56*

Classification and Structural Changes *56*

Diagnosis *58*

Differential Diagnosis of Chronic Pelvic Pain *61*
Treatment *61*
Male Patterns of Pelvic Venous Reflux *64*

5. Current Available Dressing and Adjunctive Therapies for Managing Leg Wounds 66
Harikrishna KR Nair
Wound Assessment *66*
Biofilms *67*
Dressings *69*
Other Adjunctive Modalities *78*

6. Erectile Dysfunction: Penile Revascularization Surgery 83
Jack Crozier, Michelle Ong, Sheliyan Raveenthiran, Devang Desai
Penile Vascular Anatomy *84*
Physiology of Normal Erection *84*
Erectile Dysfunction History *86*
Clinical Assessment Tools *87*
Vascular Assessment *87*
Candidacy for Penile Revascularization Surgery *89*
Principles of Surgery *89*
Specific Surgical Techniques *90*
Revascularization Strategies *91*

7. Popliteal Venous Entrapment 95
Aniket Pradhan, Kamran Khan
Etiology *95*
Clinical Features *95*
Diagnosis *96*
Management *98*

8. Failing Vascular Dialysis Access: Trouble Shooting and Management 101
Rahul Agarwal, Viswanath Atreyapurapu, Jessicka Shah, Pritee Sharma
Swing Segment Stenosis *104*
Arteriovenous Graft Stenosis *114*
Central Vein Stenosis *116*
Future Advances *117*

9. Surgical Experience with Takayasu's Disease 124
Madathipat Unnikrishnan
Etiology *124*
Clinical Paradigm *124*

Clinical Features *125*
Clinical Classification *126*
Investigations *128*
Management *128*
Results *135*

10. Renovascular Hypertension 141
Albert A Kota, Ajay Savlania, Nupur Bit, Vinoi George David, Gnaneswar Atturu, Edwin Stephen
Epidemiology *141*
Etiology for Renovascular Hypertension *142*
Clinical Syndromes of Renovascular *143*
Hypertension *143*
Pathophysiology and Pathogenesis *143*
Diagnosis: When Do You Suspect Renovascular Hypertension? *146*
Differential Diagnosis *147*
Investigations *148*
Approach to the Management of Renovascular Hypertension *151*
Results of Open Operative Management *165*
Updates on Renovascular Hypertension *166*

11. Pseudoaneurysms 174
Kamran Khan, Aniket Pradhan
Iatrogenic Pseudoaneurysms *175*
Diagnosis *176*
Management *178*
Postintervention Pseudoaneurysms at Nongroin Locations *183*
Traumatic (Noniatrogenic) Pseudoaneurysms *183*
Anastomotic Pseudoaneurysms *185*
Infected Pseudoaneurysms *186*

12. Traumatic Thoracic Aortic Injury 190
Vidyadhar Lad
Natural History *190*
Mechanism of Injury *190*
Classification/Grading of Aortic Injuries *191*
Clinical Presentation *191*
Imaging *192*
Treatment *195*
Outcomes *201*

13. Inferior Vena Cava Filters: The Good, the Bad and the Ugly of it 205
Adheesh Goriwal, R Sekhar
Indications of Inferior Vena Cava *205*
Filter Placement *205*
Patients for Bariatric Surgery *211*
Pregnant Patients *212*
Pediatric Patients *212*
Filter Design *213*
Filter Data *215*
Inferior Vena Cava Filter Complications *219*
Inferior Vena Cava Filters and Litigations *221*
What the Future Holds for Filters *222*

14. Current Trends in Managing Infected Aortic Aneurysms 228
Ajay Savlania, Abhinav Singh, Anil L Naik, Uttam Kumar Thakur, Abhinaya Reddy
Risk Factors for Infected Aortic Aneurysms *228*
Etiology *229*
Microbiology *230*
Clinical Features *231*
Diagnosis *232*
Management *234*
Results *239*
Recommendations *239*

15. Unconventional Vascular Access 249
Tarun Grover, Virender Sheorain
Unconventional Access for Peripheral Arterial Disease *251*
Hybrid Approaches Including Direct Percutaneous Access *254*
Transcaval Approach to Aortic Pathologies *254*
Percutaneous Graft Access *254*
Transgastric Approach for Splenic Artery Aneurysm *257*
Translumbar and Transhepatic Venous Access *257*
Catheter-directed Thrombolysis for Deep Vein Thrombosis *265*

16. Venous Thromboembolism in Obstetric Practice 267
Shubhabrata Banerjee, Akshata Shetty, R Sekhar
Pregnancy Thromboembolism Characteristics *267*
Prevention of Pregnancy-related Venous Thromboembolism *267*
Thromboprophylaxis in Women Undergoing Assisted Reproductive Technology *269*

Thromboprophylaxis after Cesarean Section *269*

Thromboprophylaxis in Pregnant Patients with Mechanical Heart Valves *270*

Diagnostic Algorithm for Pregnancy with Suspected Deep Vein Thrombosis *271*

Treatment of Deep Vein Thrombosis in Pregnancy *272*

17. Concept of Angiosomes and Lower Limb Vascularization 279

Rachana Tataria, Uzma Sadia, Venkatesh Reddy, Ahmed Emam

Background *280*

Anatomy *280*

Applications of the Angiosome Concept *282*

Discussion *284*

***Index*.....287**

4 Pelvic Congestion Syndrome

CHAPTER

M Ayman Fakhry, Sohiel Nagib

INTRODUCTION

For many years, the terminology of the chronic medical condition that causes pelvic pain had been discussed and many names (pelvic venous disorders, pelvic venous disease, etc.) had been suggested but finally the "International Classification of Diseases and VEIN-TERM Transatlantic Interdisciplinary Consensus Document" described it as "pelvic congestion syndrome (PCS)".[1]

BACKGROUND

Chronic pelvic venous insufficiency includes all events related to the dysfunction of the pelvic venous system, whether congenital or acquired. Venous reflux and pelvic varicose veins represent the most common pathological expression. These pelvic varicose veins are very common in multiparous women, and although they are most often asymptomatic; they can be responsible for PCS and/or varicose veins in the lower limbs.[2]

Several causes that are responsible for chronic pelvic pain (CPP) in women in gynecology clinics and PCS was first recognized by Gooch in 1831, while Taylor described the syndrome in detail and attributed it to the imbalance of the sympathetic and parasympathetic nervous systems causing this "vascular disturbance". Despite treatment for this condition was originally based on the hormonal control done by hysterectomy and oophorectomy. Hobbs described his technique by ligating the ovarian veins through retroperitoneal approach with few postoperative symptoms in most patients but no randomized clinical trials of this treatment had been published. Mathis et al. were able to ligate the ovarian veins via a transperitoneal route using laparoscopic technique.[3]

The main issue was many ladies with severe symptoms which need intervention revealing that pelvic congestion is underestimated.[1]

DEFINITION

Since Taylor was one of the earliest who defined PCS as "an increase in number and size of intrapelvic venous structures". Many different terms were used to describe PCS, e.g., Taylor's syndrome, congestion-fibrosis syndrome, pelvic vein incompetence, female varicocele, etc. More recent definition that was done in the VEIN-TERM Transatlantic Interdisciplinary Consensus Document, "chronic symptoms which may include pelvic pain, perineal heaviness, urgency of micturition, and postcoital pain, caused by ovarian and/or pelvic vein

JAYPEE BROTHERS

reflux and/or obstruction, and which may be associated with vulvar, perineal, and/or lower extremity varices".[1]

PREVALENCE

Chronic pelvic pain affects about 15% of premenopausal women in the United States and about 39% of women developed chronic pelvic vein sometimes in their life.[4]

Pathological venous hemodynamic of ovarian or pelvic veins may be responsible for a big number of cases that cause pain as ovarian vein incompetence can be seen in up to 10% of women and associated with symptoms of PCS in up to 60% of them.[5]

Studies showed 30% of CPP attributed to pelvic vein reflux as a sole factor with 15% in combination with other factors.[6]

The exact prevalence of pelvic congestion is not yet determined and more epidemiological studies are still needed.

VENOUS DRAINAGE OF THE PELVIS

Many venous plexuses drain the bladder, vagina, uterus, and rectum. The vagina and lower uterus drain into the uterine veins then to the internal iliac vein; the fundus of the uterus drains to the uterine or the ovarian plexus in the broad ligament. The right ovarian plexus drains into the right ovarian vein that drains into inferior vena cava (IVC) below the right renal vein. The left ovarian plexus drains into left ovarian vein to left renal vein (LRV); vulvoperineal veins drain into the internal pudendal vein, to the inferior gluteal vein, then the external pudendal vein, then into the saphenous vein, or into the circumflex femoral vein, lastly to the femoral vein.[7]

ETIOLOGY

It hits ladies of reproductive age (20–45 years) with increased incidence relating to number of pregnancies. Pregnancy is known with 60% increase of the pelvic vein capacity that is followed by dilation of the ovarian veins. This is hormonal related and it is likely that the ovarian veins fail to return to normal size after pregnancy and may become associated with the development of valvular incompetence. However, recent work has suggested that reflux in the ovarian veins is an ascending pattern, with the valves at the top of the vein being the last to become incompetent, except in true May–Thurner syndrome. It has been suggested that some anatomical conditions, such as kinking of the ovarian vein by a retroverted uterus, external compression (nutcracker syndrome, May–Thurner syndrome, retroperitoneal mass, etc.) may be associated with the development of pelvic congestion symptoms. Some authors described a possible association with psychosocial conditions. They reported significant correlation between some social arrangements, paternal parenting, and patterns of hostility in patients with PCS.[7]

JAYPEE BROTHERS

PATHOPHYSIOLOGY

Pain and dilated veins associated with PCS presumably arise from pelvic venous hypertension and distention of the per-uterine venous plexus. This is related to hormonal, genetic, and hemodynamic factors associated with venous dilation, decreased elasticity of the vein wall, and unfortunately valvular incompetence. Uterine venous reflux leads to venous hypertension and distending the per uterine and pelvic venous plexus causing abdominal pain and dilated veins in PCS. Classically, it has been associated with incompetence of the ovarian vein; although sometimes similar symptoms occur in cases of left iliac vein compression.[8]

HEMODYNAMIC CHANGES

The right ovarian vein is usually subject to pregnancy-related changes, and serves as a shunt to relieve the back pressure of incompetent left ovarian vein. The hemodynamics of collateral pathways vary significantly according to the causal mechanism and the site of occlusion or stenosis. The abnormal dilatation of pelvic veins may occur either because of increased or decreased blood flow.[9]

In addition to symptoms of CPP, it may also be associated with lower extremity varicose veins, either in a typical axial saphenous distribution or in atypical locations including the vulva, perineum, and posterior thigh. Such varices arise from the development of venous reflux in the distal tributaries of the internal iliac veins with transmission of venous pressure through the escape points in the pelvic floor to the lower extremity veins.[10]

These hemodynamic changes result from incompetence of the ovarian veins. However, similar pelvic venous hypertension and symptoms can result from primary internal iliac vein reflux or from compression of the left common iliac vein (May–Thurner syndrome) or LRV (nutcracker syndrome) **(Box 1)**.

CLASSIFICATION AND STRUCTURAL CHANGES

Approximately 13–15% of women have avalvular left ovarian vein. Venous hypertension in pelvic veins increases the expression of matrix metalloproteinase resulting in degradation of the underlying endothelium and smooth muscle that impairs the ability of veins to constrict and relax and increases

Box 1: Hemodynamic changes.

Vein

- Left ovarian vein
- Right ovarian vein
- Left internal iliac vein
- Right internal iliac vein
- Left renal vein
- Combined

JAYPEE BROTHERS

venous pressure with further endothelial cellular injury resulting into venous reflux. The varicosities of the pelvis show histological changes similar to those of the lower limbs with fibrosis of the intima and media, muscular hypertrophy, and proliferation of capillary endothelium.[11]

Ultrasound (US) studies have shown that women with PCS have larger uterus and cystic changes of their ovaries than healthy women, because of congestion and estrogen overstimulation.[1]

Simply we can classify PCS as: (1) primary with ovarian vein incompetence from nonobstructive causes either congenital or acquired, and (2) secondary pelvic insufficiency due to obstructive causes as (nutcracker syndrome or May–Thurner syndrome) when the pelvic or ovarian veins act as collaterals to relieve upstream obstruction.[7]

Monedero put classification of PCS based on hemodynamic changes (pressure alterations) in pelvic veins: (1) centrifugal (retrograde) collateral systems formation; (2) centripetal (anterograde) collateral systems formation; and (3) one of the listed hemodynamic conditions with leaking to the lower limbs. This classification has a great importance for adequate planning of invasive treatment of PCS. In 2005, Milka Greiner suggested a classification system that includes three main types:

Type 1: Nonobstructive valvular or parietal venous anomalies.

Type 2: Due to stenosis or obstruction in a draining vein causing symptomatic collaterals.

Type 3: Pelvic vein anomalies and pelvic reflux are secondary to a local extrinsic cause[7] **(Box 2)**.

Box 2: Milka Greiner's classification of pelvic venous reflux.

Type 1: Reflux pathology (without pelvic or suprapelvic obstruction to venous flow)

- *Valvular diseases*:
  - Congenital or acquired valvular incompetence
  - Absence of valves
- Congenital or acquired pelvic venous dilatations, regardless of the sector
- Venous malformations

Type 2: Venous pathology due to stenosis or obstruction in a draining vein

- *Suprapelvic obstruction*:
  - Abnormalities of the left renal vein
  - Pathology of the inferior vena cava or iliac veins

Type 3: Local extrinsic causes

- Postsurgery or postinfectious adhesions
- Obstetric destruction of supporting tissue (Allen–Masters syndrome)
- Nonobstetric trauma
- Endometriosis
- Abdominal/pelvic tumors
- Benign masses
- Secondary uterine retroversion (postpartum)

JAYPEE BROTHERS

DIAGNOSIS

Clinical Evaluation

Typically, PCS occurs more common in multiparous women between 20 and 45 years of age. Pelvic noncyclical pain is typically dull and increased during menstruation. Usually, pain is present >6 months and exacerbated by walking, and sexual intercourse. Other clinical manifestations of PCS may be various and it can affect different systems: Gynecological, urological, and gastroenterological with pelvic varicosities. A point of tenderness over the ovaries or uterus on bimanual examination without indurations or masses and an important step in examination is to evaluate varicose vein network, which may be present on perineal, vulvar, gluteal or posterior thigh areas.[1]

Noninvasive Tests

Ultrasound, magnetic resonance (MR) imaging, and computed tomography (CT) are very important tools to exclude a concurrent pelvic pathologic process.[7]

Ultrasound Examination

Abdominal and pelvic sonography: It is the first line of investigation in PCS, as it allows for the exclusion of other pelvic pathology, easily accessible and inexpensive.

Venous duplex of the abdomen: The patient is examined after fasting overnight. The patient is placed in the supine position with head elevation of 30° with a curvilinear 2–5 MHz transducer. The usual examined vessels are the IVC, LRV, iliac veins, ovarian veins, trans- and periuterine veins, and the tributaries of the internal iliac veins **(Fig. 1)**.[4]

Transabdominal duplex showed an ovarian vein diameter of 6 mm had been reported to have a 96% positive-predictive value for pelvic varices together with high antegrade flow in ovarian vein or reversal flow in internal iliac vein shows that the etiology of venous congestion is secondary due to intravascular (thrombotic) or extravascular (compression) factors. Presence of these flow parameters by Doppler has the basics for treatment **(Figs. 2A to C)**.[8]

Transvaginal Duplex Ultrasound

Pelvic varicocele was present in patients with PCS. The sonographic appearances of the ovarian and pelvic varicocele are multiple dilated veins around the ovary and uterus with a venous Doppler signal of varying amplitude. The presence of circular or linear venous structures with a diameter >5 mm is indicative of pelvic varicosities. A recent report suggested that initial accentuation in a pelvic varicocele during the Valsalva maneuver was an important Doppler sonographic finding for diagnosing PCS, similar to the method of diagnosing scrotal varicocele in men **(Figs. 3A to C)**.[12]

JAYPEE BROTHERS

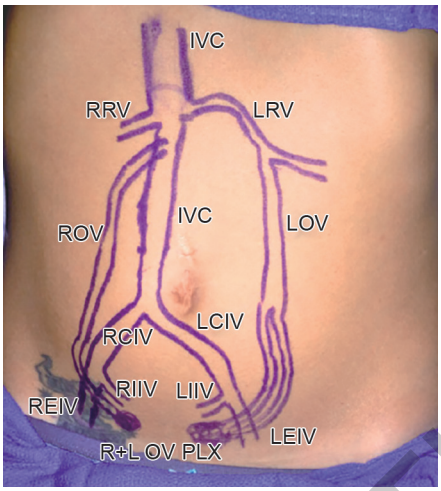

Fig. 1: Ultrasound mapping of abdominal and pelvic veins.[4]
IVC: inferior vena cava; LRV: left renal vein; LOV: left ovarian vein; ROV: right ovarian vein; RRV: right renal vein; LCIV: left common iliac vein; RCIV: right common iliac vein; LIIV: left internal iliac vein; RIIV: right internal iliac vein; LEIV: left external iliac vein; REIV: right external iliac vein; R+L OV PLX: right and left ovarian venous plexus

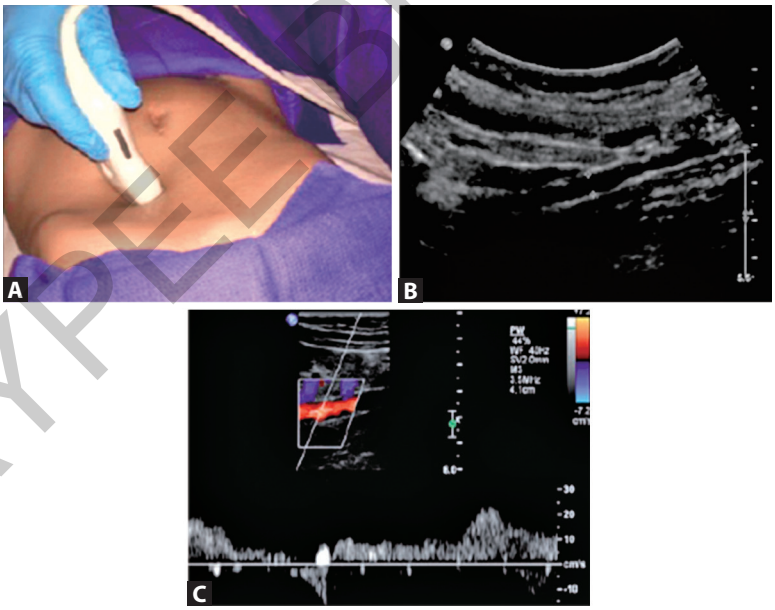

Figs. 2A to C: Duplex imaging of left ovarian vein (LOV). (A) The position of the transducer is demonstrated along the course of the LOV; (B) LOV is seen in longitudinal view with a diameter of 6.4 mm and antegrade flow; (C) LOV reflux seen on Doppler flow.[8]

JAYPEE BROTHERS

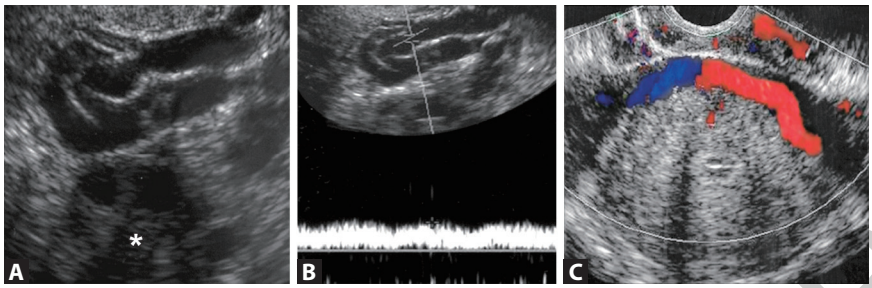

Figs. 3A to C: Transvaginal duplex imaging. (A) Transvaginal sonogram shows dilated ovarian venous plexuses around left ovary; (B) Waveform of left ovarian varicocele; (C) Transvaginal sonogram reveals large vein crossing uterine body from left to right with dilated pelvic varicocele.[12]

Duplex Ultrasonography of the Veins of Lower Limbs

It is a necessary part of the imaging protocol for the evaluation of PCS. Atypical varicose veins located on the posterior and lateral aspect of the thigh with competent saphenofemoral junction are quite pathognomonic for pelvic venous insufficiency. Venous reflux was most frequently seen in the common femoral vein (CFV) in such patients.[13]

Cross-sectional Computed Tomography

Computed tomography scan is usually useful for the diagnosis of abdominal pain. On CT, the varicosities which show venous varices in the area of uterus or in the pelvis that are isodense to other abdominal veins. CT has the capability to exclude other pelvic pathologies. In addition, careful review of the images often shows a large, dilated ovarian veins.[10]

Magnetic Resonance Venography

Magnetic resonance venography (MRV) is superior to CT venography (CTV). However, it is performed with the patient in the supine position causing under filling of the varices. Pelvic varices can be visualized efficiently in T1-phase after IV gadolinium injection, and flow in the pelvic varices appears as high signal intensity. Pelvic varicosities are identified as enlarged tortuous tubular structures in the trajectory of around the adnexa. The renal veins can be assessed for signs of compression as well as the common and/or external iliac vein. In conclusion, criteria for cross-sectional imaging diagnosis of PCS: (1) Grade I venous reflux: Early filling of left ovarian vein and/or left parauterine veins; (2) Grade II venous reflux: Grade I reflux + right ovarian vein reflux (left/right); (3) Identification of four ipsilateral pelvic veins with at least one measuring >4 mm; and (4) ovarian vein diameter >8 mm.[13]

JAYPEE BROTHERS

Invasive Tests

Catheter-directed Venography

Venography can be done via cubital, jugular or femoral access. Diagnostic criteria for PCS are following: (1) An ovarian vein diameter >6 mm; (2) Contrast retention >20 sec; (3) Congestion of the pelvic venous plexus and/or opacification of the ipsilateral (or contralateral) internal iliac vein, or (4) Filling of vulvovaginal and thigh varicosities. Injecting contrast material must be done in semi-erect position of patient and/or during Valsalva maneuver. Laborda et al. consider it is necessary to evaluate the hypogastric, external iliac, and CFVs, while some authors recommend to pay attention for renocaval and iliocaval segments. In case of atypical varicose veins of lower extremities to perform the bilateral descending venography of femoral veins are necessary.[4]

Intravascular Ultrasound

For PCS, intravascular ultrasound (IVUS) is diagnostic method, Labropoulos recommends using IVUS along with venography and renocaval gradient measurement in diagnosis of nutcracker syndrome. Patients undergoing IVUS represent either: (1) iliac vein pathology was suspected (estimated 80% of limbs) from one or more investigations, whether associated with significant distal reflux or not, and (2) results of investigations for iliac vein obstruction were negative (estimated 20% of limbs) but clinically suspected because detected distal reflux either minimal (e.g., single segment reflux) or altogether absent in the context of severe symptoms.[1]

Laparoscopy

Laparoscopy is often used in patients with CPP in many gynecological centers as an initial method of diagnosis. Pelvic varices and prominent enlarged broad ligament veins are the main findings in case of PCS.

Laparoscopy can still be negative in 80–90% of patients with PCS.[1]

DIFFERENTIAL DIAGNOSIS OF CHRONIC PELVIC PAIN

Diagnosis and confirmation of PCS can be made by excluding of other causes of CPP as: fibroids, adenomyosis, endometriosis, cystitis, pelvic inflammatory disease, pelvic tumors, ovarian and fallopian tube diseases, inflammatory bowel diseases and adhesions, pelvic arteriovenous malformations, portal hypertension, etc.[1]

TREATMENT

Generally, it is known that not all patients with PCS seek treatment as interventional treatment was only used in situations where interruption of the pelvic reflux was thought to have an impact on the clinical symptoms, and

JAYPEE BROTHERS

detection of pelvic reflux alone was not an absolute indication for treatment. The decision to perform interventional treatment is made when the reflux patterns in the pelvic veins and the symptoms correlated.[4]

Three forms of therapy were recognized for the treatment of this condition: (1) Medical treatment, (2) Surgical removal of the female reproductive organs, and (3) Alteration of venous flow. While the former two have been proposed in the past, they do not appear to be very effective. Recently, alteration in venous flow through coiling, vein transposition, and stenting is gaining interest and shows promising results.[5]

Medical Therapy

Medical treatment of PCS has included psychotherapy, analgesics, nonsteroidal anti-inflammatory drugs, hormone replacement therapy, gonadotropin-releasing hormone agonists, and venoactive drugs.[1]

Nonsteroid analgesics are an acceptable first-line treatment. They may offer some short-term relief while patients await further investigations or a more permanent treatment. However, nonsteroidal anti-inflammatory drugs are not a long-term solution for the patients with CPP.[4]

- *Venoactive drugs*: The micronized purified flavonoid fraction (MPFF) has a protective and tonic effect on the venous and capillary tone. It is reported that pelvic vein decreased after using these drugs for 8 weeks and disappeared after 14 weeks in some cases.[14]

Surgical Treatment

Hysterectomy with salpingo-oophorectomy had been performed in the past with nonconvenient results. Ovarian vein ligation, either retroperitoneal or laparoscopic has also historically been suggested as a treatment for primary ovarian vein incompetence.[15]

Endovascular Treatment

The clinical practice guidelines of the Society for Vascular Surgery and American Venous Forum suggest treatment with coil embolization, plugs, sclerotherapy, alone or in combination. Staged pelvic and lower extremity interventions could be planned in many patients with concurrent pelvic symptoms and external varices to achieve the best results. Both mechanical and chemical therapies are used in the endovascular treatment of PCS. Embolization is done with occlusive devices such as coils, vascular plugs, absorbable or detachable balloons. Coil embolization is the most common mechanical method of minimally invasive treatment for gonadal vein reflux. Guirola et al. demonstrated that there were no differences in treatment outcomes with the use of vascular plugs compared with coils. The use of foam can decrease the number of coils needed and lead to similar reductions in radiation dose (sandwich technique) **(Fig. 4)**.[4]

JAYPEE BROTHERS

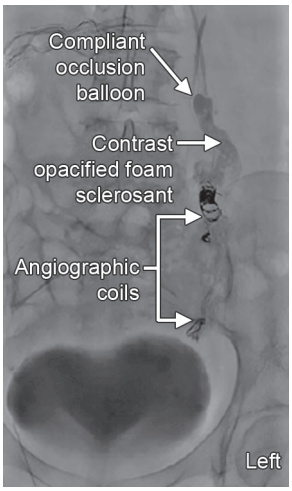

Fig. 4: Balloon occlusion foam sclerotherapy and coil embolization of the left ovarian vein using a "sandwich technique".[4]

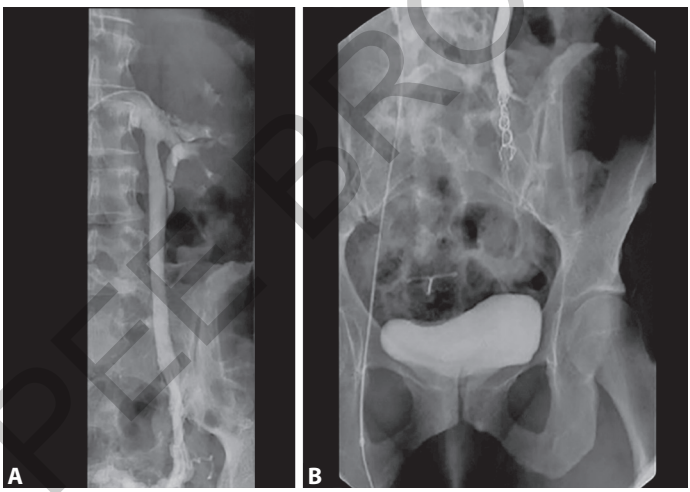

Figs. 5A and B: (A) Pathological reflux in the left ovarian vein; (B) With complete occlusion of the vessel after embolization.[4]

Venous access could be approached either from an internal jugular vein or CFV with preference to the jugular one. The left ovarian vein is easier to catheterize due to its anatomy (draining into the LRV), while the right ovarian vein typically drains directly into the IVC just inferior to the right renal vein.[6]

Maleux et al. found no significance difference in symptom relief in patients who underwent unilateral or bilateral ovarian embolization and usually unilateral left ovarian vein embolization is performed and is sometimes the only treatment required **(Figs. 5A and B)**.[4]

JAYPEE BROTHERS

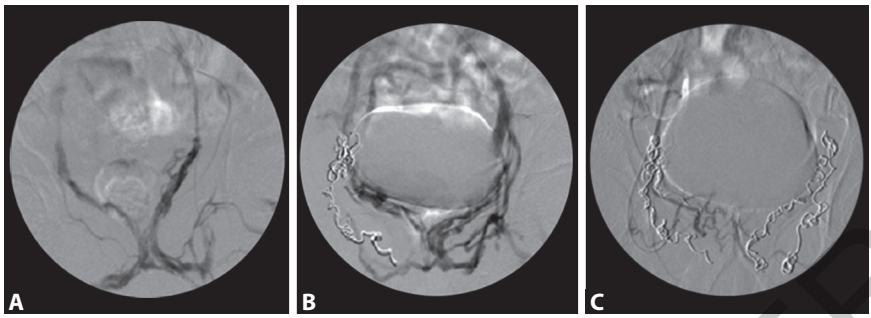

Figs. 6A to C: Venography images—during embolization and postembolization, with coils placed in both the obturator and the pudendal tributaries.[16]

MALE PATTERNS OF PELVIC VENOUS REFLUX

Neither reliable clinical trial nor epidemiologic data exist to define this observation. And aside from the connection between testicular vein insufficiency and varicocele, there is nothing that we could find in the literature regarding venous reflux in testicular and/or internal iliac veins in males and its connection with lower limb varicose veins. Pelvic venous reflux (PVR) is known to be a cause of primary and recurrent varicose veins in women. In men, diagnosis is more challenging. Dabbs et al. reported a series of male patients in whom PVR was a major cause of venous reflux and varicose veins that was treated by transjugular coil embolization **(Figs. 6A to C)**.[16]

SUMMARY

Pelvic congestion syndrome is an underestimated condition for the diverse nature and number of symptoms of the PVR. It is usually thought of as a problem of multiparous women and symptoms may be internal or external to the pelvis with varicose veins around the pelvis or legs. Although it hits reasonable number of populations with different presentations yet not fully enumerated.[1]

Reflux is the usual cause of PCS, although obstruction plays a role in a small number of cases—probably fewer cases than often thought. Duplex examination of abdomen and pelvis helps in its diagnosis while the gold standard investigation appears to be transvaginal duplex US performed in the semierect patient.[17]

Embolization is currently the optimal treatment of PVR. Coil embolization ± transcatheter foam sclerotherapy being the most popular method of therapy. Rarely, stenting is needed especially since Holdstock described pseudo-nutcracker on fluoroscopy. Pain relief and the symptomatic improvements of 60–100% after treatment trigger the need for better diagnosis, investigation, and treatments.[18]

JAYPEE BROTHERS

REFERENCES

1. Antignani PL, Lazarashvili Z, Monedero JL, Ezpeleta SZ, Whiteley MS, Khilnani NM, et al. Diagnosis and treatment of pelvic congestion syndrome: UIP consensus document. Int Angiol. 2019;38(4):265-83.
2. Lemasle P, Greiner M. Duplex ultrasound investigation in pelvic congestion syndrome: technique and results. Phlebolymphology. 2017;24(2):77-116.
3. Smith PC. The outcome of treatment for pelvic congestion syndrome. Phlebology. 2012;27 (Suppl 1):74-7.
4. Asciutto G, Asciutto KC, Mumme A, Geier B. Pelvic venous incompetence: reflux patterns and treatment results. Eur J Vasc Endovasc Surg. 2009;38(3):381-6.
5. Moore CJ. (2011). Pelvic congestion syndrome update: diagnostic and therapeutic options for this often unrecognized condition and one center's approach to treatment. [online] Available from: https://evtoday.com/pdfs/EVT1011_vessel_update.pdf [Last accessed February, 2021].
6. Kim HS, Malhotra AD, Rowe PC, Lee JM, Venbrux AC. Embolotherapy for pelvic congestion syndrome: long-term results. J Vasc Interv Radiol. 2006;17(2 Pt 1):289-97.
7. Meissner MH, Gibson K. Clinical outcome after treatment of pelvic congestion syndrome: sense and nonsense. Phlebology. 2015;30:73-80.
8. Labropoulos N, Jasinski PT, Adrahtas D, Gasparis AP, Meissner MH. A standardized ultrasound approach to pelvic congestion syndrome. Phlebology. 2017;32(9):608-19.
9. Emmerich J. Journal des Maladies Vasculaires. (2019). Présentation - EM consulte. [online].
10. Umeoka S, Koyama T, Togashi K, Kobayashi H, Akuta K. Vascular dilatation in the pelvis: identification with CT and MR imaging. Radiographics. 2004;24(1):193-208.
11. Greiner M, Dadon M, Lemasle P, Cluzel P. How does the pathophysiology influence the treatment of pelvic congestion syndrome and is the result long-lasting? Phlebology. 2012;27 (Suppl 1):58-64.
12. Park SJ, Lim JW, Ko YT, Lee DH, Yoon Y, Oh JH, et al. Diagnosis of pelvic congestion syndrome using transabdominal and transvaginal sonography. Am J Roentgenol. 2004;182(3):683-8.
13. Steenbeek MP, van der Vleuten CJ, Kool LJ, Nieboer TE. Noninvasive diagnostic tools for pelvic congestion syndrome: a systematic review. Acta Obstet Gynecol Scand. 2018;97(7):776-86.
14. Taskin O, Sahin L, Gavrilov SG, Lazarashvili Z. Medical treatment of pelvic congestion syndrome. Phlebolymphology. 2017;23(3):121-64.
15. Scultetus AH, Villavicencio JL, Gillespie DL, Kao TC, Rich NM. The pelvic venous syndromes: analysis of our experience with 57 patients. J Vasc Surg. 2002;36(5):881-8.
16. Dabbs E, Santos SD, Shiangoli I, Holdstock J, Whiteley M. Male patterns of pelvic venous reflux can be investigated with duplex ultrasound and treated with coil embolization. J Vasc Surg Venous Lymphat Disord. 2017;5(1):170.
17. Karaosmanoglu D, Karcaaltincaba M, Karcaaltincaba D, Akata D, Ozmen M. MDCT of the ovarian vein: normal anatomy and pathology. Am J Roentgenol. 2009;192(1):295-9.
18. Rochon PJ, Spencer EB. Pelvic congestion syndrome: underdiagnosed, misdiagnosed, and undertreated…or a misnomer? Endovasc Today. 2018;17(1):1-4.

JAYPEE BROTHERS

For detailed information on surgery books, visit our website www.jaypeebrothers.com, for detailed information on surgery

Yearbook of
Vascular and Endovascular Surgery-3
2021

Salient Features

- The book contains a string of very relevant and practical topics by a worldwide galaxy of experts, each one of whom is a successful and reputed practitioner of his/her craft
- An ideal companion for postgraduate trainees in vascular surgery, interventional radiologists, peripheral minded interventional cardiologists, and anyone practicing the art and science of the treatment of vascular diseases, especially those who want to stay abreast with current evidence-based management protocols
- Topics range from surgical management of mycotic aneurysms, pseudoaneurysms and aortoarteritis to popliteal vein entrapment, pelvic vein reflux, anticoagulation trends and practical advice on wound care.

R Sekhar MS FRCS (Ed) FRCS (Glasg) FVSI is a full-time Consultant who represents the Vascular and Endovascular Services at the reputed Kokilaben Dhirubhai Ambani Hospital and Medical Research Institute, Mumbai, Maharashtra, India. Besides being an avid vascular disease enthusiast and an acknowledged expert in his field, Dr Sekhar is a passionate teacher who takes significant time out from his busy professional schedule in the pursuit of academic goals, which include training and mentoring of junior doctors. His teaching clinics are as much sought after by trainees, as are his awareness lectures on vascular disease by practicing physicians.

Printed in India

Available at all medical bookstores
or buy online at www.jaypeebrothers.com



JAYPEE BROTHERS
Medical Publishers (P) Ltd.
EMCA House, 23/23-B, Ansari Road,
Daryaganj, New Delhi - 110 002, INDIA
www.jaypeebrothers.com

Join us on facebook.com/JaypeeMedicalPublishers

Shelving Recommendation
SURGERY

